

A Histo-pathological Study of various Types of Chronic Gastritis in Stray Dogs

KHAKSAR, E.^{1*}, JAMSHIDI, SH.², SEDAGHAT, R.³, TAMIMI, N.⁴

¹Department of clinical Sciences, Faculty of Veterinary medicine, Islamic Azad University, Sciences & Researches Branch, Tehran- Iran

²Department of clinical Sciences, Faculty of Veterinary medicine, Tehran University, Tehran- Iran.

³Department of Basic Sciences & Faculty of medicine, Shahed University, Tehran- Iran.

⁴Graduated from Faculty of Veterinary medicine, University of Tehran, Tehran- Iran.

*Correspondence: E-mail: ehsan.khaksar@gmail.com

Abstract

Gastritis is a common disease in dogs. According to studies, about 40% of dogs suffering from vomiting end up with chronic gastritis or those with no digestive symptoms reveal some levels of gastric histo-pathologic lesions. Studies on dogs and cats indicate that the most prevalent form of chronic gastritis is the lymphocytic plasmocytic form associated with lymphoid follicular hyperplasia and that the lesions are more likely to be seen in antrum. In order to assess chronic gastritis forms in stray dogs that seem to be at greater risk due to their probably poor nutrition and parasitic infections, this study as the first one in Iran was conducted on the antrum and body of the stomachs of 30 stray dogs killed under a culling program in Garmzar city assessing any possible correlation with the dog's age and sex. After the autopsy, histo-pathologic samples were prepared from the two areas, stained and finally examined. The results revealed that 56.6% of the dogs suffer from levels of chronic gastritis with the lymphocytic plasmocytic gastritis being the most common (50%) and hypertrophic gastritis the least common (6.6%). Antrum showed more lesions than body. Statistically there was no significant correlation between age groups or sexes with the disease. The results of this study indicate that chronic gastritis is respectively more prevalent in stray dogs than it is in other dogs; whereas poor nutrition and parasitic infections might be the reason behind this. *Islamic Azad Univ., Garmzar Branch. 5,2:145-149,2009- 2010.*

Keywords: chronic gastritis, histopathology, dog.

بررسی انواع گاستریت مزمن در سگ‌های ولگرد به روش هیستوپاتولوژی

احسان خاکسار^۱، شهرام جمشیدی^۲، رضا صداقت^۳، نقا تمیمی^۴
۱- گروه علوم درمانگاهی، دانشکده دامپزشکی، دانشگاه آزاد اسلامی واحد گرمسار علوم و تحقیقات، تهران- ایران.
۲- گروه علوم درمانگاهی، دانشکده دامپزشکی دانشگاه تهران، تهران- ایران.
۳- گروه علوم پایه دانشگاه علوم پزشکی شاهد تهران- ایران.
۴- دانش آموز، دانشکده دامپزشکی دانشگاه تهران، تهران- ایران.

چکیده

گاستریت مزمن یکی از بیماری‌های شایع در سگ‌ها به شمار می‌رود. در مطالعات حدود ۴۰ درصد از سگ‌های خانگی مبتلا به استفراغ به گاستریت مزمن دچار شده و یا سگ‌های فاقد علائم گوارشی در جاتی از ضایعات هیستوپاتولوژیک معنی را نشان می‌دهند. طی مطالعات انجام گرفته روی سگ‌ها و گربه‌ها متداول‌ترین نوع گاستریت مزمن نوع لنفوسیتیک پلاسموسیتیک به همراه هیپرپلازی فولیکولهای لنفاوی بوده، ضایعات هیستوپاتولوژیک گاستریت نیز بیشتر در ناحیه آنتروم معده گزارش شده است. جهت بررسی انواع گاستریت‌های مزمن در سگ‌های ولگرد که بنظر می‌رسد بدلیل داشتن تغذیه نامناسب و عفونت‌های انگلی بیشتر در معرض خطر باشند، این مطالعه برای اولین بار در ایران روی آنتروم و بادی معده ۳۰ قلاده‌سگ ولگرد که طی طرح معدوم‌سازی در شهرستان گرمسار از بین رفته بودند، صورت گرفت و ارتباط این بیماری با سن و جنس حیوان نیز مورد بررسی قرار گرفت. پس از کالبدگشایی، مقاطع هیستوپاتولوژیک از این دو ناحیه تهیه و رنگ آمیزی شده سپس مورد مطالعه قرار گرفتند. نتایج بدست آمده نشان داد ۵۶/۶ درصد از سگ‌ها به درجاتی از گاستریت مزمن مبتلا بوده و گاستریت لنفوسیتیک پلاسماسیتیک با ۵۰ درصد بیشترین شیوع و گاستریت هایپرتروفیک با ۶/۶ درصد کمترین شیوع را دارا می‌باشند. همچنین ضایعات در ناحیه آنتروم بیش از بادی مشاهده شد. در نهایت بررسی آماری اختلاف معنی‌داری بین گروه‌های سنی و جنس نشان نداد. نتایج این مطالعه نشان می‌دهد که گاستریت مزمن در سگ‌های ولگرد تا حدی شایع‌تر از سلبرسگ‌هاست که شاید بتوان علت آن را بالا بودن احتمالی عفونت‌های انگلی، باکتریایی و تغذیه نامناسب در این سگ‌ها دانست. مجله دانشکده دامپزشکی دانشگاه آزاد اسلامی واحد گرمسار، ۱۳۸۸، دوره ۵، شماره ۲، ۱۴۹-۱۴۵.

واژه‌های کلیدی: گاستریت مزمن هیستوپاتولوژی، سگ.



Introduction

According to studies, 35% of dogs suffering from vomiting end up with chronic gastritis and 36–48% of dogs with no apparent digestive symptoms also have revealed some levels of gastric histo-pathologic lesions. The diagnosis of chronic gastritis is based on histologic examination of gastric biopsies (1). Various classifications of chronic gastritis have been used, including etiological and histological ones, which have overlapping clinico-pathological features. If the primary cause of chronic gastritis – such as food allergy, non-steroidal anti-inflammatory drugs, or uremia – is identified, therefore an etiological classification is possible; however, in most cases the main cause remains unknown (2).

The mild to moderate superficial lymphoplasmacytic gastritis associated with lymphoid follicular hyperplasia is the most common type of gastritis in dogs and cats while eosinophilic, granulomatous, atrophic, and hyperplastic gastritis are less common. Vomiting food or bile is the most important finding in chronic gastritis. Decreased appetite, weight loss, melena, or hematemesis are also variably encountered. Clinico-pathological tests are often normal in patients with chronic gastritis and recent studies suggest that chronic gastritis is very common in asymptomatic dogs and cats (1). Even in most cases where gastroscopy has shown normal gastric mucosa, histo-pathological examination of biopsy samples, have led to the diagnosis of chronic gastritis. Also according to Redeen et al., macroscopic findings of gastroscopy have very limited value regarding the evaluation of chronic gastritis (7). These findings indicate that histo-pathological studies are not only necessary but also mandatory to report chronic gastritis.

Stray dogs seem to be at greater risk of chronic gastritis due to their poor nutrition and higher rate of parasitic infections, therefore this study was aimed to assess their rate of chronic gastritis histo-pathologically. This study that was conducted for the first time in Iran has also assessed the types of chronic gastritis and evaluated its possible correlation with the dog's sex and age.

Materials and Methods

In order to determine the rate of chronic gastritis and assess its different forms in antrum and body of the stomach, 30 stray dogs were studied; all of which were killed under a culling program conducted by the municipality and the public health center of the city of Gamsar. The dogs were transferred to the clinic of the Faculty of Veterinary Medicine, Gamsar University, considering all the necessary hygienic measures and the data regarding their age and sex was also recorded. Dogs were then divided into three groups according to their age ($Y < 5$, $5 - 10$ & $Y > 10$). After that autopsy was performed on dogs and samples were taken from the body (greater curvature) and antrum of the stomach. The formalin-fixed specimens were embedded in paraffin and then were cut into sections with 5 μ m thickness. The next step was to stain these sections with Hematoxylin and Eosin and to examine them for any possible lesion. Finally, each examined specimen was evaluated according to the following parameters: presence or absence of gastritis, lymphoid follicles, erosion and/or ulcer and fibrosis.

Statistical analysis

Statistical analysis was performed using Mc Nemar, Chi square and exact-fisher tests. A probability of less than 0.05 was considered to be statistically significant. SPSS package (ver.11) was used for this analysis.

Results

The results of this study showed that (17 dogs) 56.6% of tested dogs were diagnosed with chronic gastritis according to the histo-pathologic examination. Histo-pathological results also ruled out any significant correlation between the dog's age or sex and the incidence of chronic gastritis in stray dogs ($P < 0.05$) (Table 1).

Assessment of the rates of different types of chronic gastritis revealed that lymphoplasmacytic was the most common type (50%) (Fig. 1, 2); whereas hypertrophic gastritis was the least common one (6.6%) (Fig. 3). The rate of chronic gastritis (especially lymphoplasmacytic) in the antrum area of



the stomach was reported higher than that of the body, however, according to the Mc Nemar test this difference was not statistically significant ($P < 0.05$) (Table 2).

Examination of the gastric samples for ulcer and erosion did not lead to any report of either of these lesions in any part of the stomach.

Table 1- Number of stray dogs diagnosed with chronic gastritis histo-pathologically according to their age and sex

Age (year)	Sex	No of dogs with Gastritis	No Healthy dogs	Total
5 >	Male	6	7	13
	Female	2	2	4
	Total	8	9	17
10-5	Male	4	3	7
	Female	1	1	2
	Total	5	4	9
>10	Male	4	-	4
	Female	-	-	-
	Total	4	-	4
Total	Male	14	10	24
	Female	13	3	6
	Total	17	13	30

Table 2- Number of stray dogs diagnosed with chronic gastritis histo-pathologically according to the area of the stomach (antrum and body)

Gastritis type	Hypertrophic				Lymphoplasmacytic				Total
	Antrum	Body	both	Total	Antrum	Body	both	Total	
Number of dogs	-	-	2	2	8	5	2	15	17

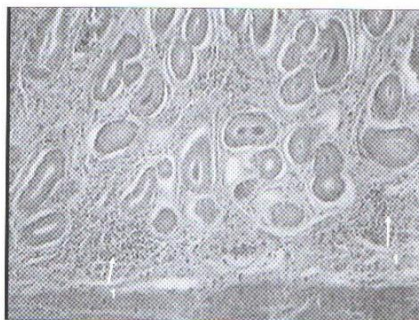

Fig 1- Lymphoplasmacytic gastritis: cellular infiltration (1) (H & E, $\times 400$)

Discussion

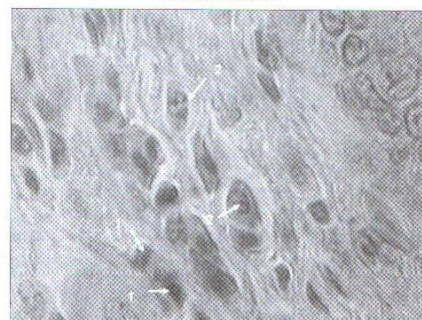


Fig 2- Lymphoplasmacytic gastritis: mild infiltration of lymphocytes (1) and Plasmacells (2) (H & E, $\times 1000$)

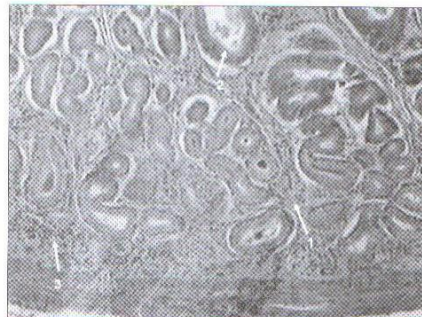


Fig 3- Hypertrophic gastritis: lamina propria (1) Hypertrophic glands (2), mononuclear cells infiltration (3) (H & E, $\times 400$)

Although chronic gastritis is a common cause of chronic vomiting in small animals, still there are limited studies regarding the prevalence of this disease and its different types. Results of recent studies show that gastritis is a common disease in dogs since 35% of dogs suffering from chronic vomiting and 36% to 48% of asymptomatic dogs were affected (1).

Chronic vomiting is a common gastrointestinal complaint in dogs and cats, and is often linked to chronic gastritis, but histologically verified chronic gastritis is a poorly documented entity in these species (2).

In Iran there has been no study in relation to the



prevalence of chronic gastritis in dogs so far; therefore this is the first study regarding this disease and its different types in two areas (body and antrum) of the stomach. This study also assesses the possible correlation of this disease with the animal's age and sex.

Van Der Gaag and Happe believed that since chronic gastritis often occurs in small patchy lesions, thereafter small gastric biopsy specimens would not represent the entire stomach (8). Recent studies also recommend that several biopsies for each case of gastritis be obtained (5). Gross features of gastroscopy have very limited value in evaluating chronic gastritis (7). Accordingly, in order to prevent these mistakes in this study and to enhance the possibility of detecting different types of chronic gastritis, gastric samples were taken randomly and in full thickness from two different areas of the stomach.

The current study has reported a total rate of 56.6% of chronic gastritis in dogs which is much higher than other reports in domestic dogs (1). Despite the high prevalence of gastritis an underlying cause is rarely identified and, in most cases of chronic gastritis the main cause remains unknown (2), and there is still much more to discuss about the etiology of chronic gastritis. Considering the fact that the dogs in this study were stray dogs and the probability of them having improper diet, parasitic infections and foreign bodies is relatively high, it seems that these factors can be blamed for having caused a higher rate of chronic gastritis in these dogs.

According to ETTINGER and FELDMAN, the most common form of gastritis in dog is a mild to moderate lymphoplasmatic gastritis. The current study has also reported the mild lymphoplasmatic gastritis as the most common form of gastritis (1).

Kato et al. considered the sex and age of human patients as effective factors in the incidence of gastritis (4); however, the current study as well as ETTINGER and FELDMAN's study did not detect any significant correlation between these parameters and the disease in stray dog (1). The current study's results are also similar to the results of ETTINGER and FELDMAN's in that only 2 dogs (6.6%) were diagnosed with hypertrophic gastritis in this study. In

other words, this result verifies ETTINGER and FELDMAN's suggest that Hypertrophic gastritis in the fundic mucosa of dogs and cats is uncommon (1).

While studies of HAPPONEN et al. and NIEGER et al. revealed that chronic gastritis was significantly more prevalent in feline antrum than in other areas of the stomach, the current study has also reported more prevalence of gastritis in antrum (3, 6). Moreover, neither HAPPONEN et al. detected any gastric ulcer/erosion –macroscopic or microscopic– in any part of the stomach nor the current study reported any ulcer or erosion examining gastric histo–pathological samples.

According to the results of this study chronic gastritis –especially the lymphoplasmatic type– is considerably important in stray dogs. It can also be inferred that possible factors such as parasitic infection, improper diet and foreign bodies can probably have important role in causing chronic gastritis in dogs.

Since there is a good chance of histo–pathological changes in gastric mucosa of asymptomatic animals, the clinical significance of such findings should be further questioned. It should also be considered that lack of GI symptoms may be related to mild and non-specific clinical signs which may be missed by the owners. Nevertheless, the decision for therapy in such animals should be based on the presence and degree of clinical signs, regardless of histo–pathological findings.

References

1. ETTINGER, S., E. FELDMAN (2005) Text Book of Small Animal Veterinary Medicine, Sixth edition, Elsevier Saunders, St. Louis, Missouri, 1321–1326.
2. GUILFORD, W. G., G. R. STROMBECK (1996) Strombecks Small Animal Gastroenterology: Third edition, WB Saunders, Philadelphia, 286.
3. HAPPONEN, I., S. SAARI, L. CASTREN, O. TYNI, M. HENNINEN, E. WESTERMARCH (1996) Occurrence and topographical mapping of gastric *Helicobacter*-like organisms and their association with histological changes in apparently healthy dogs and cats. *J. Vet. Med. A*, 43: 305–315.
4. KATO, S., N. MATSUKURA, A. TOGASHI, G.



and
; in
1),
ER
rtly
s of
ore
ver,
tric
any
any
cal

nic
- is
be
itic
an
ric

cal
ils,
be
rat
-
ne
in
rd
-

of
n,

6)
rd

ll,
3)
ic
on
js

3.

- MASUDA, N. MATSUDA, N. YAMADA, Z. NATIO, T. MATSUHISA, T. TAJIRI (2004) Sex differences in mucosal response to *Helicobacter pylori* infection in the stomach and variations in interleukin-8, COX-2 and trefoil factor family 1 gene expression. *Aliment Pharmacol. Ther.* **20**: 17-24.
5. KHOURI, K., R. SAYEGH, C. YAGHI, K. HONIEN, E. GEREON, J. B. JAODE, G. ABADIGIAN, W. NASSR, N. ABDEL MALAK, L. KLEIN, R. SLIM (2002): Role of endoscopic gastric biopsies in the management of gastritis. A study of 250 consecutive cases. *J. Med. Liban.* **50**: 149-56.
6. NEIGER, R., C. DIETERICH, A. BURNENS, A. WALDVOGEL, I. CORTHESEY, F. HALTER, B. LAUTERBURG, A. SCHMASSMANN (1998) Detection and prevalence of *Helicobacter* infection in pet cats. *J. Clin. Microbiol.* **36**: 634-637.
7. REDEEN, S., F. PETERSSON, K. A. JONSSON, K. BORCH (2003) Relationship of gastroscopic features to histological findings in gastritis and *Helicobacter pylori* infection in a general population sample. *Endoscopy*, **35**: 946-950.
8. VAN DER GAAG, I., N. HAPPE (1989) Follow-up studies by per oral gastric biopsies and necropsy in vomiting dogs. *Can. J. Vet. Res.* **53**: 468-472.

