



## The effect of *Malva neglecta* total extract on bleomycin- induced pulmonary fibrosis in rat

Amir Albabay<sup>1</sup>, Ali Hosseini-Sharifabad<sup>\*1</sup>, Afsaneh Yegdaneh<sup>2</sup>, Mahdi Tavakoli<sup>3</sup>, Hamide Dabaghydost<sup>1</sup>

<sup>1</sup>School of Pharmacy and Pharmaceutical Sciences, Isfahan University of Medical Science, Esfahan, Iran;

\*Email: [hosseini\\_a@pharm.mui.ac.ir](mailto:hosseini_a@pharm.mui.ac.ir)

<sup>2</sup>Department of Pharmacognosy, School of Pharmacy and Pharmaceutical Sciences, Isfahan University of Medical Science, Esfahan, Iran;

<sup>3</sup>Department of Pharmacognosy, Faculty of Pharmacy, Zanjan University of Medical Sciences, Zanjan, Iran;

### ARTICLE INFO

**Type:** Original Research

**Topic:** Medicinal Plants

**Received** July 19<sup>th</sup>2023

**Accepted** November 05<sup>th</sup>2023

### Key words:

- ✓ Idiopathic pulmonary fibrosis
- ✓ Bleomycin
- ✓ *Malva neglecta*
- ✓ Rat

### ABSTRACT

**Background & Aim:** Idiopathic pulmonary fibrosis (IPF) is a chronic and progressive respiratory disease. *Malva neglecta* possesses significant anti-inflammatory and antioxidant activity. In this study, the therapeutic effect of hydroalcoholic extract of *M. neglecta* on bleomycin-induced pulmonary fibrosis was investigated.

**Experimental:** 36 male Wistar rats (180-200 g) were used for this study. The animals were randomly divided into six groups. Group I (control) was administered saline intratracheally on day 1 (single dose). The other groups received a single dose of bleomycin (7.5 IU/kg) intratracheally on day 1 and were then fed daily for 28 days according to the following schedule: group II: saline, group III: pirfenidone, groups IV, V, VI: 300, 600 or 900 mg/kg *M. neglecta* extract. Finally, the rats were euthanized and the lung tissue was removed for histological analyses and biochemical investigations.

**Results:** Intratracheal administration of bleomycin significantly increased the lung tissue levels of hydroxyproline, malondialdehyde and free radicals compared to the control group ( $P < 0.001$ ). *M. neglecta* extract (900 mg/kg) significantly prevented the increase of these factors compared to the BLM group ( $P < 0.001$ ). *M. neglecta* extract at higher dose (900 mg/kg) remarkably decreased the above factors compared to its lower dose ( $P < 0.01$ ). Lung tissue in bleomycin-treated groups showed severe tissue damage. In addition, hydroalcoholic extracts from *M. neglecta* prevented the pathological damage of BLM to the lung tissue.

**Recommended applications/industries:** Our findings showed *M. neglecta* total extract could treat the pulmonary fibrosis induced by BLM. This effect may be related to the anti-inflammatory and antioxidant properties of the extract.

### 1. Introduction

Idiopathic pulmonary fibrosis (IPF) is a chronic and progressive disease of the interstitial tissue of the lung that is associated with symptoms such as dry cough and shortness of breath (Krishna et al., 2022). IPF begins with damage to the alveolar epithelial cells, which

leads to the release of inflammatory mediators and free radicals. These mediators eventually lead to lung tissue damage and respiratory failure. The etiopathogenesis of IPF is not fully understood. Otherwise, excessive production of free radicals has been repeatedly reported

to be associated with IPF (Yousefi-Manesh *et al.*, 2022). Risk factors of this disease include environmental factors (smoking, dust, metals), genetic factors (mutation of SP-C, ELMOD2, ABCA3 genes) and aging, and pathogenic mechanisms such as oxidative stress (Mouratis and Aidinis, 2011).

Pathologic features of IPF include extracellular matrix expansion, fibroblast activation and proliferation, impaired immune regulation, cellular senescence, and the presence of abnormal basaloid cells (Glass *et al.*, 2022). Pharmacologic treatments for IPF include nintedanib and pirfenidone. Due to their adverse effects, limited tissue distribution and low bioavailability, researchers are interested in exploring alternative therapies such as the use of traditional herbal medicines with antifibrotic and anti-inflammatory properties (Nwafor *et al.*, 2021). *Malva neglecta*, which belongs to the Malvaceae family, is a perennial plant with heart-shaped leaves and white flowers with red veins. In some regions of Iran, its leaves, flowers and stems are used as a medicinal plant to treat various diseases (Seyyednejad *et al.*, 2010). The plant known as *M. neglecta* is also known as mallow and Marsh mallow. The active substances in the flowers of *M. neglecta* include mucilage, flavonoids, tannins, phenolic compounds and anthocyanins (malvin, delphinidin, malvidin) (Mahlooji *et al.*, 2022). *M. neglecta* shows various effects such as softening, anti-inflammatory and relief of respiratory diseases.

These effects are due to the richness of mucilage-forming substances, especially in the flowers of this plant, which underlines the potential of *M. neglecta* as a valuable traditional medicine. Several studies have confirmed the anti-inflammatory and antioxidant effects of Malva (Afolayan *et al.*, 2010; Marouane *et al.*, 2011). Regarding the effectiveness of natural compositions of *M. neglecta* in the treatment of numerous diseases, their clinically outstanding properties and the lack of study on the effect of *M. neglecta* on the pulmonary fibrosis and inflammation, this study aimed to investigate the therapeutic and preventive effects of hydroalcoholic extract of *M. neglecta* on pulmonary fibrosis and inflammation model in rat.

## 2. Materials and Methods

### 2.1. Preparation of hydroalcoholic extract

In late spring and early summer 2023, the aerial parts of *M. neglecta*, including stems, leaves and flowers, were collected from Marand, East Azerbaijan province, Iran. This plant was approved by Isfahan University of Medical Sciences, Department of Pharmacognosy. After air drying at room temperature (25 °C), the powdered plant (1319 g) was soaked in 5 L of EtOH-H<sub>2</sub>O (7:3) at 37 °C for 24 h. Then, the extract was filtered. The organic solvent was completely evaporated in a vacuum rotary evaporator at a temperature of 40 °C. Finally, the extract was dried using a freeze-drier (Sinijderspoland-Netherlands).

### 2.2. Experimental animals and BLM-induced lung fibrosis

Thirty-six adult male Wistar rats (180 to 200 g) were obtained from the animal house of the Faculty of Pharmacy, Isfahan University of Medical Sciences. Animals are divided to six groups, 6 rats in each. They were kept in standard cage under a 12/12-hour light/dark cycle and room temperature. Animals were treated according to the following schedule:

Control group: Intratracheally normal saline (single dose) on day 1 and normal saline (0.5 mL) by gavage for 28 consecutive days.

Bleomycin group: Intratracheally BLM (7.5 units/kg, single dose) on day 1, normal saline (0.5 mL) was given for 28 consecutive days.

Pirfenidone group: Intratracheally BLM (7.5 units/kg, single dose) on day 1, pirfenidone (100 mg/kg) was administered by gavage for 28 consecutive days.

*M. neglecta* extracts groups: Intratracheally BLM (7.5 units/kg, single dose) on day 1, and *M. neglecta* extract (300, 600, 900 mg/kg) was given by gavage for 28 consecutive days, respectively.

### 2.3. Induction of pulmonary fibrosis

A single injection of bleomycin was given after anesthesia with ketamine. Pulmonary fibrosis was induced in 36 rats by intratracheal injection of bleomycin sulfate (15,000 IU equiv. Standardized biological activity of 15 mg bleomycin)

(BLEOMICINA KEMEX vial, Argentina) dissolved in 0.9% saline as stock solution 7500 IU/ml for immediate use.

#### 2.4. Preparation of pulmonary tissue for histological analysis

Before administration, the rats were anesthetized with ketamine (0.2 mL/kg body weight) and intubated

using a plastic tube. To ensure uniform distribution, 0.5 mL of air was injected twice after bleomycin administration (Fig. 1) (Hübner *et al.*, 2008). After 28 days, the rats were killed under CO<sub>2</sub> anesthesia and the lungs were removed. One lung was preserved in Falcon with 10% formalin for histopathologic examination, while the other lung was used for subsequent molecular analyzes.

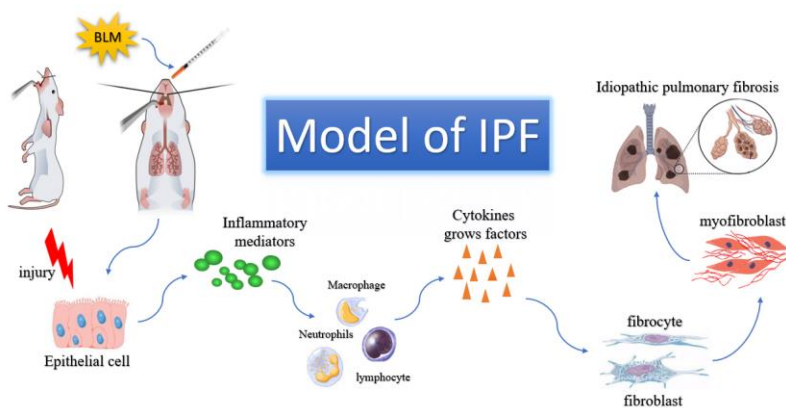


Fig. 1. Model of idiopathic pulmonary

#### 2.5. Histological evaluation

Lung tissue samples were fixed in formalin-fixed, dehydrated through a graded series of alcohols, paraffin-embedded and sectioned at a thickness of 4 micrometers. Serial sections were stained with hematoxylin and eosin (H&E) and Masson's trichrome to assess inflammatory cell infiltration and collagen deposition, respectively. A previously established semiquantitative scoring system was used for blinded assessment of the severity of inflammation and fibrosis in the lung parenchyma (Abidi *et al.*, 2017).

Inflammation Grading:

- Grade 0: No inflammation
- Grade 1: Minimal inflammation
- Grade 2: Mild to moderate inflammation
- Grade 3: Moderate inflammation with thickened alveolar walls
- Grade 4: Moderate to severe inflammation
- Grade 5: Severe inflammation

Fibrosis Grading:

- Grade 0: Normal lung
- Grade 1: Minimal fibrous thickening of alveolar or bronchial walls
- Grades 2-3: Moderate thickening of walls without significant architectural disruption

- Grades 4-5: Increased fibrosis with clear architectural damage and formation of fibrous bands or small masses
- Grades 6-7: Severe structural distortion with large fibrous areas; includes "honeycomb lung"
- Grade 8: Complete fibrotic obliteration of the observed field

The fibrosis score for each lung section was determined by averaging the scores from all sections (Ashcroft *et al.*, 1988).

#### 2.6. Measurement of hydroxyproline

The amount of hydroxyproline in lung tissue was measured using a hydroxyproline measurement kit (Kiazist Company, Hamadan, Iran). The protocol was performed according to the manufacturer's catalog and all measurements were done at 560-540 nm by UV-VIS spectrophotometry. The samples were compared with the obtained standard curve (Soltanfar *et al.*, 2023).

#### 2.7. Measurement of total antioxidant capacity (TAC)

Antioxidants are the body's first line of defense against free radicals. Total antioxidant capacity of homogenized lung tissue was determined by the spectrophotometric CUPRAC (reducing cup antioxidant capacity) method using a commercial kit (Kiazist, Iran) (Mousavi *et al.*, 2022). In this method

(CUPRAC assay), copper ( $\text{Cu}^{+2}$ ) is converted to  $\text{Cu}^{+1}$  and causes a color in the presence of chromogen which is measured at 450 nm. The advantage of this method is the measurement of antioxidants such as thiol, which is not possible in methods such as FRAP (Hosseini-Sharifabad et al., 2021).

### 2.8. Measurement of lipid peroxidation

The content of malondialdehyde (MDA) in tissues was quantified using a colorimetric-fluorimetric lipid peroxidation assay kit (KMDA-96, Kiazist, Iran). Briefly, MDA reacts with thiobarbituric acid (TBA) to form an orange color complex. The absorbance of the complex was measured at 550 nm using an ELISA colorimeter (Kravis et al., 1976).

### 2.9. Statistical analysis

Data values were expressed as mean  $\pm$  SEM (standard error of the mean). For statistical comparison, One-way ANOVA test was used for parametric data and the Tukey post-hoc test for multiple comparisons. The Kruskal-Wallis test was used for non-parametric data. The computer program GraphPad Prism was used for the statistical analysis.

**Table 1.** The effects of *M. neglecta* extract on BLM-induced body changes in animals.

Body weight	C	BLM	P	MN (300)	MN (600)	MN (900)
Initial( $w_0$ )(g)	187.3 $\pm$ 2.64	194.66 $\pm$ 2.1	196.28 $\pm$ 4.11	192.66 $\pm$ 2.45	188.66 $\pm$ 6.10	193.56 $\pm$ 2.45
Final( $w_1$ )(g)	199.5 $\pm$ 1.61	173.33 $\pm$ 3.71	189.42 $\pm$ 7.04	179.46 $\pm$ 5.36	179.46 $\pm$ 4.64	185.73 $\pm$ 3.57
Body weight gain (%)	6.11 $\pm$ 2.76	-12.32 $\pm$ 4.64	-3.6 $\pm$ 1.57	-7.3 $\pm$ 2.15	-5.12 $\pm$ 2.85	-4.2 $\pm$ 5.85

Data are presented as Mean $\pm$ SD; (n = 6). C: Control; BLM: Bleomycin; P: Pirfenidone; MN: *M. neglecta* extract.

### 3.2. Effect of *M. neglecta* extract on bleomycin-induced lipid peroxidation in lung

Lipid peroxidation was assessed by MDA determination and the results are shown in (Fig. 2). The MDA level in the lung was significantly higher in the BLM group than in the control group ( $P < 0.001$ ). In the pirfenidone group, the MDA level was remarkably lower than in the BLM group ( $P < 0.01$ ). A similar result was also found in the *M. neglecta* groups, in which the MDA content decreased significantly compared to the BLM group ( $P < 0.001$ ). Malondialdehyde (MDA) is a by-product of lipid peroxidation. MDA is an aldehyde that can directly damage unsaturated fatty acids, proteins and DNA. MDA is a reliable indicator of inflammation in damaged tissue. Elevated MDA levels have been observed in a variety of inflammatory conditions. Treatment with *M. neglecta* extract reduces the levels of malondialdehyde and free radicals in lung

## 3. Results and discussion

### 3.1. Body weight

The body weight of rats was measured at the beginning and at the end of the experiment. The percentage of body weight gain in each group was compared and calculated.

Death or clinical signs of *M. neglecta* extract poisoning were not detected in any of the experimental groups during this experiment. Body weight variations of rats are given in Table 1.

We noticed a decrease in the body weight in the BLM group from the first to the last day before the sacrifice, but an increase in control group in the same period of time. It is well known that administration of bleomycin in cancer treatment and in lung fibrosis models often results in significant weight loss (Gungor et al., 2020; Esterbauer et al., 1991). Our results showed a significant reduction in the body weight gain percentage in the BLM group compared to control and even other treated groups.

tissue maybe because it is rich source of polyphenols such as quercetin derivatives, coumaric acid, gallic acid, ferulic acid and cinnamic acid derivatives (Saleem et al., 2020; Yang et al., 2018; Guo et al., 2019; Akgedik et al., 2012).

### 3.3. Effect of *M. neglecta* extract on bleomycin-induced hydroxyproline in lung

The amount of collagen deposited in the lung tissue was determined by measuring hydroxyproline. Compared to the control group, bleomycin significantly increased the content of hydroxyproline in the lungs of rats ( $P < 0.01$ ). *M. neglecta* extract significantly and dose-dependently reduced the hydroxyproline content in the treated animals compared to the BLM-treated group. The level of hydroxyproline also decreased significantly in the groups receiving pirfenidone compared to the BLM-treated group ( $P < 0.01$ ) (Fig. 3).

Intratracheal administration of BLM led to a significant increase in the levels of hydroxyproline, malondialdehyde and free radicals in the lung. However, treatment with *M. neglecta* resulted in a significant decrease in hydroxyproline levels in lung tissue. Hydroxyproline is an amino acid that is mainly found in collagen, a major component of the extracellular matrix. In contrast to other amino acids, hydroxyproline contains a hydroxyl group (-OH) on its proline ring. This modification makes the amino acid more stable and resistant to proteolytic degradation, making it a reliable indicator of collagen content even in highly processed or degraded samples (Safaeian et al., 2008).

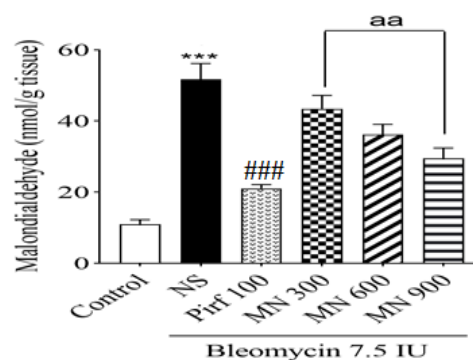
### 3.4. Effect of *M. neglecta* extract on bleomycin-induced total antioxidant capacity (TAC) in lung

The TAC level in the lung tissue of the bleomycin group was significantly lower than that of the control group ( $P < 0.001$ ). In addition, the TAC level in the lung tissue was significantly higher in the pirfenidone and *M. neglecta* groups than in the bleomycin group ( $P < 0.01$ ), but the difference between the group received 900 mg/kg of *M. neglecta* extract and pirfenidone group was not significant ( $P > 0.05$ ) (Fig. 4). The highest dose (900 mg/kg) showed the most pronounced antioxidant effect among the treated groups. Medicinal herbs rich in polyphenols, such as *M. neglecta*, exhibit significant antioxidant and anti-inflammatory properties (Guder and Korkmaz, 2012). According to previous studies, phytochemical analysis of *M. neglecta* has shown the presence of quercetin derivatives, coumaric acid, gallic acid, ferulic acid and cinnamic acid derivatives (Saleem et al., 2020). Quercetin accelerates wound healing by effectively modulating cytokine growth factors (Gopalakrishnan et al., 2016). Gallic acid and its derivatives have also strong antioxidant properties.

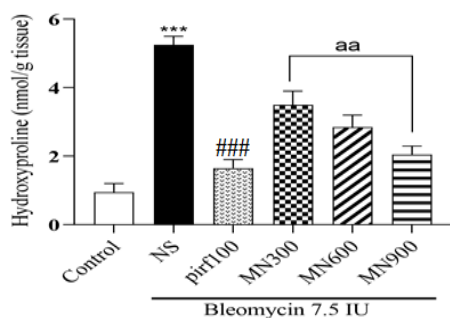
### 3.5. Effect of *M. neglecta* extract on Histopathological findings

Microscopic examination of the lung tissue of the control rats (without bleomycin) revealed normal bronchial and alveolar spaces and normal thickening of the alveolar septa. The main histopathologic findings in the bleomycin group were disruption of the alveolar structure, severe necrosis, heavy infiltration of inflammatory cells (predominantly mononuclear cells including macrophages and lymphocytes and fewer

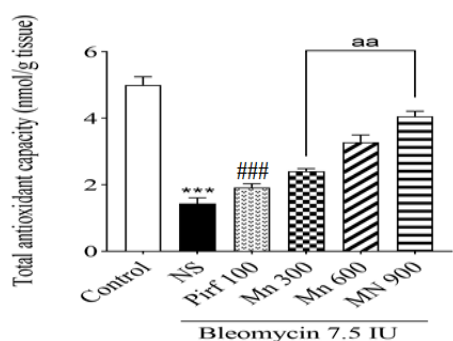
neutrophils) in the interstitial area along with many collagens. The pattern of lesions in the groups treated with hydroalcoholic extracts of *M. neglecta* was clearly elucidated. The extent and severity of the lesions, especially the development of necrosis, inflammation and fibrosis, were significantly less compared to the bleomycin-treated group. Among the treated groups, most therapeutic effects were observed with the administration of the hydroalcoholic extract. In general, a high dose of the extracts (900 mg/kg) showed a stronger preventive effect on the damaged lungs than lower doses (Fig. 5). To confirm the effect of *M. neglecta* extracts on bleomycin-induced lung injury, a semi-quantitative assessment of the severity and extent of inflammation in the lung sections was performed by numerical scoring (Fig. 6). According to the observations on the sections stained with Masson's trichromacy, the fibrosis score was significantly increased in the rats treated with bleomycin, while this score was significantly reduced in the rats treated with different doses of extracts and pirfenidone (Fig. 7). We hypothesize that *M. neglecta* may have a protective effect against pulmonary fibrosis by reducing the production of reactive oxygen species (ROS) in the bleomycin-induced lung injury model due to its potent antioxidant properties. The observed reduction in histological pathology supports this hypothesis and suggests that *M. neglecta*, possibly through its polyphenolic compounds, has the ability to neutralize oxidative stress and scavenge free radicals, thus providing potential benefits in reducing pulmonary fibrosis.



**Fig. 2.** Effect of *M. neglecta* extract on the malondialdehyde level in lung tissue. Data are given as mean  $\pm$  SEM ( $n=6$ ). NS: bleomycin, Pirf: pirfenidone, MN: *M. neglecta* extract (\*\*\*)  $P < 0.05$  vs. control, ###  $P < 0.001$  vs. control, aa  $P < 0.05$ ).



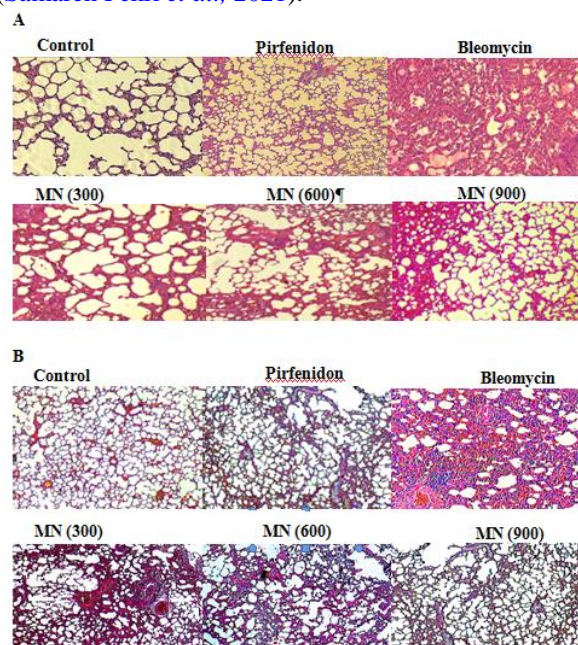
**Fig. 3.** Effect of *M. neglecta* extract on the hydroxyproline level in lung tissue. Data are given as mean  $\pm$ SEM (n=6). NS: bleomycin, Pirf: pirfenidone, MN: *M. neglecta* extract (\*\*\*) P<0.05 vs. control, ### P<0.001 vs. control, aa P<0.05).



**Fig. 4.** Effect of *M. neglecta* extract on total antioxidant capacity in lung tissue. Data are expressed as mean  $\pm$ SEM (n=6). NS: bleomycin, Pirf: pirfenidone, MN: *M. neglecta* (\*\*\*) P<0.05 vs. control, ### P<0.001 vs. control, aa P<0.05).

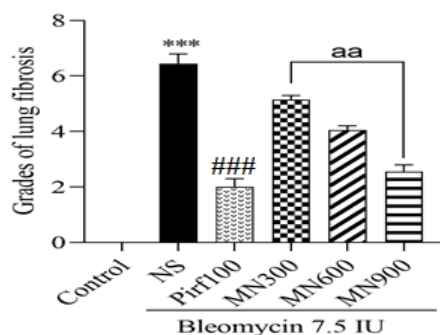
Pulmonary fibrosis is a progressive disease characterized by an increased concentration of inflammatory mediators, increased collagen deposition and increased cell proliferation in the interstitial tissue (Kim et al., 2015). Fibroblasts and myofibroblasts play a central role in collagen synthesis, which ultimately leads to impaired lung function (Kravis et al., 1976). The study by Reddy and Evameka has shown that the increase in hydroxyproline levels in lung tissue is related to the progression of lung disease (Wynn and Ramalingam, 2012). Oxidative stress and inflammation are critical components of the complex pathophysiology of pulmonary fibrosis (Gungor et al., 2020). Given the lack of documented, effective and specific treatments for pulmonary fibrosis, the focus is on implementing risk mitigation measures to reduce the likelihood of exacerbation of lung damage. The

treatment of pulmonary fibrosis is proving to be a difficult task with only modest success to date (Hasan et al., 2022). The bleomycin-induced model is the predominant and widely accepted approach to the study of pulmonary fibrosis (PF) in animal-based research (Gao et al., 2023). For centuries, traditional medicine has been a mainstay of healthcare that goes beyond mere symptom relief to encompass holistic therapeutic approaches. Recent scientific research has revealed fascinating prospects in this area, particularly in relation to pulmonary fibrosis. This optimism stems from their proven ability to modulate inflammatory cascades and counteract oxidative stress pathways – key processes involved in fibrotic remodeling (Samareh Fekri et al., 2021).

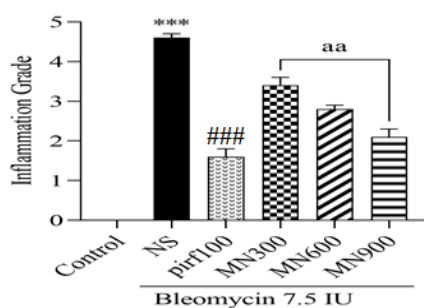


**Fig. 5.** Development of histological changes in the rat lung after instillation of BLM and/or treatment with *M. neglecta* extract. (A) Hematoxylin and eosin. In the bleomycin group, severe inflammation, disruption of the alveolar structure with the presence of lymphoid follicles and significant interstitial thickening were observed. In the groups treated with pirfenidone and *M. neglecta* extract, the inflammation and degree of fibrosis decreased significantly. (B) Lung tissue stained with Masson's trichrome. Collagen is stained blue and cells are stained red. Focused sections show an increased presence of collagen (blue), cellular infiltration, alveolar edema and an inflammatory infiltrate of the septa in the peribronchovascular area, which gradually gives way to a particularly pronounced

fibrotic infiltrate (magnification, 200; scale bar, 100  $\mu$ m).



**Fig. 6.** The resulting data were expressed as the product of the extent of fibrosis in the form of mean $\pm$ SEM (n=6). A one-way anova was used for statistical comparison NS: bleomycin; Pirf100:pirfenidone; MN: *M. neglecta* extract (\*\*P<0.05 vs. control, ###P<0.001 vs. control, aa P<0.05).



**Fig. 7.** Numerical evaluation of the severity and extent of inflammation in the rat lung. During microscopic examination, each field was graded according to the following scheme: Grade 0 for normal tissue and Grade 1-5 for the presence of lung inflammation. The collected data are expressed as multiplication of severity and extent of inflammation and presented as mean  $\pm$  SEM (n=6). The Kruskal-Wallis test was used for statistical comparison (\*\*P<0.05 vs. control, ###P<0.001 vs. control, aa P<0.05).

#### 4. Conclusion

In animal models, extracts of *M. neglecta* showed systemic anti-inflammatory and antifibrotic activities and reduced biochemical and histopathological indices of pulmonary fibrosis. It is therefore suggested to use *M. neglecta* concomitantly with chemotherapy with anticancer drugs such as bleomycin to prevent the development of pulmonary fibrosis. In addition, an oral

drug preparation of *M. neglecta* extracts would have a positive anti-inflammatory effect in patients with obstructive pulmonary disease and asthma.

#### 5. References

- Abidi, A., Robbe, A., Kourda, N., Khamsa, S.B. and Legrand, A. 2017. *Nigella sativa*, a traditional Tunisian herbal medicine, attenuates bleomycin-induced pulmonary fibrosis in a rat model. *Biomedicine and Pharmacotherapy*, 90: 626-637.
- Afolayan, A.J., Aboyade, O.M., Adedapo, A.A. and Sofidiya, M.O. 2010. Anti-inflammatory and analgesic activity of the methanol extract of *Malva parviflora* Linn (Malvaceae) in rats. *African Journal of Biotechnology*, 9(8):1225-1229.
- Afshari-Kaveh, M., Abbasalipourkabir, R., Nourian, A. and Ziamajidi, N. 2021. The protective effects of vitamins A and E on titanium dioxide nanoparticles (nTiO<sub>2</sub>)-induced oxidative stress in the spleen tissues of male Wistar rats. *Biological Trace Element Research*, 199:3677-3687.
- Akgedik, R., Akgedik, Ş., Karamanlı, H., Uysal, S., Bozkurt, B., Ozol, D., et al. 2012. Effect of resveratrol on treatment of bleomycin-induced pulmonary fibrosis in rats. *Inflammation*, 35:1732-1741.
- Ashcroft, T., Simpson, J.M. and Timbrell, V. 1988. Simple method of estimating severity of pulmonary fibrosis on a numerical scale. *Journal of Clinical Pathology*, 41(4):467-470.
- Esterbauer, H., Schaur, R.J. and Zollner, H. 1991. Chemistry and biochemistry of 4-hydroxynonenal, malonaldehyde and related aldehydes. *Free Radical Biology and Medicine*, 11(1):81-128.
- Gao, C., Bai, Y., Zhou, H., Meng, H., Wu, T., Bai, W., et al. 2023. Effects of N-butanol extract of *Amygdalus mongolica* on rats with bleomycin-induced pulmonary fibrosis based on metabolomics. *Brazilian Journal of Medical and Biological Research*, 56:e13045.
- Ghasemi Dehkordi, N., Sajadi, S., Ghanadi, A., Amanzadeh, Y., Azadbakht, M., Asghari, G.R., et al. 2002. Iranian herbal pharmacopoeia. Tehran: Ministry of health and medical education. 6(3):63-69.
- Glass, D.S., Grossfeld, D., Renna, H.A., Agarwala, P., Spiegler, P., DeLeon, J. and Reiss, A.B. 2022. Idiopathic pulmonary fibrosis: Current and future

- treatment. *The Clinical Respiratory Journal*, 16(2): 84-96.
- Gopalakrishnan, A., Ram, M., Kumawat, S., Tandan, S. and Kumar, D. 2016. Quercetin accelerated cutaneous wound healing in rats by increasing levels of VEGF and TGF- $\beta$ 1. *Indian Journal of Experimental Biology*, 54(3):187-195.
- Güder, A. and Korkmaz, H. 2012. Evaluation of in-vitro antioxidant properties of hydroalcoholic solution extracts *Urtica dioica* L., *Malva neglecta* Wallr. and their mixture. *Iranian Journal of Pharmaceutical Research*, 11(3):913.
- Gungor, H., Ekici, M., Onder Karayigit, M., Turgut, N.H., Kara, H. and Arslanbas, E. 2020. Zingerone ameliorates oxidative stress and inflammation in bleomycin-induced pulmonary fibrosis: modulation of the expression of TGF- $\beta$ 1 and iNOS. *Naunyn-Schmiedeberg's Archives of Pharmacology*, 393:1659-1670.
- Guo, J., Yang, Z., Jia, Q., Bo, C., Shao, H. and Zhang, Z. 2019. Pirfenidone inhibits epithelial-mesenchymal transition and pulmonary fibrosis in the rat silicosis model. *Toxicology Letters*, 300:59-66.
- Hasan, M., Paul, N.C., Paul, S.K., Saikat, A.S.M., Akter, H., Mandal, M. and Lee, S.S. 2022. Natural product-based potential therapeutic interventions of pulmonary fibrosis. *Molecules*, 27(5):1481.
- Hosseini-Sharifabad, A., Sadraei, H., Hashemnia, M., Sajjadi, S.E. and Mirdamadi, Z. 2021. Effect of hydroalcoholic and aqueous extracts of *Dracocephalum kotschyi* on bleomycin induced pulmonary fibrosis. *Journal of Herbmed Pharmacology*, 10(2): 209-217.
- Hübner, R-H., Gitter, W., Eddine, E., Mokhtari, N., Mathiak, M., Both, M., Bolte, H., et al. 2008. Standardized quantification of pulmonary fibrosis in histological samples. *Biotechniques*, 44(4): 507-517.
- Kim, H.J., Perlman, D. and Tomic, R. 2015. Natural history of idiopathic pulmonary fibrosis. *Respiratory Medicine*, 109(6): 661-670.
- Kravis, T.C., Ahmed, A., Brown, T., Fulmer, J. and Crystal, R. 1976. Pathogenic mechanisms in pulmonary fibrosis: collagen-induced migration inhibition factor production and cytotoxicity mediated by lymphocytes. *The Journal of Clinical Investigation*, 58(5): 1223-1232.
- Kroes, Bv., Van den Berg, A., Van Ufford, H.Q., Van Dijk, H. and Labadie, R. 1992. Anti-inflammatory activity of gallic acid. *Planta medica*, 58(06): 499-504.
- Marouane, W., Soussi, A., Murat, J-C., Bezzine, S. and El Feki, A. 2011. The protective effect of *Malva sylvestris* on rat kidney damaged by vanadium. *Lipids in Health and Disease*, 10:1-8.
- Mouratis, M.A. and Aidinis, V. 2011. Modeling pulmonary fibrosis with bleomycin. *Current Opinion in Pulmonary Medicine*, 17(5):355-361.
- Mousavi, M., Abedimanesh, N., Mohammadnejad, K., Sharini, E., Nikkhah, M., Eskandari, M.R., et al. 2022. Betanin alleviates oxidative stress through the Nrf2 signaling pathway in the liver of STZ-induced diabetic rats. *Molecular Biology Reports*. 49(10):9345-9354.
- Nwafor, E-O., Lu, P., Liu, Y., Peng, H., Qin, H. and Zhang, K. 2021. Active components from traditional herbal medicine for the potential therapeutics of idiopathic pulmonary fibrosis: a systemic review. *The American Journal of Chinese Medicine*, 49(05):1093-1114.
- Romero, F.J., Bosch-Morell, F., Romero, M.J., Jareño, E.J., Romero, B., Marín, N. and Romá, J. 1998. Lipid peroxidation products and antioxidants in human disease. *Environmental Health Perspectives*, 106(suppl 5):1229-1234.
- Safaeian, L., Jafarian, A., Rabbani, M., Sadeghi, H., Torabinia, N. and Alavi, S. 2008. The role of strain variation in BAX and BCL-2 expression in murine bleomycin-induced pulmonary fibrosis. *Pakistan Journal of Biological Sciences*, 11(23):2606.
- Sankari, A., Chapman, K. and Ullah, S. 2024. Idiopathic pulmonary fibrosis. StatPearls Publishing. PMID: 28846333.
- Saleem, U., Khalid, S., Zaib, S., Anwar, F., Ahmad, B., Ullah, I., et al. 2020. Phytochemical analysis and wound healing studies on ethnomedicinally important plant *Malva neglecta* Wallr. *Journal of Ethnopharmacology*, 249:112401.
- Samareh Fekri, M., Poursalehi, H.R., Sharififar, F., Mandegary, A., Rostamzadeh, F. and Mahmoodi, R. 2021. The effects of methanolic extract of *Glycyrrhiza glabra* on the prevention and treatment of bleomycin-induced pulmonary fibrosis in rat: experimental study. *Drug and Chemical Toxicology*, 44(4):365-371.
- Seyyednejad, S.M., Koochak, H., Darabpour, E. and Motamedi, H. 2010. A survey on *Hibiscus rosa*—



- sinensis, *Alcea rosea* L. and *Malva neglecta* Wallr as antibacterial agents. *Asian Pacific Journal of Tropical Medicine*, 3(5):351-355.
- Soltanfar, A., Meimandi Parizi, A., Foad-Noorbakhsh, M., Sayyari, M. and Iraj, A. 2023. The healing effects of thymoquinone on experimentally induced traumatic tendinopathy in rabbits. *Journal of Orthopaedic Surgery and Research*, 18(1):233.
- Wynn, T.A. and Ramalingam, T.R. 2012. Mechanisms of fibrosis: therapeutic translation for fibrotic disease. *Nature Medicine*, 18(7):1028-1040.
- Yang, D-x., Qiu, J., Zhou, H.H., Yu, Y., Zhou, D., Xu, Y., et al. 2018. Dihydroartemisinin alleviates oxidative stress in bleomycin-induced pulmonary fibrosis. *Life Sciences*, 205:176-183.
- Yousefi-Manesh, H., Noori, T., Asgardoost, M.H., Derakhshan, M.H., Tavangar, S.M. and Sheibani, M. 2022. Protective effect of dapsone against bleomycin-induced lung fibrosis in rat. *Experimental and Molecular Pathology*, 124:104737.