



Histomorphological study of the effect of *Biarum straussiis*' rhizome extract on cutaneous wound healing in a rat model

Sahar Ekradi¹, Tahereh Momeni Isfahani^{*1}, Mohammad Alimoradi¹, Masoumeh Khanahmadi²

¹Department of Chemistry, Arak Branch, Islamic Azad University, Arak, Iran;

*Email: t.momeni@iau-arak.ac.ir

²Department of Research Chemistry, ACER (Jahad-E-Daneshgahi), Kermanshah Unite, 67149, Iran;

ARTICLE INFO

Type: Original Research

Topic: Medicinal Plants

Received June 28th 2020

Accepted October 12th 2020

Key words:

- ✓ *Biarum straussii*
- ✓ Phytomedicine
- ✓ Rhizome extract
- ✓ Wound healing

ABSTRACT

Background & Aim: Phytomedicine or herbal medicine, refers to the use of plants to treat diseases and promote good health. Anti-oxidative and anti-inflammatory characteristics of the medicinal herbs make them logical adjuvant to improve wound healing. The aim of this study was to evaluate the wound healing potential of *Biarum straussiis*' (*B. straussii*) rhizome extract on cutaneous wounds in rats.

Experimental: Adult male rats (n=18) were divided into three groups (n=6), as group A, B and C. Then, full-thickness, square shape cutaneous wounds were created on the skin. In group A, as negative control, the wound area was only washed using normal saline solution; in group B as positive control, the wound was treated using phenytoin and the wound treatment using *B. straussii* rhizome extract was done in group C, as experimental subject. The progressive changes in wounds of each group were evaluated for the contraction degree on days 4,7,10 and 14. The tissue samples of the wound area were removed from each group on day 14, fixed in 10% formalin and finally stained with H&E for histological examination. Data analysis was carried out using one-way ANOVA test, followed by Tukey-Kramer test ($P<0.05$).

Results: The wound contraction was higher in group treated with *B. straussii* extract than in control group at 7th, 10th and 14th days ($P<0.0001$). The histological analysis showed a significant accelerated wound contraction, complete re-epithelialization, and tissue recovery due to the topical application of *B. straussii* rhizome extract.

Recommended applications/ industries: It can be concluded that the rhizome extract of *B. straussii* is favorable for cutaneous wound healing in rats and would be considered as a medicinal plant, but further studies are required to reach more definitive results.

1. Introduction

The Complementary and Alternative Medicines (CAMs) are gaining interest as an exclusive treatment of a variety of conditions all over the world (Mori, Kawanami, Kawahata and Aoki, 2016). Among various CAMs, herbal medicines have especially received attention mainly for their potentially active substances.

Plants from different genera are unlimited sources of a huge range of various substances; they are able to act as defense agents against the environmental aggressions (Khemiri et al., 2019; Riyazzudin et al., 2016) and promote healing and angiogenesis (Estevo et al., 2013). Healing is a natural complex phenomenon with systemic and physiological processes where the body is required to activate, inhibit, and produce several components. These cellular and molecular

components are organized in order to contribute to the recovery process as well as the function of damaged tissues (Pessoa *et al.*, 2012)

The use of various types of herbal medication to enhance tissue regeneration and wound healing are being gradually popular. Phytomedicine as a field of medicine, refers to the use of plants and herbs either to treat disease or promote health agents. Traditional phytotherapies generally preserved the original composition and integrity of the source plant, while in new phytomedicines, the active compounds of plants such as alkaloids and flavonoids, are preserved to improve the effectiveness and decrease the harmful side effects of herbal medicines (Falzon and Balabanova, 2017; Ghashghaii *et al.*, 2017).

Biarum straussii (*B. straussii*), a new endemic species from Iran, is a flowering plant in the family Araceae. *Biarum* genus is native to North Africa, South Europe (Balkans, Italy, Spain, and Portugal) as well as the Middle East (Iran, Iraq, Turkey, and Syria) (Bogner and Boyce, 1989; Boyce, 2008; Valizadeh and Rafieirad, 2016). All *Biarum* species have a seasonal growth regime, and the majority of species including *B. straussii* blossom in autumn and early winter (Boyce, 1999). The presence of the anthocyanins and flavonoids in Aracea order, was first reported by Williams and colleagues in 1981 (Williams *et al.*, 1981). Also, the existence of alkaloids, amines, cinnamic acids, and saponins in this order has been authenticated. Flavonoids are a wide spectrum of the polyphenolic compounds, distributing extensively in photosynthesizing cells. The polyphenolic compounds are known for their numerous pharmacological usages (Valizadeh and Rafieirad, 2016) because of linear relationship between phenolic contents and antioxidant activities (Hosseini *et al.*, 2012).

The protection of cells against oxidative damages by antioxidant activities of phenolic compounds has been well recognized (Hosseini *et al.*, 2012). The plants are rich sources of antioxidant metabolites which have strong potentials in eradicating the free radicals from the cells (N28) and these antioxidant metabolites are found in each part of plants such as leaf, skin, fruit, seed, and root (Georgiev *et al.*, 2014). As the several experiments have indicated that antioxidants with herbal source are effective in healing action (Estevao *et al.*, 2013; Ghashghaii *et al.*, 2017; Khemiri *et al.*, 2019; Mori *et al.*, 2016), here in, we focused on the wound

healing potential of *B. straussii*' rhizome extract on the treatment of cutaneous wounds in rats.

2. Materials and methods

2.1. Preparation of *Biarum straussii* extract

The mature *B. straussii* were collected locally during the months of September and October 2019 from highlands of Sahneh city (Kermanshah Province, West of Iran). The genus was approved by the Razi University Herbarium in Kermanshah Province, Iran. The plant was first cleaned and washed to remove all contaminations and then the rhizome was separated and divided into small pieces, mechanically. Then, the rhizome pieces were dried by an incubator at a temperature of 80°C for 48 h and then powdered with an electric blender. The 200 g of powder was added to Erlenmeyer flask containing 800 ml of methanol and shaken for 48 h while filtered subsequently. This process was repeated three times to obtain maximal extraction. In the following step, the solvent was evaporated at 60°C. The obtained extract was mixed with cold cream (as a basal cream) at a concentration of 10%.

2.2. Animals

Eighteen healthy adult male Wistar rats, weighing 200-220 g, with three months of age were obtained from the School of Pharmacy, Kermanshah University of Medical Sciences. The animals were housed in individual boxes at constant temperature (23-25°C) and relative humidity (55±5%), under 12-hour light/dark cycle; their chow and water were provided according to libitum standard laboratory diet (70% carbohydrates, 25% proteins, 5% lipids) and animals were adapted to laboratory conditions for one week before the experiment. Efforts were made to use the smallest possible number of animals as well as to ensure minimum animal suffering. All animal treatments were carried out in accordance with US NIH guidelines for the care and use of Laboratory animals and it was approved by ethical committees of Kermanshah University of Medical Science, Kermanshah, with number IR. IAUA. 1397.398.

2.3. Wound creation and treatment

All animals were anesthetized with a combination of ketamine (100 mg/kg) and xylazine (20 mg/kg)

(Merck, Germany), administered intraperitoneally. The anterior dorsal fur of each rat was shaved using an electric clipper and the skin was cleaned with 70% ethanol. Then, the area was marked and a square shape full thickness excision (25 mm in diameter) was created by removing a patch of skin under aseptic conditions. The wound was left uncovered and without any local or systemic antimicrobial drugs administration. All 18 rats were randomly divided into three main groups, each containing 6 animals as follows:

Group A: negative control (without treatment)

Group B: positive control (wound treatment using phenytoin)

Group C: experimental subject (wound treatment with 10% *B. straussii* rhizome extract)

The phenytoin for group B and the cream containing rhizome extract for group C were applied topically on the wound area, immediately after surgical excision, twice a day and for 14 consecutive days. Normal saline solution was applied to wash the wound in group A. All rats in three groups were monitored for any wound fluid and any infection. On the day 14, rats were euthanized by increasing the anesthesia (via ketamine and xylazine) and the wound granulation tissues formed were carefully removed and used for further analysis.

2.4. Wound healing assay

The progressive changes in wounds of each group were measured with the aid of a caliper graph on days 4,7,10 and 14, to estimate the wound closure as the reduction of the original wound size. The calculation of the average degree of closure was expressed as percentages using the following formula:

% Wound closure = [(Initial wound size - Particular day wound size) / Initial wound size] × 100

2.5. Histological examination

The tissue samples of the wound area of each animal were removed on day 14 and fixed in 10% formalin for 7 days. Following dehydration in an ethanol solution of increasing concentrations and clearance in xylene, the samples were embedded in paraffin. Then tissue were sectioned with 5 μm thickness and stained with hematoxylin and eosin (H&E) for histological examination using a light microscope (Bancroft and Gamble, 2002).

2.6. Statistical analysis

Data analysis was carried out using the SPSS V.20 (SPSS Inc., Chicago, Illinois, USA). The means of wound area measurements between groups was compared using a one-way ANOVA (analysis of variance), followed by Tukey-Kramer post hoc test. All numerical values were expressed as mean ± SEM and *P* value < 0.05 was considered statistically significant.

3. Results and discussion

The skin as a vital organ in the human body, is a protective barrier against the external environment which is rich in various pathogens, inducing the simplest to the most severe diseases. The wound healing is a very complex innate program which could be categorized into four overlapping and well established phases; 1) haemostasis to stop the subsequent loss of blood from injured vessels, 2) inflammation, 3) proliferation including granulation, angiogenesis, tissue contraction, and re-epithelialization, and finally 4) remodeling phase for tissue recovery after wound closure (Kasuya and Tokura, 2014; Khémiri *et al.*, 2019; Labib *et al.*, 2019; Nejati, Farahpour and Nagadehi, 2015). Although wound healing is a natural process, management is often mandatory to prevent occurrence of infections as well as reduction of healing period (Adams, Bateman, Bik and Meadow, 2015; Keller and Tomecki, 2011). Tissue aseptic operation, suturing, and disinfected therapies are thought to be improper for healing the some injured tissue. During recent years, a resurgence of several infections have been shown by clinical experiences that accompanied the occurrence of new infectious diseases (Farahpour *et al.*, 2018; Manzuorh *et al.*, 2019; Ruppen *et al.*, 2018; Wikaningtyas and Sukandar, 2016). Moreover, most drugs including available antimicrobials to treat several infections, have been reported to induce harmful side effects (Khemiri *et al.*, 2019). Therefore, it has become imperative to quest for new medications and therapies.

Phytomedicine as an alternative medicine has been considered by many ethnopharmacological researchers to improve new medical therapies. The high amount of alkaloids, flavonoids, saponins, tannins, triterpenes, and naphthoquinone in medicinal plants have attracted the scientists to clarify the biological and physiological activities of these components (Ghashghaii *et al.*, 2017;

Hashemnia et al., 2014; Oryan et al., 2012). Some in vitro and in vivo experiments, have demonstrated the ability of these components as anti-viral, anti-inflammatory, anti-tumor, anti-carcinogenic (Penna et al., 2003) as well as antihyperglycemic agents (Gallagher et al., 2003).

Also, several clinical trials and animal experiments have been conducted by researchers in the field of wound healing, in which the potential of medicinal plants extracts such as alcoholic and hydro-alcoholic extracts as well as essential oils have strongly suggested to manage the quality and healing rate particularly in cutaneous wounds (Estevao et al., 2013; Ghashghaii et al., 2017; Khemiri et al., 2019; Labib et al., 2019; Mori et al., 2016; Nayak et al., 2008; Nejadi et al., 2015; Oryan et al., 2012; Takzaree, et al., 2020).

The current investigation was focused on healing potential of the *Biarum straussii*' rhizome alcoholic extract for the treatment of cutaneous wounds in rats. As mentioned earlier, *B. straussii* belongs to the order of Araceae, which the antioxidant characteristics due to the existence of flavonoids in this order has been justified 4 decades ago (Williams et al., 1981).

In a survey, conducted by Valizadeh and Rafieirad (2017), hydro-alcoholic extract of other species of *Biarum* genus as *B. Bovei* was studied in diabetic male rats. They observed the reduction of blood glucose and complications of diabetes such as lipid profiles. Finally, they concluded that the hydro-alcoholic extract of *B. Bovei* may has antioxidant characteristics which can be used to improve diabetes along with medication (Valizadeh and Rafieirad, 2016).

The *B. straussii* is a new endemic species from Iran that blossom in autumn and early winter like the majority of species in *Biarum* genus (Boyce, 1999). This plant is obtained from the highlands of Sahneh city (Kermanshah, West of Iran). The rhizome of *B. straussii* is used in folk medicine to stop the bleeding of cutaneous wounds. But, there is no scientific report about pharmacological effects of this species such as, anti-microbial, antitumoral, and anti-inflammatory effects. Hence, we designed our study based on folk people experiences and focused on the effect of rhizome alcoholic extract of *B. straussii* to heal cutaneous wound in animal model.

A total of 18 male rats were randomly divided into three main groups (n=6). In group A as negative control, the wound area was only washed using normal saline solution; in group B as positive control, the wound was treated using phenytoin and the wound treatment using *B. straussii* 10% was done in group C, as experimental subject. The phenytoin for group B and *B. straussii* 10% for group C were applied topically on the wound area.

Also wounds in all groups were left uncovered and without any local or systemic antimicrobial drugs administration. All animals in three groups were monitored for any wound fluid and any infection. The observation of wound healing on days 4,7,10 and 14 showed a significant reduction in the wound size in the treated group using *B. straussii* rhizome extract (C) compared to two other groups (A and B) (Table 1, Figure 1).

Table 1. Wound size (Mean \pm SEM) in different treated groups during the experimental process (n = 6).

Days/ Groups	Change of wound size (mm ²)				
	0	4	7	10	14
Group A	49 \pm 0.44	44.50 \pm 0.45	40.23 \pm 0.61	23.02 \pm 0.63	15.55 \pm 0.45
Group B	49 \pm 0.33	42.40 \pm 0.61	39.06 \pm 0.54	20.11 \pm 0.13	11.25 \pm 0.76
Group C	49 \pm 0.50	40.04 \pm 0.23	32.02 \pm 0.51	9.32 \pm 0.15	2.31 \pm 0.05

Group A: negative control (untreated)

Group B: positive control (treated with phenytoin)

Group C: experimental subject (treated with *B. straussii* rhizome extract).

Moreover, the wound closure calculation represented that topical application of *B. straussii* rhizome extract (10%) caused a significant ($P<0.0001$) increase in the wound closure in the experimental subject, compared to that of the negative and positive controls.

Actually, compared to negative control, both phenytoin and *B. straussii* rhizome extract had beneficial effects on wound healing. The healing process in the group C was more considerable, especially in days of 7, 10 and 14 compared to the other two groups (Figure 2).

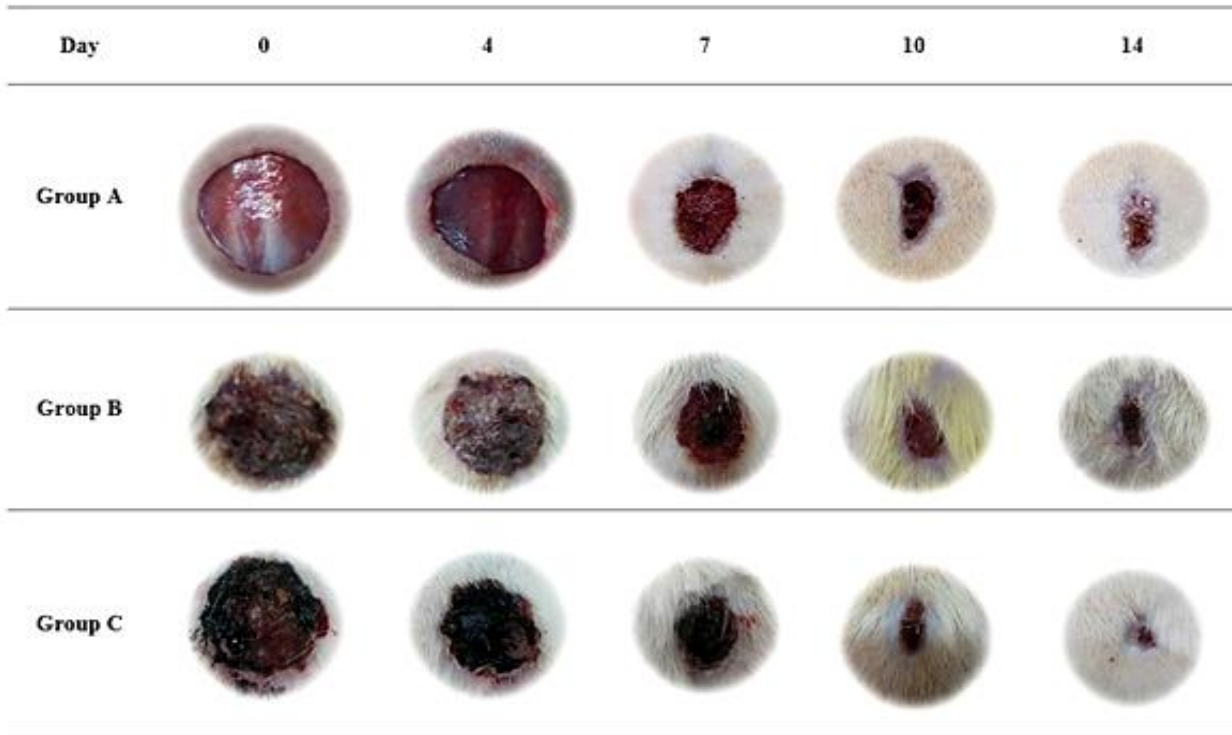


Figure 1. Representative photographs of wound closure in rat models on days 4, 7, 10 and 14 in three studied groups. Group A (untreated), group B (treated with phenytoin), and group C (treated with 10% concentration of *B. straussii* rhizome extract). The significant improvement of the wound healing process was observed in group C, with topical application of *B. straussii* rhizome extract compared to the other two groups.

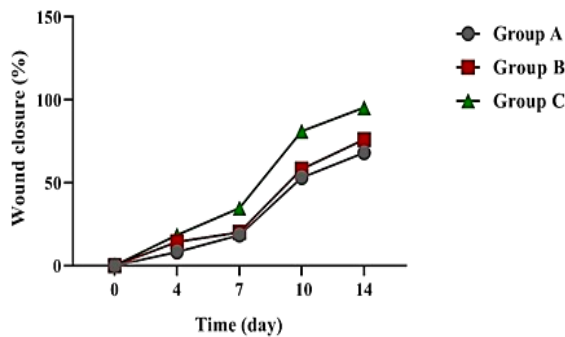


Figure 2. The comparison of wound healing process on days 4, 7, 10 and 14 in three studied groups (Group A (untreated), group B (treated with phenytoin), and group C (treated with *B. straussii* rhizome extract)).

A research conducted by Ghashghai *et al.* (2017) showed a wound contraction and healing acceleration in rats after using the alcoholic extract of *Scrophularia striata* (*S. striata*). This plant is a well-known plant in Iranian traditional medicine with anti-oxidative and anti-inflammatory characteristics. Treated rats with *S. striata* extract showed a decreased number of

lymphocytes and enhanced number of fibroblasts at the earlier stages of wound healing. They also demonstrated best wound healing activity with significant changes in other parameters such as re-epithelialization and epithelial formation as well as enhanced maturity of collagen fibers and fibroblasts, compared to control (Ghashghai *et al.*, 2017).

In this study, histological observation of wound healing on day 14 showed a retarded wound healing, dermal disorganization and inflammatory cells infiltration in negative control (group A); representing the persistence of the inflammatory process in this group. In the phenytoin group (B) a continuous but thin epithelium showed a full re-epithelialization of the skin, indicating the acceleration of wound healing process due to the topical application of phenytoin. In group C (treated with rhizome extract) the reduced inflammation was observed. Also, tissue regeneration and re-epithelialization as well as synthesis of extracellular matrix components was enhanced considerably. Epithelium regenerating and dermis extracellular matrix organization was evident in

rhizome extract and phenytoin treated groups compared to the normal saline treatment, while the rats in group C showed considerable re-epithelialization (Figure 3). In normal saline and phenytoin treated groups, the

presence of inflammatory cells was prominent within the granulation tissue, however, as in group C, there were no signs of infection around the wound area in these groups (Figure 3).

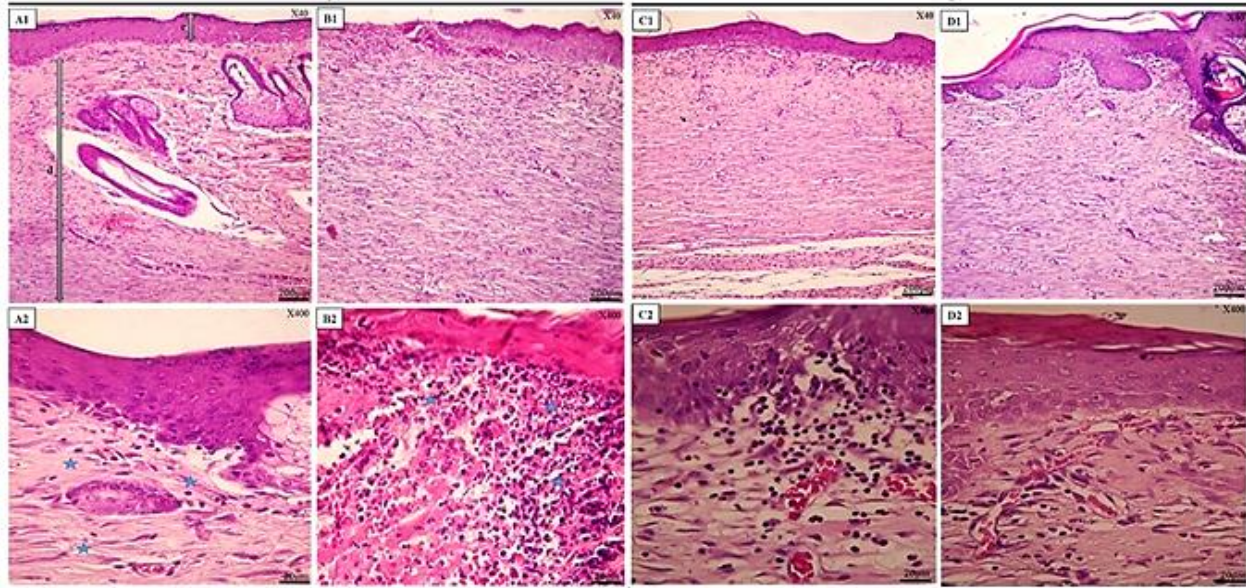


Figure 3: Representative images of H&E staining skin sections of the three experimental groups as well as normal skin. (A) Normal skin, (B) Negative control (untreated), (C) Positive control (treated with phenytoin), (D) experimental subject (treated with *B. straussii* rhizome extract). In *B. straussii* extract (10%) treated group (D) the wound inflammatory process was reduced and tissue regeneration and epithelialization was enhanced compared to control groups. Star: cell and connective tissue. Magnification x40 (A₁, B₁, C₁, D₁) and x400 (A₂, B₂, C₂, D₂).

4. Conclusion

In summary, this study, even if preliminary, demonstrated that rhizome alcoholic extract of *Biarum straussii* has healing potential on cutaneous wounds in rats. Since, in this study, accelerated wound closure, complete re-epithelialization, and tissue recovery after wound closure was observed due to the topical application of *Biarum straussii* rhizome extract (10%), we concluded that *Biarum straussii* was favorable for wound healing process in rat cutaneous wounds. Also, it's expected that this alcoholic extract could be effective as an antimicrobial agent in the healing process. But further large cohort studies are needed to approve these effects even on humans.

5. References

Adams, R.I., Bateman, A.C., Bik, H.M. and Meadow, J.F. 2015. Microbiota of the indoor environment: a meta-analysis. *Microbiome*, 3(1): 49-66.

- Bancroft, J. and Gamble, M. 2002. Theory and practice of histological and histochemical techniques. Butter Worths Churchill Livingstone, New York, NY, USA.
- Bogner, J. and Boyce, P. 1989. A remarkable new *Biarum* (Araceae) from Turkey. *Willdenowia*, 409-417.
- Boyce, P.C. 1999. *Biarum mendax* (Araceae: Araceae), a new species from Southwest Spain. *Aroideana*, 22: 90-91.
- Boyce, P.C. 2008. A taxonomic revision of *biarum*: Araceae. *Curtis's botanical magazine*, 25(1): 2-17.
- Estevao, L.R.M., Mendonça, F.D.S., Baratella-Evencio, L., Simoes, R.S., Barros, M.E.G.D., Arantes, R.M.E. and Evencio-Neto, J. 2013. Effects of aroeira (*Schinus terebinthifolium* Raddi) oil on cutaneous wound healing in rats. *Acta Cirurgica Brasileira*, 28(3): 202-209.
- Falzon, C.C. and Balabanova, A. 2017. Phytotherapy: An introduction to herbal medicine. *Primary Care: Clinics in Office Practice*, 44(2): 217-227.

- Farahpour, M.R., Vahid, M. and Oryan, A. 2018. Effectiveness of topical application of ostrich oil on the healing of *Staphylococcus aureus* and *Pseudomonas aeruginosa*-infected wounds. *Connective Tissue Research*, 59(3): 212-222.
- Gallagher, A., Flatt, P., Duffy, G. and Abdel-Wahab, Y. 2003. The effects of traditional antidiabetic plants on in vitro glucose diffusion. *Nutrition research*, 23(3): 413-424.
- Georgiev, V., Ananga, A. and Tsoleva, V. 2014. Recent advances and uses of grape flavonoids as nutraceuticals. *Nutrients*, 6(1): 391-415.
- Ghashghaii, A., Hashemnia, M., Nikousefat, Z., Zangeneh, M.M. and Zangeneh, A. 2017. Wound healing potential of methanolic extract of *Scrophularia striata* in rats. *Pharmaceutical Sciences*, 23(4): 256-263.
- Hashemnia, M., Javdani, M., Nikousefat, Z., Hoseinpour, F. and Kakaei, S. 2014. Evaluation of the wound healing activity of methanolic extract of *Tragopogon porrifolius* in rat. *Research Opinions in Animal and Veterinary Sciences*, 4(8): 446-452.
- Hosseini, N., Akbari, M., Ghafarzadegan, R., Changizi Ashtiyani, S. and Shahmohammadi, R. 2012. Total phenol, antioxidant and antibacterial activity of the essential oil and extracts of *Ferulago angulata* ssp. *angulata*. *Journal of Medicinal Plants*, 43(3): 80-89.
- Kasuya, A. and Tokura, Y. 2014. Attempts to accelerate wound healing. *Journal of Dermatological Science*, 76(3): 169-172.
- Keller, E.C. and Tomecki, K.J. 2011. Cutaneous infections and infestations: new therapies. *The Journal of Clinical and Aesthetic Dermatology*, 4(12): 18-24.
- Khémiri, I., Essghaier Hedi, B., Sadfi Zouaoui, N., Ben Gdara, N. and Bitri, L. 2019. The antimicrobial and wound healing potential of *Opuntia ficus indica* L. *inermis* extracted oil from Tunisia. *Evidence-Based Complementary and Alternative Medicine*, 2019: 1-10.
- Labib, R.M., Ayoub, I.M., Michel, H.E., Mehanny, M., Kamil, V., Hany, M. and Mohamed, A. 2019. Appraisal on the wound healing potential of *Melaleuca alternifolia* and *Rosmarinus officinalis* L. essential oil-loaded chitosan topical preparations. *PLoS one*, 14(9): e0219561.
- Manzuoerh, R., Farahpour, M.R., Oryan, A. and Sonboli, A. 2019. Effectiveness of topical administration of *Anethum graveolens* essential oil on MRSA-infected wounds. *Biomedicine & Pharmacotherapy*, 109: 1650-1658.
- Mori, H.-M., Kawanami, H., Kawahata, H. and Aoki, M. 2016. Wound healing potential of lavender oil by acceleration of granulation and wound contraction through induction of TGF- β in a rat model. *BMC Complementary and Alternative Medicine*, 16(1): 144-149.
- Nayak, B., Raju, S. and Chalapathi Rao, A. 2008. Wound healing activity of *Persea americana* (avocado) fruit: a preclinical study on rats. *Journal of Wound Care*, 17(3): 123-125.
- Nejati, H., Farahpour, M.R. and Nagadehi, M.N. 2015. Topical *Rosemary officinalis* essential oil improves wound healing against disseminated *Candida albicans* infection in rat model. *Comparative Clinical Pathology*, 24(6): 1377-1383.
- Oryan, A., Naeini, A.T., Moshiri, A., Mohammadalipour, A. and Tabandeh, M. 2012. Modulation of cutaneous wound healing by silymarin in rats. *Journal of Wound Care*, 21(9): 457-464.
- Penna, S., Medeiros, M., Aimbire, F., Faria-Neto, H., Sertie, J. and Lopes-Martins, R. 2003. Anti-inflammatory effect of the hydroalcoholic extract of *Zingiber officinale* rhizomes on rat paw and skin edema. *Phytomedicine*, 10(5): 381-385.
- Pessoa, W.S., Estevão, L.R.d.M., Simões, R.S., Barros, M.E.G.D., Mendonça, F.D.S., Baratella-Evêncio, L. and Evencio-Neto, J. 2012. Effects of angico extract (*Anadenanthera colubrina* var. *cebil*) in cutaneous wound healing in rats. *Acta Cirurgica Brasileira*, 27(10): 655-670.
- Riyazzudin, M., Sharma, M., Kaur, G. and Chaudhry, N. 2016. A review on therapeutic potential of plant derived natural compounds. *Bio-Chemiae Acta*, 1(1): 30-34.
- Ruppen, C., Notter, J., Strahm, C., Sonderegger, B. and Sendi, P. 2018. Osteoarticular and skin and soft-tissue infections caused by *Streptococcus agalactiae* in elderly patients are frequently associated with bacteremia. *Diagnostic Microbiology and Infectious Disease*, 90(1): 55-57.
- Takzaree, A., Goodarzi, M. and Shahbabae, S. 2020. Investigating histopathologic the synergistic effect of topical use of *Mentha pulegium* essential oil and honey in healing of cutaneous ulcers. *Journal of Medicinal Plants*, 4(72): 274-287.
- Valizadeh, Z. and Rafieirad, M. 2016. Effects of hydro-alcoholic leaf extract of Kardeh (*Biarum Bovei*

Blume) on the blood glucose and lipid peroxidation in cerebral tissues and lipid profile in Streptozotocin induced diabetic rats. *Iranian Journal of Diabetes and Obesity*, 8(1): 16-23.

Wikaningtyas, P. and Sukandar, E.Y. 2016. The antibacterial activity of selected plants towards resistant bacteria isolated from clinical specimens. *Asian Pacific Journal of Tropical Biomedicine*, 6(1): 16-19.

Williams, C.A., Harborne, J.B. and Mayo, S.J. 1981. Anthocyanin pigments and leaf flavonoids in the family Araceae. *Phytochemistry*, 20(2): 217-234.