



## ORIGINAL ARTICLE

## Histological and Biochemical Evaluation of Rat Liver and Kidney Following Nitrofurantoin Administration

Omewomano Peace Onyilo, Efe Endurance Ahama\*, Ehizokhale Santos Ehebha, Chikodili Judith Okoro, Oghenenyehovwo Success Okorodudu

Department of Human Anatomy and Cell Biology, Faculty of Basic Medical Sciences, Delta State University, Abraka, Nigeria

(Received: 25 January 2024

Accepted: 7 July 2024)

## KEYWORDS

Nitrofurantoin;  
Liver;  
Kidney;  
Rat

**ABSTRACT:** Nitrofurantoin (NFR) is an antibiotic commonly used in the management of uncomplicated urinary tract infections. The study examined histoarchitectural and biochemical alterations in the liver and kidney of Wistar rats following exposure to nitrofurantoin. Fifteen (15) adult Wistar rats comprising five (5) animals per group were randomly assigned into three groups. Group A was the control group while Groups B and C received 30mg kg<sup>-1</sup> and 60mg kg<sup>-1</sup> body weight of NFR respectively for thirty (30) days. Data generated from liver and renal functional markers was analyzed on graph pad prism using descriptive statistics and outcomes implicated as standard error of the mean and mean. Mean value differences were evaluated using analysis of variance (ANOVA) considering p<0.05 as statistically significant value. Upshot display periportal hepatitis in the group given 30mg kg<sup>-1</sup> of nitrofurantoin, the hepatocytes appeared polygonal and there was vascular congestion with inflammatory cell infiltration in rats given 60mg kg<sup>-1</sup> NFR. These features were consistent with inflammatory responses. However, liver function tests showed a significant increase in Alanine transaminase (ALT), Aspartate aminotransferase (AST), and Alkaline phosphatase (ALP) levels across treated groups when rationalized to control group (p<0.05). Also observed is a statistically significant increase in mean serum level of total protein, direct and indirect Bilirubin across treatment groups compared to control. More so, there were features consistent with normal renal histoarchitecture with tubules comprising of multiple segments and corpuscle made up of the Glomerulus surrounded by the podocytes. Conversely, renal function parameters showed a decrease in the urea level across treatment groups. Nitrofurantoin displays no histoarchitectural outcome of the kidney but elucidated negative outcome on the liver histology, therefore caution should be considered when administered as a therapeutic agent.

## INTRODUCTION

Nitrofurantoin (NFR) is an active antibacterial drug applied in the treatment of acute urinary tract infections (UTI) or as a single-use postcoital pill [1]. It has gained wide prescription over two decades even up till now, however, because of the use of another supplemental drug, other supplemental drugs which have been observed to replace its therapeutic function [2]. NFR is a

well-recommended prophylaxis for aged patients with UTIs, though it is absorbed quickly from the gut there is shreds of evidence of adverse effects in the gastrointestinal tract and liver in animal models. Long-term use of nitrofurantoin has been associated with chronic and acute hepatic failure, more so, the elevated blood concentration of NFR has reportedly caused

\*Corresponding author: efeahama@gmail.com (E. Endurance Ahama)  
DOI: 10.60829/jchr.2024.1956

axonal neuropathy with features of paresthesia [1, 3, 4]. Nitrofurantoin was seen to exert an inhibitory effect on spermatogenesis but has no negative effect on steroidogenesis [5]. Pulmonary hypersensitivity reaction (PHR), fibrosis and hepatotoxicity follow prolonged usage of NFR which may result in significant lung and liver swelling and inflammation [1]. Antimicrobial nitrofurantoin is rarely implicated in hepatitis (autoimmune), which is a common initiator of liver failure [6]. In a study by [7] which examined NFR upshot on the lungs of rats, outcome display ruptured interalveolar septa, which is thickened, with associated inflammatory cellular infiltration, and regeneration of many emphysematous air pockets. Blood extravasations, blood clots, and fluid exudates were all present as well as an increase in the number of lung macrophages. Some studies have revealed that nitrofurantoin has several adverse effects on the body, notably with hepatic reactions such as hepatitis hepatic necrosis and cholestatic jaundice [8 - 12].

The kidney primarily maintains homeostasis of extracellular fluid volume in the mammalian system, and this is believed to be powered by the nephron, which conducts several drug pharmacokinetics [13]. Intake of certain substances and multiple drugs, can affect the kidneys basically on the same site (causing acute tubular necrosis), which may lead to renal dysfunctionality in adults. Nephrotoxic drugs possess dose-dependent outcomes and may cause idiosyncratic renal deterioration [13]. There was a report of acute renal dysfunction observed following the administration of NFR, which assesses a remarkable association of NFR-related acute granulomatous interstitial nephritis which bring about acute renal failure and renal deterioration with tubular function defects, and in previous times before now, it has only been reported once to the best of their knowledge [14].

Despite previous treatise on the deleterious outcomes of NFR on the liver and kidney, its use as a therapeutic agent especially for prophylaxis for UTI and as a post-coital pill for women is rampant; however, no report has also elucidated its single use on the liver and kidney assessing its histoarchitectural and biochemical upshot. Furthermore, extensive critical literature assessing NFR on the liver and kidney histoarchitecture and biochemical

property is observed to be scanty and has created an existing knowledge gap. This study therefore evaluates the histoarchitectural and biochemical evaluation of rat kidney and liver following nitrofurantoin administration.

## MATERIALS AND METHODS

### *Experimental animals and Grouping*

The study comprised fifteen (15) adult Wistar rats weighing 150-200g, were procured from the Animal House of the College of Health Sciences, Delta State University, Abraka. The animals were kept in a plastic cage and allowed to acclimatize under favorable conditions. Animals were accommodated in well-ventilated space under a controlled environment with relative humidity ( $50\pm 5^\circ\text{C}$ ), temperature ( $25\pm 5^\circ\text{C}$ ), and a 12-hour light/dark cycle. They were fed daily with standard grower's mash (feed) and were given access to water. Thereafter, a daily dose of Nitrofurantoin was administered to them, and were weighed weekly for 30 days. The rats were handled according to etiquette authenticated by the institutional animal ethics committee (IAEC) as espoused by the Faculty of Basic Medical Sciences, Delta State University, Abraka, Nigeria. The animals were weighed and categorized into groups A, B, and C consisting of 5 adult Wistar rats each. Group A served as control group while groups B and C were the treated groups. Group B and C received  $30\text{mg kg}^{-1}$  and  $60\text{mg kg}^{-1}$  per body weight NFR.

### *Sample Collection*

Termination of the treatment period, Wistar rats were euthanized using cervical dislocation. Samples of blood were collected from the inferior vena cava and centrifuged at 4000rpm and used for assessment of liver and renal function parameters. Harvested liver and kidneys were fixed in 10% formal saline and processed following standard histological protocol as prescribed by [15].

### *Photomicrography*

Processed tissue slides were captured using Digital Zeiss Primo Star Microscope with focusing Eyepiece WF 10x/20, 8.0 megapixel (HD) connected to a computer via

USB-C 2.0 [16, 17].

### **Biochemical analysis**

Blood samples were obtained from inferior vena cava kept in a well-labeled tubes containing Lithium heparin anticoagulant. The blood sample was centrifuged for 10 minutes at 300rpm [18]. Using an automated analyzer, the collected plasma was used to assay the liver and renal function test

### **Statistical analysis**

Data from the renal function test was analyzed using a graph pad prism and report expressed as standard error of the mean and the mean. Differences in mean value were assessed using analysis of variance (ANOVA) and considering  $p \leq 0.05$  to be statistically significant.

## **RESULTS**

### ***Effects of nitrofurantoin on the liver function of adult wistar rat***

The graph shows a comparison of the mean serum level of Liver function parameters in adult rats treated with Nitrofurantoin at graded doses of  $30\text{mg kg}^{-1}$  and  $60\text{mg kg}^{-1}$  per body weight NFR. Results showed a remarkable increase ( $p < 0.05$ ) in Alanine transaminase (ALT), Aspartate aminotransferase (AST), and Alkaline phosphatase (ALP) levels across treatment groups when compared to control. Multiple comparisons between groups using the least square difference displayed statistically significant increase ( $p < 0.05$ ) in the mean serum ALP and AST levels at  $60\text{mg kg}^{-1}$  compared to the control. More so, mean serum ALT level remarkably increased in all treatment groups juxtapose to control

(Figure 1). Also observed is a statistically remarkable increase ( $p < 0.05$ ) in the mean serum level of total protein, Direct Bilirubin, and Indirect Bilirubin across treatment groups compared to the control (Figure 2). Multiple comparisons between groups using least square difference showed a statistically remarkable dose-dependent increase ( $p < 0.05$ ) in the total protein (Figure 3) and Direct bilirubin at  $60\text{mg kg}^{-1}$  body weight of NFR compared to the control. However indirect bilirubin the level significantly increased in all treatment groups juxtaposed to control.

### ***Effects of nitrofurantoin on the renal function of adult wistar rat***

Finding display remarkable decrease ( $p < 0.05$ ) in urea level more evident at high doses when compared to the control. Multiple comparisons between groups using least square difference display a statistically remarkable decrease ( $p < 0.05$ ) in the mean serum urea level at high dose compared to the control, however in the low dose group no significant change was observed (Figure 4).

There was no remarkable change ( $p > 0.05$ ) in mean serum creatinine and some electrolytes (sodium and potassium) levels across treatment groups juxtaposed to control. However, the mean serum level of chlorine remarkably increased ( $p < 0.05$ ) across treatment groups when juxtaposed to control (Figure 5). Multiple comparisons between groups using least square difference showed a statistically remarkable increase in the mean serum chlorine level in low dose groups ( $p < 0.05$ ), and more evident in high dose group ( $p < 0.05$ ) juxtaposed to control. The significant changes in serum levels of urea and chlorine observed at high doses indicate a dose-dependent response in renal parameters.

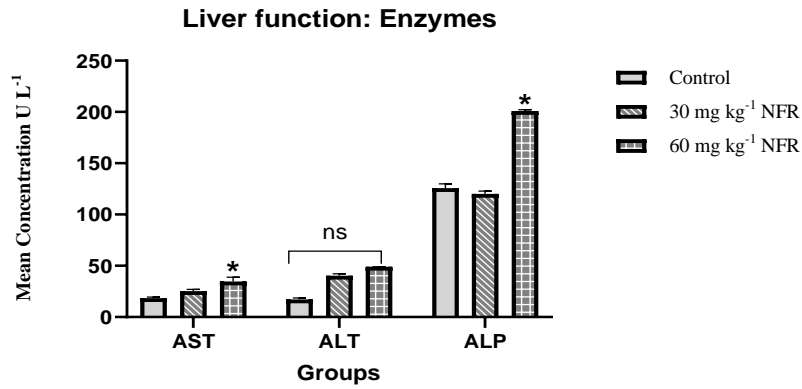


Figure 1. Effects of NFR on Liver Enzymes: AST, ALT & ALP.

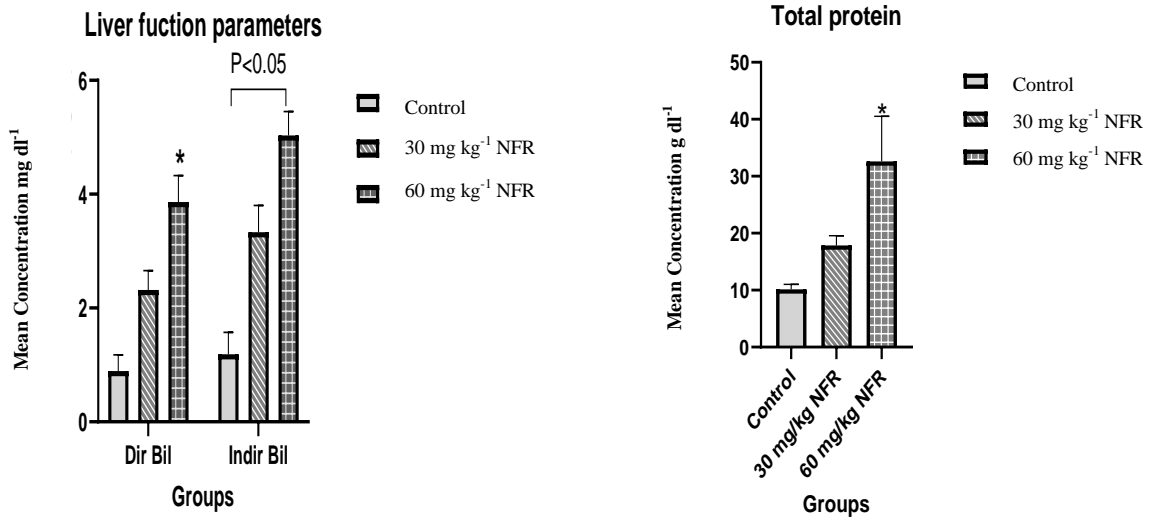


Figure 2. Effects of NFR on Dir. & Indir. Bilirubin

Figure 3. Effects of NFR on Total Protein

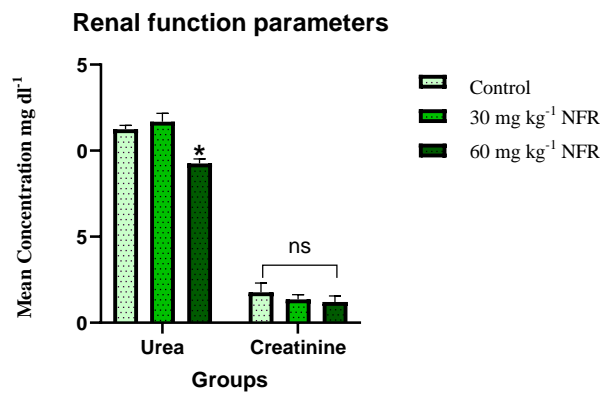
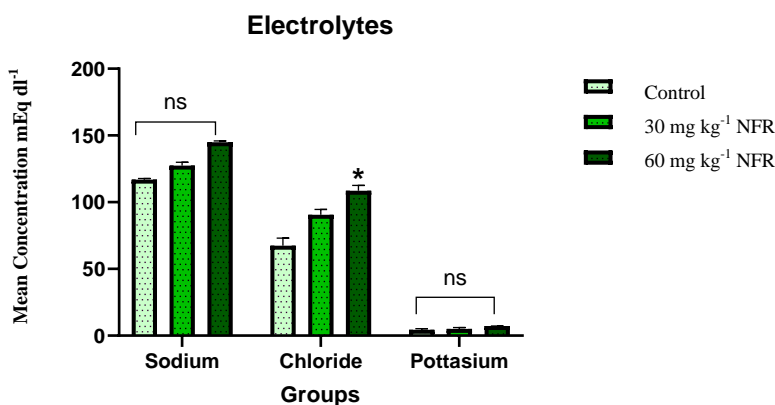


Figure 4. Effects of NFR on Renal function parameters: Urea & Creatinine.



**Figure 5.** Effects of NFR on Electrolyte concentration: Sodium, chloride & potassium. Values are presented as mean  $\pm$  SEM for each group;  $n=5/\text{group}$ , \*  $p<0.05$  indicates a significant difference compared to the control. \*ns represent no significant change

#### *Effect of nitrofurantoin on the liver histology of adult wistar rat*

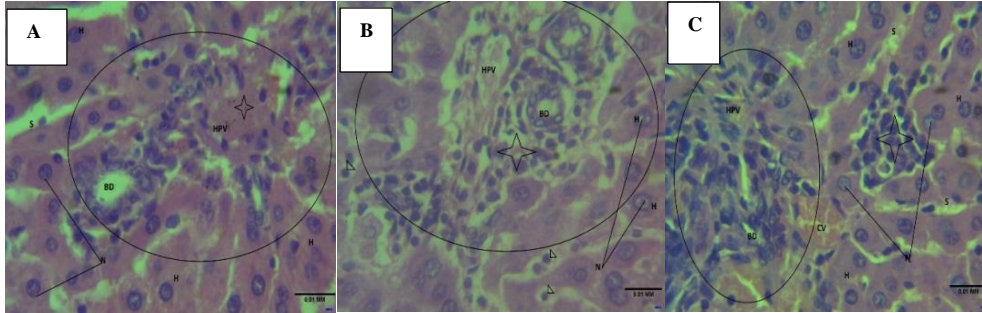
Microanatomy section of animals in the control group display hepatocytes (H) disposed in polygonal sheet with definite nucleus (N), round to oval in shape posited in a cytoplasm. Cells within polygonal sheets are separated by the sinusoids (S) with tiny endothelial lining. Observed is a portal region (Circle) comprises of branches of the hepatic portal vessels (HPV), and bile duct (BD) which reveal normal histoarchitecture.

Low dose group given  $30\text{mg kg}^{-1}$  of nitrofurantoin also reveal hepatocytes (H) dispersed in a polygonal sheet with a poorly-outlined vesicular nucleus (N) appearing seldom round to oval shape. Cells are poorly separated by the sinusoids (S) in the sheet by tiny endothelial border and contain activated Kupffer cells (arrowhead). Portal region (Circle) comprises of branches of hepatic portal vessels (HPV), and bile duct (BD). Micro anatomic section reveals periportal hepatitis (Star). However, high dose group given  $60\text{mg kg}^{-1}$  of nitrofurantoin reveal similar histo and cytoarchitectural benchmark but display vascular congestion (CV) and inflammatory cell infiltration (star). Features consistent with inflammatory responses. (Figure 6)

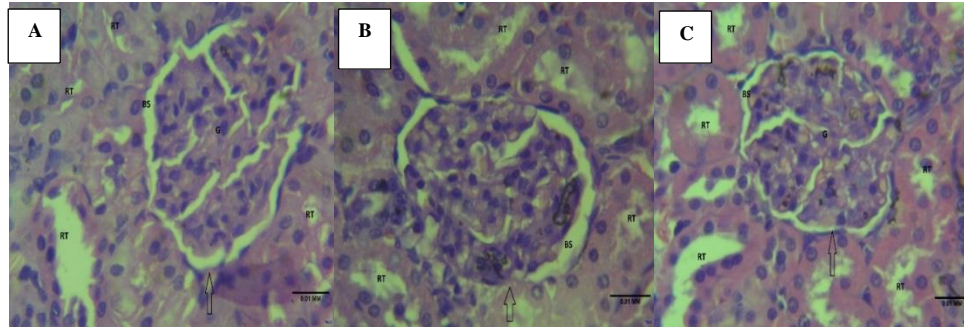
#### *Effects of nitrofurantoin on the kidney histology of adult wistar rat*

Renal tissue (Group A) display renal corpuscle (arrow) and tubules made up of multiple fragments. Corpuscle comprises of glomerulus (G) surrounded by podocytes and are dispersed by a definite Bowman's capsule space (BCS). Renal tubules, RT are lined by cuboidal epithelium with proximal portion of it revealing dense packed microvilli conformed into a brush border. Renal micro anatomic sections appear normal and unremarkable.

Renal histology for low dose group reveals corpuscle (arrow) and tubules which comprises of multiple portions. Corpuscles composed of glomeruli (G) surrounded by the podocytes and partitioned by a definite Bowman's capsule space (BCS). Tubules are lined by simple cuboidal epithelium proximal portion of it displaying dense packed microvilli conformed into a brush border. Renal section appears normal with unremarkable features. However, high dose group treated with  $60\text{mg kg}^{-1}$  of NFR reveal similar histo and cytoarchitectural as that of low dose group. Microanatomy sections appear normal with unremarkable features. (Figure 7)



**Figure 6.** Photomicrograph of Rat Liver in control (A) and treated groups (B & C) given NFR at 30mg kg<sup>-1</sup> and 60mg kg<sup>-1</sup> respectively.



**Figure 7.** Photomicrograph of Rat Kidneys in control (A) and treated groups (B & C) given NFR at 30mg kg<sup>-1</sup> and 60mg kg<sup>-1</sup> respectively.

## DISCUSSION

Nitrofurantoin use is thought to have displayed toxic effects, with none assessing the histoarchitectural and biochemical evaluation of kidney and liver of adult Wistar rats. The index study therefore examined the upshot of nitrofurantoin on the kidney and liver of adult Wistar rats. Findings from the index study assessing animals with low dose (30mg kg<sup>-1</sup>) administration depict hepatocytes posited in polygonal hepatic sheet with a well-defined nucleus. However, there was periportal hepatitis. The finding was supported by that of [19] who reported that low and high doses of NFR resulted in interface hepatitis, portal and periportal lymphoplasmacytic and eosinophilic infiltration except for advanced fibrosis and cirrhosis. Following administration of NFR at a high dose of 60mg kg<sup>-1</sup>, depict hepatocytes appearing round to oval with vesicular nuclei disposed of in a polygonal hepatic sheet. Seen also are vascular congestion and inflammatory cell infiltration, representing features of consistent inflammatory response. Observed cyto-architectural hepatic distortion may be associated with functional changes that may have been detrimental, which is observed to display a significant increase in Alanine transaminase (ALT), Aspartate aminotransferase (AST), and Alkaline

phosphatase (ALP) levels across treated groups. Also seen is a significant increase in mean serum level of total protein, direct and indirect bilirubin across treated groups Juxtaposed with control group ( $p < 0.05$  respectively). Findings observed were slightly similar to that of [11] where NFR-induced liver injury displaying broad phenotypic range, spanning from transient increases in icteric hepatitis, acute liver failure, and even death, with a frequent biochemical pattern, displaying an hepatocellular presentation. The outcome of NFR was further explicated in a 42 years old Caucasian woman with an elevated alanine transaminase concentration of 469 U/L (10-35), however, biochemistry of the liver improved rapidly after several weeks of corticosteroid medication and NFR termination [6]. Similarly, these findings were obtainable in a [20] study in 2015 where an aged patient had a liver injury due to therapeutic use of NFR, however upon withdrawal of NFR liver failure tends to subside. Therefore NFR administration resulted in cellular reaction to injury in the liver of treated rats, as postulated in the previous treatise.

Unanimously graded doses of the drug administered at 30mg kg<sup>-1</sup> and 60mg kg<sup>-1</sup> NFR displayed no histoarchitectural distortion to the kidney of the treated

rats, with all cytoarchitecture remaining intact. However, renal function outcomes reveal a general decrease in creatinine and urea levels, with a specific linear decrease in creatinine and urea levels evident with the group receiving high dose, however at the low dose group, there is no linear decrease in urea and creatinine level. Also, there was no remarkable change in mean serum creatinine and some electrolytes (sodium and potassium) levels across treatment groups. However, the mean serum level of chlorine significantly increased across treated groups when juxtaposed to control group, although the increase was more evident in the high-dose group than the low-dose group. This is similar to a [14] study in 2010 where a rare association of NFR-related acute granulomatous interstitial nephritis bring about acute renal dysfunctionality, but upon withdrawal of NFR, renal physiology was improved without corticosteroids required.

### CONCLUSIONS

This study underscored the deleterious outcomes in liver and kidney exposed to NFR with graded doses depicting microscopic or cytoarchitectural changes, therefore caution should be considered when used as a therapeutic agent.

### ACKNOWLEDGEMENTS

Authors would like to thank the Faculty of Basic Medical Science of Delta State University for granting the permission to conduct this research and also thank every reviewer for their good work.

### ETHICAL CONSIDERATION

Ethical permission was obtained from the Department of Human Anatomy and Cell Biology, Faculty of Basic Medical Sciences, College of Health Sciences, Delta State University with Ethical number DELSU/CHS/ANA/2022/27.

### Conflict of interests

The authors declare no conflict of interest.

### REFERENCES

1. Ortega Martell J.A., Naber K.G., Milhem Haddad J., 2019. Prevention of recurrent urinary tract infections: bridging the gap between clinical practice and guidelines in Latin America. *Ther Adv Urol.* 11, 1756287218824089.
2. Huttner A., Verhaegh E.M., Harbarth S., 2015. Nitrofurantoin revisited: a systematic review and meta-analysis of controlled trials. *J Antimicrob Chemother.* 70, 2456 - 2464.
3. Luk T., Edwards B.D., Bates D., Evernden C., Edwards J., 2021. Nitrofurantoin-induced liver failure: a fatal yet forgotten complication. *Can Fam Phy.* 67, 342-344
4. Wonnacott S., Gala D., Shah M., Kaul D., Kumar V., 2022. An Unusual Case of Drug-Induced Liver Injury Secondary to Nitrofurantoin Use. *Cureus.* 14(7), e26882. Doi: 10.7759/cureus.26882
5. Abaas N.F., Haba M.K., 2015. Histopathological changes caused by the chronic effect of nitrofurantoin drug in the testes of albino mice. *Bagh Sci J.* 12(1), 20 - 26.
6. Appleyard S., Saraswati R., Gorard D.A., 2010. Autoimmune hepatitis triggered by nitrofurantoin: a case series. *J Med Cas Rep.* 4, 1 - 5.
7. Rizk A., 2011. Effect of Nitrofurantoin on the Lungs of Adult Albino Rat and the Possible Protective Role of Vitamin E. <https://scholar.cu.edu.eg/?q=aymanrizk/publications/effect-nitrofurantoin-lungs-adult-albino-rat-and-possible-protective-role-vit>.
8. Chalasani N., Bonkovsky H.L., Fontana R., 2015. Features and outcomes of 899 patients with drug-induced liver injury: the DILIN prospective study. *Gastroentero.* 148, 1340-1352.e7
9. Muller A.E., Verhaegh E.M., Harbarth S., 2017. Nitrofurantoin's efficacy and safety as prophylaxis for urinary tract infections: a systematic review of the literature and meta-analysis of controlled trials. *Clin Microbiol Infect.* 23, 355 - 362
10. de Boer Y.S., Kosinski A.S., Urban T.J., 2017. Features of autoimmune hepatitis in patients with drug-induced liver injury. *Clin Gastroenterol Hepatol.* 15, 103-112.e2. <https://doi.org/10.1016/j.cgh.2016.05.043>.
11. Bjornsson E.S., 2017. Drug-induced liver injury due

to antibiotics. *Scand.JGastroenterol.* 52, 617 - 623.

12. Bessone F., Ferrari A., Hernandez N., Mendizabal M., Ridruejo E., Zerega A., Tanno F., Reggiardo M.V., Vorobioff J., Tanno H., Arrese M., Nunes V., Tagle M., Medina Caliz I., Robles Diaz M., Niu H., AlvarezAlvarez I., Stephens C., Lucena M.I., Andrade R.J., 2023. Nitrofurantoin induced liver injury: long term follow up in two prospective DILI registries. *Arch Toxicol.* 97, 593 - 602

13. Naidoo S., Meyers A.M., 2015. Drug and Kidney. *SoutAfr Med J.* 105(4), 322.

14. Namagondlu G., Low S.E., Seneviratne R., Banerjee A., 2010. Acute renal failure from nitrofurantoin-induced acute granulomatous interstitial nephritis. *QJM: Int J M.* 103(1), 49 - 52.

15. Ahama E.E., Igben V.O., Ubogu J., Osakue I.I., Nwabuoku U.S., Okwuribo P., Kpangban A., Odokuma E.I., 2023. Potential Nephrotoxic Sequel of the Kidney Following Exposure to Turmeric Extract in Adult Wistar Rats. *J Col Med Sci Nep.* 19(4), 482 - 488; DOI:10.3126/jcmsn.v19i4.48718

16. Ahama E.E., Odokuma E.I., 2023. Histomorphological Effects of Oral Nicotine administration on the testes of adult wistar rats. *Journal of Chemical Health Risks.* 13(2), 291 - 298. DOI: 10.22034/jchr.2022.1949064.1488

17. Ahama E.E., Odokuma E.I., Ehebha E.S., Enakpoya O.P., 2024. Histological Sequel Following Exposure to Levonorgestrel on Wistar Rat Ovary. *Journal of Chemical Health Risks.* 14(1), 71-86.

18. Callaghna E., 2020. Bilirubin. Retrieved from: <https://www.randox.com/tag/liver-function-tests/> (accessed 14 August, 2022).

19. Mack C.L., Adams D., Assis D.N., 2020. Diagnosis and management of autoimmune hepatitis in adults and children: 2019 practice guidance and guidelines from the American Association for the Study of Liver Diseases. *Hepato.* 72, 671 – 722.

20. McCracken D., 2015. Nitrofurantoin Induced Liver Injury. *JSM Gastroenterol Hepato.* 3(1), 1040.