



Case Report

Occurrence of progressive and corrosive lesions in perineal area of a Kurd stallion due to *oxyuris equi*

Mohamad Tolouei ^{1*}, Seyed Abdolhamid Hosseini ², Saeid Mostofi ³

¹Department of clinical sciences, Faculty of Veterinary Medicine, University of Tabriz, Tabriz, Iran

²Faculty of Veterinary Medicine, University of Tabriz, Tabriz, Iran

³Laboratory staff, Veterinary Office of East Azerbaijan Province, Tabriz, Iran

ARTICLE INFO	ABSTRACT
Received: 25 December 2019	In Autumn of 2018 a Kurd stallion with symptoms of itching and some deep and corrosive lesions in above of perineal region and around anus was examined at one of equestrian clubs of Tabriz province. Vital signs of animal were normal. The wounds had spread around the rectum and below the tail, a big corrosive and progressive lesion had developed. After collecting feces samples and parasitological test, eggs and even larvae of <i>Oxyuris equi</i> were observed. According to the clinical and parasitological examinations, involvement of Oxyuriasis was considered. Treatment of the disease started with anti-parasitic drugs such as Pyrantel, Oxybendazole and Ivermectin, although the lesions were disinfected with iodide solution, vitamin A+D ointment and Tetracycline. The lesions were 90% recovered by 20 days after treatment. As in the report, Oxyuriasis can be seen unusual form as corrosive and progressive lesions in perineal region in even adult horses.
Accepted: 6 February 2020	
KEYWORDS:	
<i>Oxyuris equi</i>	
Parasitic infestation	
Horse	
Corrosive wound	

وقوع ضایعات خورنده و پیشرونده ناحیه پرینه یک راس اسب نر نژاد کرد با انگل اکسیوریس اکوئی (*Oxyuris equi*) در

اطراف شهرستان تبریز

محمد طلوعی^{۱*}، سید عبدالحمید حسینی^۲، سعید مستوفی^۳

^۱گروه علوم درمانگاهی، دانشکده دامپزشکی، دانشگاه تبریز، تبریز، ایران

^۲دانشکده دامپزشکی، دانشگاه تبریز، تبریز، ایران

^۳کارشناس آزمایشگاه اداره کل دامپزشکی استان آذربایجان شرقی، تبریز، ایران

چکیده

در پائیز سال ۱۳۹۷ یک راس اسب نر با نشانه‌های خارش و تظاهر برخی ضایعات در نواحی اطراف مقعد در یکی از اسب‌داری‌های شهر تبریز مورد معاینه قرار گرفت. نشانه‌های حیاتی دام طبیعی بودند. زخم‌های مذکور در ناحیه بالای پرینه و زیر دم منتشر شده و یک زخم بزرگ پیشرونده و خورنده تشکیل شده بود. پس از جمع‌آوری نمونه‌های مدفوع و آزمایش‌های انگل‌شناسی تخم‌ها و حتی لارو انگل اکسیوریس/اکوئی مورد مشاهده قرار گرفت. بر اساس مشاهدات بالینی و آزمایش‌های انگل‌شناسی درگیری به بیماری اکسیوریازیس مورد تأیید قرار گرفت. درمان بیماری با تجویز داروهای ضدانگلی پیرانتل، اکسی بندازول و آیورمکتین شروع شد و همچنین ضد عفونی نواحی درگیر بوسیله محلول‌های ید دار، پماد تتراسایکلین و پماد ویتامین آ و د انجام گردید. ضایعات مذکور در عرض ۲۰ روز پس از درمان بیش از ۹۰ درصد بهبود یافته بودند. براساس این گزارش بیماری اکسیوریازیس می‌تواند در شکل غیرمعمول به صورت زخم عمیق خورنده و پیشرونده در ناحیه بالای پرینه حتی در اسب‌های بالغ ایجاد گردد.

واژه های کلیدی: اکسیوریس اکوئی، آلودگی انگلی، اسب، زخم خورنده

* Corresponding author's email: Toloui_m@yahoo.com

©2019 Islamic Azad University, Urmia Branch.

This work is licensed under a [Creative Commons Attribution 4.0 International License](https://creativecommons.org/licenses/by/4.0/).



INTRODUCTION

Parasitic infestations are one of the major worldwide problems in horses breeding. Despite the presence of about 600000 working and 400000 riding horses in Iran, there have been few studies on the infestations of horses with different types of gastrointestinal Nematodes (GINs) [1]. Gastrointestinal nematodes occur ubiquitously in horses (*Equus caballus*) and present a major veterinary concern throughout the world. Strongylid (family *Strongylidae*) nematodes such as *strongylins* (large *strongyles*) and cyathostomins (small *strongyles*) are the main internal nematode parasites of horses constituting more than 75% of the total parasite fauna [2,3]. Non-strongylid GINs found in horses include *Parascaris*, *Equorum*, *Habronema* spp., *Draschia megastoma*, *Oxyuris equi*, *Trichostrongylus axei* and *Strongyloides westeri* [4]. The equine pinworm *Oxyuris equi* is common horse parasite with worldwide distribution [3, 5, 6]. In a past, research on equine Nematodes has mainly been focused on member of the superfamily *Strongyloidea*, especially *cyathostomes*, since resistance of these parasites against anthelmintic represent a global problem [7]. *Oxyuris equi* follows a direct life cycle, with the adults inhabiting mainly the right dorsal colon and, in cases of heavy infections, also the adjoining parts of the colon of equines. After mating, adult females migrate to the anus to deposit eggs in sticky clumps (8,000 to 60,000 eggs/female) which seen grossly as yellowish white gelatinous streaks on the skin of the perianal region. Within four to five days, the egg contains an infective third-stage (L3) larva. The eggs are rubbed off, contaminate the environment and horses become infected by ingestion of eggs on forage, grass and bedding. The eggs hatch and the L3 larvae invade the crypts in the ventral colon and caecum. Within 3 to 11 days, development into fourth-stage (L4) larvae takes place and the L4 larvae move slowly towards the dorsal colon. From day 50, post-infection molting into fifth-stage (L5) larvae begins and it will take another 100 days to reach sexual maturity [8].

Larval pinworms attach to the mucosa of the cecum and ventral colon, where their plug-feeding activities may cause superficial typhilitis or colitis. Adult pinworms apparently do not have any primary pathologic impact [9]. Infected horses routinely apply their posterior part of bodies to the walls to get rid of the burning and itching of female worms. This rubbing of the horse breaks the hairs as well as creating areas without hair. The horse's tail also gradually becomes rat-tailed. In addition to the mentioned symptoms, the restless animal also eats less food and physical conditions decrease. Adult horses appear to be less susceptible to this kind of infection as they are partially resistant to *Oxyriasis* but there are reports of infecting adult horses suggesting that the parasite develops in new way to contamination [10]. This study reports the occurrence of an unusual form of *Oxyuris equi* in an adult horse in Iran and the discussion of its different epidemiological, clinical and diagnostic aspects.

HISTORY AND CLINICAL FINDINGS

Autumn of 2018, a 3 years-old Kurd stallion was examined with signs of itching and wounds around anus and above perineum region at an equestrian club in Tabriz province. There was no significant information of the horse background except that the horse was previously grazing in the pasture and had no anti-parasitic prevention programs. In clinical examinations, the vital signs were normal (HR: 35bpm, RR: 20bpm, temperature: 37.9°C, CRT: 2.5seconds, mucous membranes: moist and pink) but showed restlessness and tried to rub his perineal region to the wall. There was one deep corrosive and progressive lesion around the rectum, above the perineal region and under the tail, which are believed to be due to the corrosion of adult worms. The tail of the animal was tangled up and the quality of the cover had decreased (Figure 1).

Parasitology tests

The feces were obtained from the rectum for parasitological examination and was sent to the parasitology laboratory. In the parasitology laboratory, fecal flotation test was performed with sodium nitrate. In parasitological tests,

the oval yellow one site flat with unipolar mucosal plague Eggs and even the larvae of the *Oxyuris equi* were observed (Figure 2).

Treatment procedure

Treatment of the disease started with anti-parasitic drugs *Pyrantel* 6.6mg/kg PO for 3 days then one dose after 15 days, *Oxybendazole* 15mg/kg PO for 3 days then one dose after 15 days, *Ivermectin* 0.2mg/kg PO for 3 days then one dose after 15 days, although the lesions were disinfected every 2 days with iodide solution, vitamin A+D ointment and Tetracycline. The lesions were 90% recovered by 20 days after treatment (Figure 3,4).

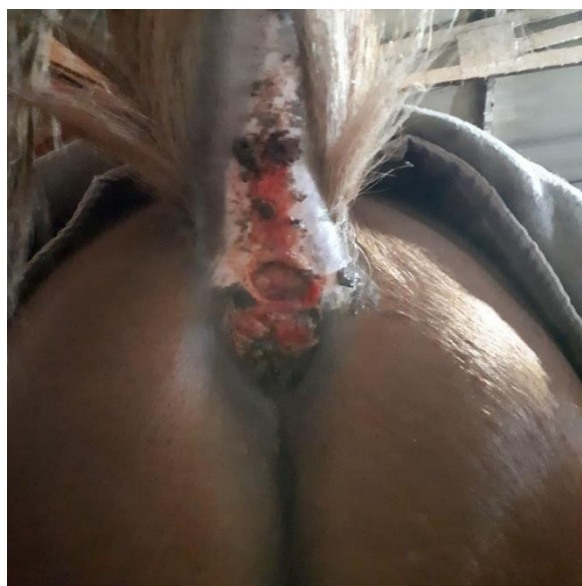


Figure1: Lesions in around rectum and under the tail.

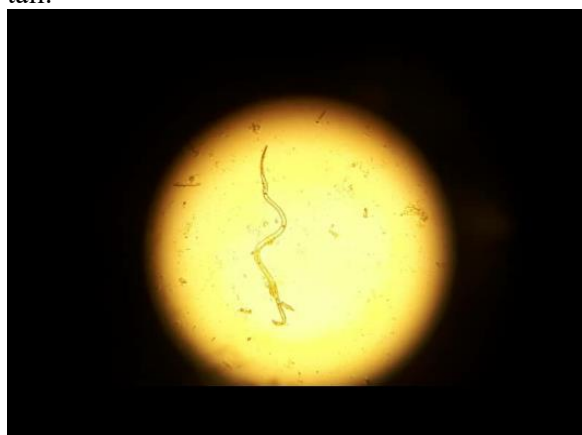

Figure2: *Oxyuris equi* adult worm (magnification $\times 40$).

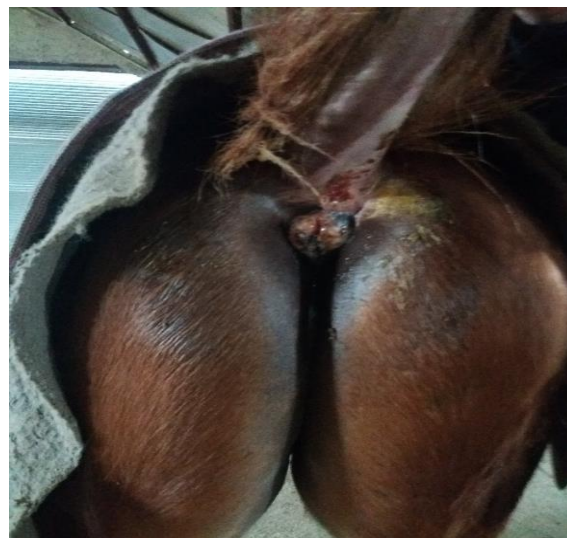


Figure 3,4: progress of treatment by 20 days after treatment.

DISCUSSION

In the livestock industry, parasitic diseases are one of the most harmful category of diseases that cause numerous damages to the animal. Horse breeding is no exception and parasitic diseases are also significant. Equines have important parasites such as *Strongyles* and *Parascaris equorum*. *Trichostrongylus axia*, *Hydatid cysts* and *Fasciola* are also important parasites of these animals [4]. *Oxyuris equi* inhabit the colon of domestic and wild equids worldwide and is often described as parasite of

low pathogenicity and thus a minor importance [11]. Pathogenic effect of *Oxyuris equi* in the intestine is due to the feeding of larvae (generally L₄) from the mucosal surface of the intestine, which can cause inflammation responses. In some reported cases of *Oxyuris equi*, poor body conditions, decreased animal performance and decreased cover quality have been noticed. Usually, owner complaints of back pruritus and itching due to the external excretions containing worms from anus and this pruritus could damage to tail and the skin of the perineum. The most important differential diagnosis is insect bite hypersensitivity (sweat itch) [8]. The pathogenic effects of *Oxyuris equi* is due to the feeding of worms on the mucosal crypts of the intestine. Due to the itching in the perineum and by rubbing the back of the animal with various objects, lesions outbreak in perineal region and adult worms have no direct effect on perineal ulceration [6,12]. Most important thing about this case was a great deep corrosive lesion around anus, which is not usually seen in the contamination with *Oxyuris equi*. Contrary to what is commonly thought about outbreaks of external lesions, it seems that these wounds are caused by the direct effect of corrosive nature of *oxyuris*. Due to the insufficient attention by the owner and prolonged infection, outbreaks of these types of lesions were possible. A flotation solution such as sucrose, sodium nitrate, sodium sulfate, sodium chloride, zinc sulfate, or magnesium sulfate provides a suitable specific gravity that helps to separate parasite eggs from fecal debris. Rather than single fecal samples, wider fecal sampling (both spatially and temporally) likely allows a better estimation of the distribution pattern of egg shedding but this is obviously difficult when evaluating an individual horse with suspected parasitic disease [13]. It is easy to diagnose *Oxyuris equi*. The clinical signs mentioned along with the observation of worm eggs in the feces confirms the diagnosis. Sometimes the owner mentioned that he had seen long-tailed white or cream worms in the feces of infected animal. Egg hatching location indicates that *Oxyuris* eggs are rarely found in

stool removed directly from the rectum. Egg should be sampled from intraperitoneal or fecal masses on the ground. The observation of the *Oxyurise* eggs confirms a definitive diagnosis. *Oxyuris* eggs are ovary, yellow, one side is slightly flat and have unipolar mucoidal plaque. Different techniques are used to collect feces samples. In the *cellophane tape* (scotch) technique, the sticky side of a small piece of adhesive tape is applied to the perianal area and then attached directly to a glass slide for microscopic examination. Diagnostic material can also be collected by scraping the perianal region with a tongue depressor dipped in mineral oil or lubricant and transferring the scrapings to a microscope slide for examination [9]. *Oxyuris equi* is sensitive to a numerous broad spectrum anti-parasitic drugs, including *Benzimidazole*, *Tetrahydropyrimidine* and macrocyclic lactones [14,15]. Anecdotal reports of treatment failures using *Ivermectin* and *Moxidectin* have been published [11,16,17]. As well as documented cases from the US and Germany, in which continuous shedding of *Oxyuris equi* eggs despite repeated treatments with either *Ivermectin* or/and *Moxidectin* compounds occurred, resulting in severe perianal pruritus as the main clinical finding [9,10]. Studies report *Pyrantel*, *Ivermectin* and *Moxidectin* are 91 per cent to 100 per cent effective against adult worms and 95 per cent to 99 per cent effective against the larval stages 2-4 [18,10]. Thus, traditionally, it has been thought pinworms are easily prevented by the anthelmintic protocols routinely employed for the control and prevention of large and small *strongyles* and *Cestodes* [8]. However, it must be acknowledged that testing the effect of these compounds on *Oxyuris equi* was a side effect rather than the main goal of many of the studies and that, in one study, small numbers of pinworms were found in three out of four horses after *Ivermectin* treatment and removal of L3 larvae was only 37 per cent [14]. The response to treatment in this case indicates that concomitant use of *Ivermectin* with other anti-parasitic drugs is more likely to succeed. Various treatment plans have been developed over the years,

most often based on herd treatment at fixed intervals. In fact, the main purpose of these therapies is to prevent or reduce the transmissions of the parasite, but most often it is done without sufficient attention to the life cycle of the parasites and its pathogenicity. According to the high importance of parasitic control in the horse industry, the need for greater use and efficiency of a comprehensive anti-parasitic program is becoming increasingly evident, which could prevent such damages. One of the most important point in prevention programs is using different drugs in prevention treatment courses, which in turns reduce drug resistance and increase program efficacy. In the use of anti-parasitic agents, it should be noted that the drug used should be repeated within next 15-21 days to completely eliminate all parasitic larvae and eggs in the body. As in the report, *Oxyuriasis* can be seen unusual form as corrosive and progressive lesions in perineal region in even adult horses.

ACKNOWLEDGMENTS

The authors want to acknowledge Mrs Shahbazi for her technical help in performing the parasite examination. They also want to acknowledge all staffs of Laboratory in the Veterinary Office of East Azerbaijan Province, Tabriz, Iran.

CONFLICT OF INTEREST

The authors have no conflict of interest to declare.

REFERENCES

- [1] VJ_Volume 11_Issue 1_Pages 130-131.pdf.
- [2] Bucknell D, Hoste H, Gasser RB, Beveridge I. The structure of the community of strongyloid nematodes of domestic equids. 1996;185–92.
- [3] Lichtenfels JR, Kharchenko VA, Dvojnos GM. Illustrated identification keys to strongylid parasites (strongylidae: Nematoda) of horses, zebras and asses (Equidae). Vet Parasitol. 2008;156(1–2):4–161.
- [4] Saeed MA, Beveridge I, Abbas G, Beasley A, Bauquier J, Wilkes E, et al. Systematic review of gastrointestinal nematodes of horses from Australia. Parasites and Vectors . 2019;12(1):1–16.
- [5] Reinemeyer CR, Nielsen MK. Review of the biology and control of *Oxyuris equi*. Equine Vet Educ. 2014; 26(11):584–91.
- [6] Wolf D, Hermosilla C, Taubert A. *Oxyuris equi*: Lack of efficacy in treatment with macrocyclic lactones. Vet Parasitol. 2014;201(1–2):163–8.
- [7] Coles GC, Jackson F, Pomroy WE, Prichard RK, Von Samson-Himmelstjerna G, Silvestre A, et al. The detection of anthelmintic resistance in nematodes of veterinary importance. Vet Parasitol. 2006;136(3–4):167–85.
- [8] Menzies-gow AN. Pinworm – a growing irritation. 2014;1–7.
- [9] Debra S. Equine infectious diseases (Sellon). 2nd Edition. Debra C. Sellon MTL, editor. St. Louis, Missouri: Copyright © 2014, 2007 by Saunders, an imprint of Elsevier Inc.; 2014. 445–455 p.
- [10] Reinemeyer CR. Anthelmintic resistance in non-strongylid parasites of horses. Vet Parasitol. 2012;185(1):9–15.
- [11] Reinemeyer CR, Prado JC, Nichols EC, Marchiondo AA. Efficacy of pyrantel pamoate and ivermectin paste formulations against naturally acquired *Oxyuris equi* infections in horses. Vet Parasitol. 2010;171(1–2):106–10.
- [12] Nielsen MK, Reinemeyer CR, Sellon DC. Nematodes. Second Edi. Equine Infectious Diseases: Second Edition. Elsevier Inc.; 2013. 475-489.e4 p.
- [13] Wilkes EJA, Cowling A, Woodgate RG, Hughes KJ. Inhomogeneity of the density of *Parascaris* spp. eggs in faeces of individual foals and the use of hypothesis testing for treatment decision making. Vet Parasitol. 2016;229:131–8.
- [14] Lyons ET, Tolliver SC, Kuzmina TA, Collins SS. Critical tests evaluating efficacy of moxidectin against small strongyles in horses from a herd for which reduced activity had been found in field tests in Central Kentucky. Parasitol Res.

- 2010;107(6):1495–8.
- [15] Cleale RM, Edmonds JD, Paul AJ, Reinemeyer CR, Chapman MR, Clem R, et al. A multicenter evaluation of the effectiveness of Quest® Gel (2% moxidectin) against parasites infecting equids. *Vet Parasitol.* 2006;137(1–2):119–29.
- [16] Durham A, Coles G. Worm control in horses: Possible resistance in equine pinworms. *Vet Rec.* 2010;167(23):913–4.
- [17] Stephenson R. Oxyuris equi a resurgent problem? *Companion Anim.* 2010; 15(5): 8–10.
- [18] Bauer C, Çirak VY, Hermosilla C, Okoro H. Efficacy of a 2 per cent moxidectin gel against gastrointestinal parasites of ponies. *Vet Rec.* 1998;143(20):558–61.