

## A pyogenic granuloma on buccal mucosa related to an embedded tooth root

Zahra Jafari<sup>1</sup>, Sara Asgarian<sup>2</sup>, Amir Mansour Shirani<sup>3</sup>

Received: 2023-03-12 / Accepted: 2023-05-02 / First publication date: 2023-05-10  
© The Author(s) 2023

### Abstract

A 48-year-old female complained of a growing mass in the right buccal mucosa near maxillary molar teeth from 3 months ago. Clinical examination showed a pink-red sessile nodule (1.5×1×0.5 cm) with a smooth surface. The mass was generally firm and bony hard in palpation in some areas and had a purulent discharge. Clinical, radiographical and pathological evaluations showed that one of the roots of the first maxillary molar was in the lesion. In a review of the literature, there was no similar case report. Diagnostic assessment and clinical management of the lesion were discussed.

**Keywords:** foreign bodies, tooth root, buccal mucosa, pyogenic granuloma, surgery, radiography

### Introduction

Injuries to the soft tissue of the oral cavity may result from the surgeon's lack of adequate attention to the delicate nature of the mucosa, attempts to do surgery with inadequate access, rushing during surgery, or employing excessive and uncontrolled force.

The most frequent problem of extracting a tooth is the possible fracture of its roots. The tooth root most commonly displaced into unfavourable anatomic spaces is the maxillary molar root, forced into the maxillary sinus (1). Foreign bodies found in or around the oral area such as broken wooden pieces, lead pencil tips, broken tooth fragments, and metallic objects have been reported in the literature (2). Patients may complain of pain. Signs of inflammation with purulent discharge may exist (3).

Trauma and local irritation like root remnants have a significant role in the pathogenesis of reactive tumour-like lesions such as pyogenic granuloma (4). In this case report a patient with a growing tumour-like lesion in the buccal mucosa was presented. Clinical,

radiographic, and pathological evaluations revealed that the lesion was related to an embedded tooth root. In the performed review of literature, articles, books, and the internet there was no similar report of tooth root embedded in the buccal mucosa that have caused a mass.

### Case report

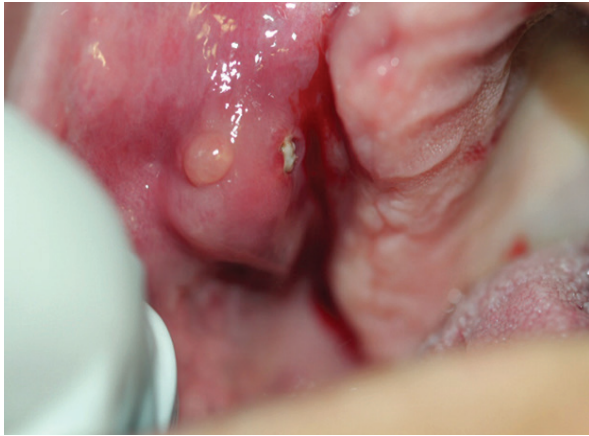A 48-year-old female complained of a mass in the right buccal mucosa near the maxillary molar teeth for the past three months. No relevant medical histories were found. Clinical examination showed a pink-red sessile nodule with a smooth surface in 1.5×1×0.5 cm dimension. A white area was seen in the core of the lesion (figure 1). The mass was firm and bony-hard in touch with a provoked purulent discharge (figure 2). Maxillary first right molar near the lesion was extracted without tooth socket repair. The patient complained of pain at the time of surgery and some days after. Periapical radiographic evaluation of the right upper six areas showed a residual root in the alveolar bone and a fractured root in the soft tissue (figure 3). She was not aware of these residual roots. An excisional biopsy from the lesion was performed. The tooth root was seen in the biopsied specimen, and it was submitted for histopathology evaluation (figure 4). The remaining root in the tooth socket was removed surgically, and antibiotics were prescribed for the patient.

**Corresponding Author:** Dr Zahra Jafari  
Department of oral and maxillofacial medicine, Borujerd Branch, Islamic Azad University, Borujerd, Iran  
E-mail: Z.jafari@iaub.ac.ir

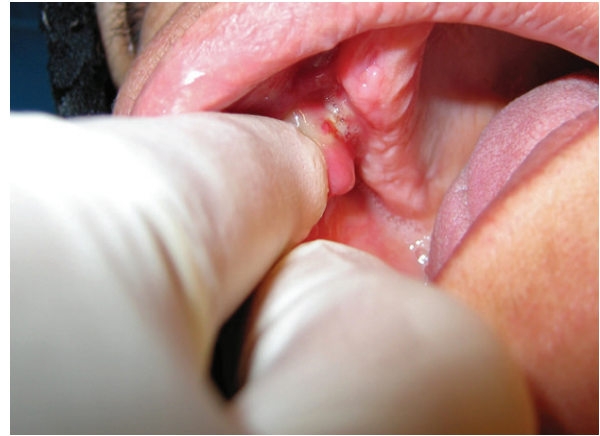<sup>1</sup> Department of oral and maxillofacial medicine, Borujerd Branch, Islamic Azad University, Iran

<sup>2</sup> Oral Medicine specialist

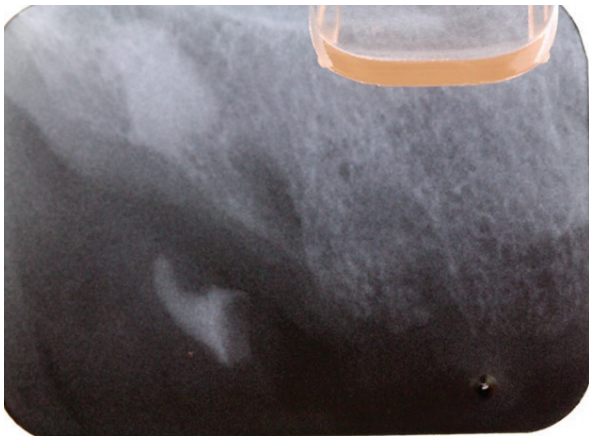
<sup>3</sup> Department of Oral Medicine, School of Dentistry, Isfahan (Khorasgan) Branch, Islamic Azad University, Isfahan, Iran



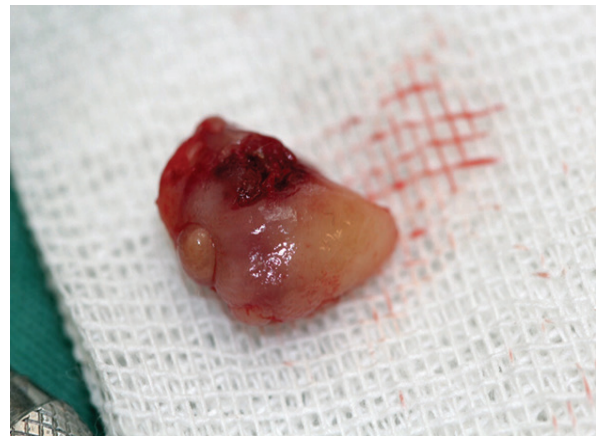**Figure 1.** Tumor-like lesion in buccal mucosa



**Figure 2.** Purulent discharge in palpation



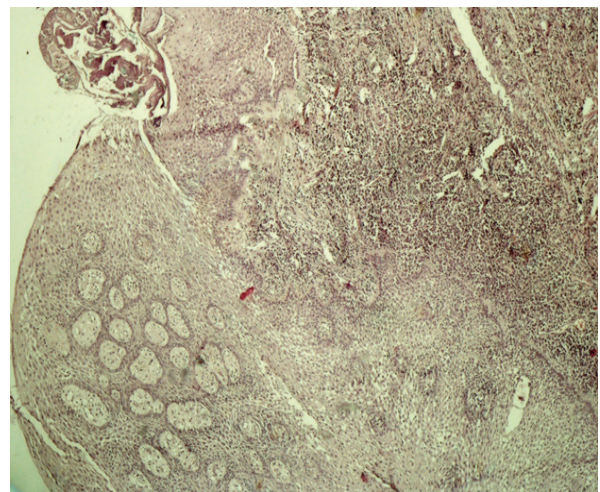
**Figure3.** Periapical radiographic evaluation showed a tooth root outside of the bone



**Figure4.** Tumor-like lesion was removed by scalpel

## Discussion

The presence of embedded foreign body in the soft tissue of the oral cavity is common (1). Foreign bodies such as broken files, lead pencil points, broken tooth fragments, betel nut, fish bone, and metallic pieces have been reported in literature (2). But there was no similar report of tooth roots embedded in the buccal mucosa that have caused a tumour-like lesion. Histopathology evaluation showed para-keratinized and acanthotic stratified epithelium with infiltration of mixed inflammatory cells consisting of plasma cells and lymphocytes in papillary connective tissue. The highly vascular proliferation resembled granulation tissue. The definite diagnosis was pyogenic granuloma (figure 5). Patient had no problem after surgery and no relapse in 6 months' follow-up. When such tumour-like lesion appears on the buccal mucosa, it includes some differential diagnoses: reactive hyperplasia like pyogenic granuloma, Nodular fasciitis, granular cell tumour, tumours of muscle, salivary gland tumours and



**Figure5.** Pyogenic granuloma in pathology evaluation (H&E stain , magnification X4)

malignancies of connective tissue. The clinician must inspect the lesion, palpate it and carefully evaluate the surrounding area. In this case, a bony-hard feeling in

palpation of lesion and purulent discharge of the lesion and a non-healed socket of the molar tooth near the lesion indicated a probability of foreign body. She had a history of extraction before the lesion appeared. A radiography evaluation confirmed the diagnosis. Thus, reactive hyperplasia related to tooth roots was the possible diagnosis.

During a tooth extraction, it is possible to injure neighboring tissues, like inducing the mobility of adjacent tooth, fractured crown, fractured alveolar bone and pushing root to the maxillary sinus (3).

In our case report tooth root was pushed into the buccal mucosa during extraction of the first right upper molar. For surgical removal of foreign bodies precise localization of it is essential since blind searching is time-consuming and may produce further trauma or displacement of the foreign body into the deeper facial planes (5).

Indications for the removal of foreign bodies from soft tissue are thorns, spines, wood and other vegetative materials, heavy contamination, toxicity (heavy metals, spines with venom), impingement of vital structures (vessels, nerves, tendons), impairment of mechanical function (restricted joint mobility), intra-articular location, intravascular location, persistent pain, established infection, allergic reaction, cosmetic, and psychological distress (6).

Foreign bodies may be implanted at a great distance from the mucosa. Teeth and foreign bodies may be ingested or implanted into the soft tissues and may impale the patient. Thorough clinical examination with diagnostic imaging is mandatory in detecting the foreign body (7). Even if imaging is uneventful surgical exploration may be necessary (8). Pathological evaluation of the lesion, in this case, identified that it was a pyogenic granuloma. This is of particular importance to dentists because of its common intraoral occurrence and sometimes alarming clinical course (9). Dentists should be aware that intramucosal foreign body can be an incidental finding on intraoral examinations and can mimic the appearance of a benign and well-defined connective tissue tumors (10).

The surgeon must pay attention to soft tissue while working on bone and tooth structures, and if a laceration of soft tissue happens, it is vital to evaluate the site of injury for the foreign body to prevent an undesired problem for the patient. If a rubber dam were applied to this patient at tooth extraction, it could have prevented the injury to the soft tissues. Dentists need to work according to their ability and refer the patient to a qualified dentist or dental centre at the time of an accident as soon as possible. In diagnosing tumour-like lesions, it will be necessary to consider the foreign body as a potential cause though it is a rare occurrence.

**Conflicts of interest: none**

## References

1. Hupp JR., Ellis III E, Tucker MR. Contemporary oral & maxillofacial surgery. 7th ed. Philadelphia: Elsevier, 2019; 498-518
2. da Silva EJ, Deng Y, Tumushime-Buntro CG. An unusual foreign body in the tongue. Br J Oral Maxillofac Surg, 2000,38:241-242
3. Price C, Whitehead FI. Impression materials as foreign bodies. Br Dent J 1972;133: 9-14
4. Glick M, Greenberg MS, Lockhart PB, Challacombe SJ. Burket's Oral Medicine. 13th ed. Hoboken: Wiley Blackwell, 2021: 176-177
5. Cameron M, Phillips B. Snookered! Facial infection secondary to occult foreign body. Int J Oral Maxillofac Surg. 2006;35:373-5
6. Fonseca RJ, Walker RV, Barber HD, Powers MP, Frost DE. Oral and maxillofacial trauma. 4th ed. Missouri: Elsevier Saunders, 2013,220-231
7. Vikram A, Mowar A, Kumar S. Wooden foreign Body embedded in the zygomatic region for 2 Years. J Maxillofac Oral Surg 2012;11:96-100
8. Mallya SM, LAM EWN. White and Pharoah's oral radiology principles and interpretations. 8th ed. Missouri: Elsevier 2019.: 1233-1284
9. Neville BW, Damm DD, Allen CM, Chi AC. Oral and maxillofacial pathology .4th ed. Missouri: Elsevier, 2019:483-484
10. Puliyeel D, Balouch A, Ram S, Sedghizadeh PP. Foreign body in the oral cavity mimicking a benign connective tissue tumor. Case Rep Dent. 2013;2013:369510