



## ORIGINAL ARTICLE

# Histomorphological Effects of Oral Nicotine Administration on the Testes of Adult Wistar Rats

Ahama Endurance Efe\*, Odokuma Emmanuel Igbo

Delta State University, Abraka, Nigeria

(Received: 5 January 2022

Accepted: 14 June 2022)

## KEYWORDS

Histomorphology;

Nicotine;

Testes;

Alkaloid

**ABSTRACT:** Nicotine is a potent para-symphathomimetic alkaloid, which belongs to the Nightshade family of plants and is abundant in the roots and leaves of these plants. Here, we investigated the histomorphological effects of oral nicotine exposure on the testes of adult Wistar rats. Sixteen adult male Wistar rats were divided into 4 groups (I, II, III, and IV), with each group containing 4 rats per group. Control group (I) received growers mash with water, group II received 2mg kg<sup>-1</sup> day<sup>-1</sup> of nicotine, group III received 4 mg kg<sup>-1</sup> day<sup>-1</sup> of nicotine and group IV received 6 mg kg<sup>-1</sup> day<sup>-1</sup> of nicotine via the oral route of administration, in addition to food and water for six weeks. At the end of the 7<sup>th</sup>, 21<sup>st</sup>, and 42<sup>nd</sup> days of the administration, animals were euthanized by cervical dislocation, and testes were harvested and processed with standard histological techniques. Euthanizing on these various days was done to assess the time and dose-dependent effect of nicotine on the testes. Findings from histological observation of the testes showed similar histoarchitectural changes on different days between the treated groups and the control group. These changes may be attributed to the drug metabolism of nicotine, administration route of nicotine, and drug dosage adopted in the current study. However experimental animals administered with nicotine for 42 days, showed normal histology of the testes with the presence of vascular congestion in the lumen of the seminiferous tubules. Within the limitation and design of this study, oral nicotine exposure at a low dose showed no features of testicular toxicity as there were no histoarchitectural distortions in the treated animals. However, our findings suggest that nicotine exposure at a low dose may possess a therapeutic effect in the management of testicular pathologies.

## INTRODUCTION

Nicotine is a nitrogenous base compound, belonging to the family of nightshade plants (*Solanaceae*) and its primary source is the dried leaves of the tobacco plants [1]. Its structural isomer has a molecular formula of C<sub>10</sub>H<sub>14</sub>N<sub>2</sub>, (with a molecular mass of 162.23mm<sup>-1</sup>) and appears to be colorless and hygroscopic in its fluid form. It is also readily soluble in alcohol and miscible in water at 60°C and 210°C [2]. It is an alkaloid, which forms salts with acids that are usually solid and water-soluble [1]. The Cholinergic system

is tightly regulated by acetylcholine synthesizing enzymes, transporter, receptors, and degrading enzymes [3].

Acetylcholine (ACh) acts in a similar manner as nicotine, it is a natural agonist for the receptors which also bind to nicotine [4]. The body synthesizes ACh from choline and acetyl-CoA by an enzyme called choline acetylase. Synthesis of trimethylamine and beta-chloroethyl acetate in the laboratory gives AChCl (acetylcholine chloride) [5].

\*Corresponding author: efeahama@gmail.com (A. E. Efe)  
DOI: 10.22034/jchr.2022.1949064.1488

Nicotine is a weak base of about 7.9 that is readily absorbed by the lung, oral and nasal mucosa, skin, and GIT. It is widely distributed to several parts of the body, extensively metabolized by the liver, lung, and kidney and its excreted out of the body through urine [6].

The reproductive system of a male is highly sensitive to many chemicals and drugs and has been found to pose adverse effects on the reproductive capacity of males under certain conditions [7]. Decrease in semen qualities such as viability, sperm concentration, motility, morphology, and inhibition of spermatogenesis has been linked to cigarette smoking [8]. Finding from a study has shown the presence and physiologic effects, (positive or negative) of acetylcholine receptor of nicotine ( $\alpha 7$  nAChRs) with expression localized within several parts of the testis of several mammals [9]. Research has proven the presence of nicotine in the Leydig cells, although neither a cell-specific location nor function has been established [10]. Several studies have shown many functions of ACh in the male reproductive tract such as vaso-activity, sperm transport, muscle contraction and cell secretion are mediated via mAChR [9, 10, and 11]. Based on the existing background, this study was conducted to investigate the dose and time-dependent of the oral administration of nicotine on the anatomic architecture of the testes of adult Wistar rats.

## MATERIALS AND METHODS

### *Chemical compound*

The experimental drug was nicotine ((S) -3- (1-Methyl-2pyrroli- vinyl) pyridine).25.0g of nicotine hydrogen salt tartrate [(95% nicotine); Sigma life science, 614-002-00-x United Kingdom (batch number: USAB313 0016, Expiry date: November, 2020)] was purchased from Rovet Scientific shop in Benin-City, Edo State, Nigeria [13].

### *Animal and diet*

Adult male Wistar rats with an average body weight of 150g -200g were purchased from the animal house of Delta State University, Abraka, Nigeria. All animals were fed

with commercially formulated rat chow and water *ad libitum*.

### *Sample size*

This was determined using the resource equation  $E = \text{Total number of animals} - \text{Total number of groups}$ . [14, 15] Where E is the degree of freedom for the analysis of variance. [14] A total number of 16 male adult Wistar rats were used for this study.

### *Experimental design*

This was an experimental and observational study that entailed 16 rats into four groups with 3 regimen dose plans. The rats were weighed, sorted, and assigned to a group containing four rats each. Animals were kept and nurtured under a standard conditions (12 hours light and 12 hours darkness, temp: 28-31°C; humidity: 50-55%) and were allowed to acclimate for two days before administration according to animal acclimatization guidelines stated by Obernier and Baldwin (2008); Animal research ethics (2009). [13, 16] The experiment lasted for 6 weeks with animals euthanized on days 7, 21, and day 42; this was to demonstrate the time and dose-dependent effect of the test agent

### *Dosage and drug administration*

Diluent for the administration of nicotine used was water and the time of administration was twice daily (6.00 am and 6.00 pm); this was to maintain a steady concentration of nicotine in blood circulation Route of administration of the test drug was oral with the use of an orogastric tube and experimental animals were treated as indicated in (Table 1). The LD50 for oral nicotine administration in adult male rats is 50mg kg<sup>-1</sup>. [6]

### *Animal euthanasia*

Experimental rats were euthanized at 7, 21 days, and 42 days by cervical dislocation after an overnight fast. [17] Testes were harvested and fixed immediately into 10% formal saline. [18]

### **Histological procedures**

At the end of each experimental day which was stipulated for 7, 21 days, and 42 days. The animals were weighed and euthanized by cervical dislocation. Testes were grossed, placed in tissue cassette, and processed manually under standard histological procedures which entail several stages, from fixation using 10% formal saline, tissue processing comprises four sections: dehydration (series changes of the tissue in alcohol with time dependency), clearing (series changes of the tissue in xylene also with time-dependent), infiltration (series changes of the tissue in paraffin wax also with time dependency) and embedding

(preparation of tissue block, using a mold), sectioning (using a microtome at 5 to 7 $\mu$ m), staining (using H and E and special stains), mounting (using DPX) and photomicrography. [19, 20]

### **Photomicrography**

Prepared Slides were viewed, and tissue images were captured using a digital microscope “CARL ZEISS (Primo Star)” of about 8.3 megapixel camera, connected to a computer. Obtained micrographs were interpreted to ascertain the histological and cytological effects of nicotine on the testes.

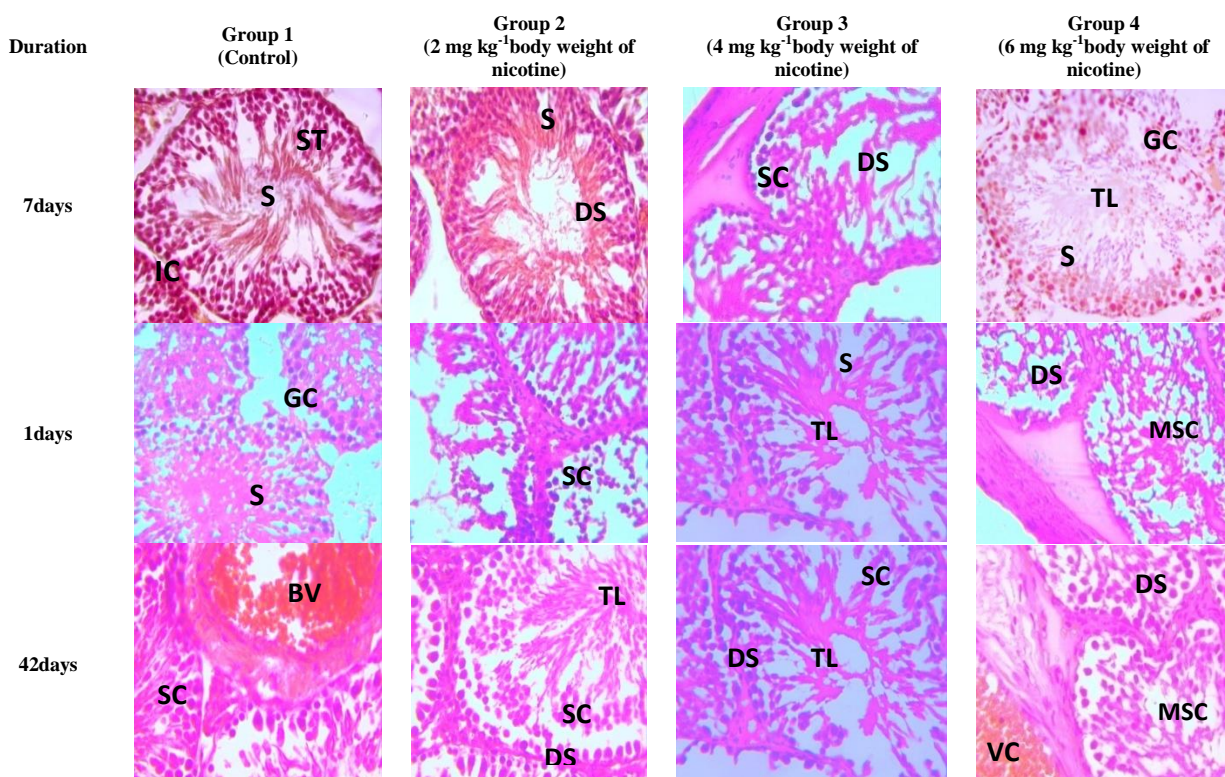
**Table 1.** Experimental groups and Nicotine administration

<b>Group</b>	<b>Designation</b>	<b>Duration (days)</b>	<b>Treatment dose per day</b>
<b>I</b>	Control (n =4)	42 days	Distilled water
<b>II</b>	Low dose (n =4)	7 days	2 mg kg <sup>-1</sup> body weight of nicotine
<b>III</b>	Moderate dose (n =4)	21 days	4 mg kg <sup>-1</sup> body weight of nicotine
<b>IV</b>	Chronic dose (n =4)	42 days	6mg kg <sup>-1</sup> body weight of nicotine

### **RESULTS**

The figure below shows sections of the testes for days 7, 21, and 42 depicting normal testicular histoarchitecture as displayed in the control group. The tubules vary in size and are separated by a loose fibrovascular connective tissue stroma which are sheets of interstitial cells. The seminiferous tubule is lined by stratified germinal

epithelium composed of a basal spermatogonia layer, spermatocytes and spermatozoa disposed to the luminal aspects. Sertoli cells are apparent between these parenchyma cells. Vascular congestion at the 42 days is also prominent within the tubules and the fibro connective tissue enclosing the seminiferous tubules is unremarkable.



**Figure 1.** Histological effects on the testes of experimental animals exposed to different graded doses of nicotine for 7, 21, and 42 days. H & E (x400)

Keywords: **S:** spermatocytes, **DS:** developing spermatogonia, **SC:** Sertoli cells, **TL:** tubule lumen, **BV:** blood vessels. **VC:** vascular congestion, **GC:** interstitial cells.

## DISCUSSION

Nicotine intake is ascribed as a major cause of infertility [21]. It is present in cigarette smoke and has been discovered to inhibit testicular tissue, resulting in impaired reproductive function.[22] Though several authors have documented the effects of varying doses of nicotine on the male reproductive system, most of these studies generally excluded detailed histological investigations unlike it was addressed in the index study [23,24, 25].

The histological findings from this study were in keeping with normal histology sections of the testes with no cellular alterations as shown in graded dose and time exposure manner, except for the result obtained on day 42 showing vascular congestion. The finding however differed from a report conducted by Oyeyipo in Osun State, Nigeria who documented that nicotine affected the testicular tissues, with testosterone levels significantly decreased, observed atrophy in the genital epithelial cells, and testes distortions

of nicotine-treated F1 males [26]. Similarly, although a study revealed normal seminiferous tubules in most of the testes of the laboratory animals with few reported to display slightly altered histoarchitecture [27], a contrary finding was demonstrated in another study report which reported the spermatogenic arrest, at the spermatid stage, following exposure to nicotine, which was observably found to be ameliorated by the therapeutic effect of vitamin E.[28] The positive result obtained from the index study can be inferred as a result of drug metabolism by the liver and enzymes in the gut wall which are implicated to reduce the pharmacological actions of nicotine.[29] The pharmacokinetics of nicotine involves metabolism at several locations of the alimentary canal thus leading to a subsequent reduction in nicotine bioavailability to testicular tissue [6]. Also, a study conducted by [3] reveals a positive effect of nicotine agonists associated with the sufficiency of

mAChR than of nAChR in their study. This was clearly explained with mice deficient for  $\alpha_7$ - nAChR producing sperm with impaired motility and mAChR agonist promotes sperm motility, especially in humans.

The route of nicotine administration employed in the in vivo study may also have contributed to the obtained findings, where nicotine was administered orally for 42 days. This route of drug delivery is the most preferred route due to its non-invasiveness and convenience. Nevertheless, one of the major limitations associated with oral administration is a pharmacological phenomenon called the first-pass effect. This entails drug metabolism by the body leading to a decrease in the unchanged fraction of the drug before it enters the systemic circulation. One of the major organs and sites of metabolism associated with first-pass effect in the liver [30].

Nicotine on the other hand is rapidly and extensively metabolized by the CYP2A6, CYP2B6, CYP2E1 enzymes in the liver, glucuronidation (GG2B10), and N-oxidation [31]. Thus, our findings indicate that the unchanged fraction of nicotine remaining after its rapid metabolism did not induce testicular toxicity hence the testicular histoarchitecture preservation reported in the current study. A study reported the efficiency of the intravenous route, and its ability to bypass the systemic first-pass effect.[32] Despite the routine use of the oral route of administration in the in vivo study, it is however contrary to a study circulated by Jensen and colleagues where they employed the intravenous route of administration because of its efficiency in administering substances to humans since it bypasses the process of solute absorption.[33] This was also in agreement with a study conducted by Jensen and Co. where the comparable difference between smoking and IV infusion in respect to time to reach peak arterial nicotine concentrations were observed to be 20 sec and 30 sec respectively as against the limitations of using the oral route of administration like; potential significant first-pass effect by the liver, local irritation, and absorption of substances by digestive enzymes and acid.[34] Therefore, we affirm that nicotine administration may be advantageous when administered orally as compared with other routes of administration. This is because the

intravenous route of administration is considered a gold standard for assessing dose-dependent effects of drugs [35] The drug dose might also be considered with respect to the histoarchitectural preservation observed in the testes. Benowitz and Hatsukami *et al* considered in their study the gradual reduction in the amount of nicotine in nicotine-based products to achieve a reduce negative health effects caused by nicotine.[36, 37] It is of great importance to determine an accurate threshold dose value for nicotine otherwise erroneous result is inevitable. In comparison to Benowitz and Hutsukami's study, the route of administration used in the index study requires a high dose of nicotine to produce toxicity.[32] This is contrary to a study, with findings revealing the toxic effects of nicotine, with dose-related as a result of overstimulation of the nicotinic receptor, which often leads to inhibitory actions (desensitization) of the receptors, following continuous stimulatory effect from its administration, thereby causing toxicity to the male reproductive system. [25]

Another vital reason for this observed effect may be ascribed to the fact that nicotine is reported to possess antioxidative properties just like other plant antioxidants and compounds. [38, 39, 40, 41] Nicotine attenuated 2,2'-azobis(2-methylpropionamide) dihydrochloride (AAPH) and *tert*-butyl hydroperoxide (*t*-BuOOH) induced hemolysis in erythrocytes through an antioxidative mechanism in a dose-dependent manner.[42] This antioxidant potential of nicotine may be through its interaction with intracellular nicotinic receptors or extracellular through its action as a radical scavenger.[43] In the line with this, the question of whether nicotine protected the testes from cellular degeneration via attenuating oxidative stress is open to further investigations.

## CONCLUSIONS

Nicotine exposure to nicotine at a low dose showed no deleterious effect on the histology of the testes. This may be due to the interactions between and the testicular blood barrier; therefore, further studies should be targeted

towards understanding the exact mechanism of action of nicotine that led to this testicular preservation.

### **Recommendation**

Further study is needful to affirm the findings of the index study and to assess for the therapeutic effect of nicotine in respect to male reproduction.

### **ACKNOWLEDGEMENTS**

The authors are grateful to those researchers whose articles are cited in this manuscript and reviewers who improved this study.

### **ETHICAL CONSIDERATION**

Approval for this study was obtained from the Faculty of Basic Medical Science ethical committee Delta State University Abraka, with reference number: DELSU/CHS/ANA/68/79. This conforms to the guidelines for animal research and National Institute of Health Guide for Care and Use of Laboratory Animals [12]

### **Conflicts of Interests**

The authors declare that there was no conflict of interest.

### **Authors Contributions**

Efe Ahama is the principal investigator and Igho Odokuma is the coordinator of all phases of this study.

### **REFERENCES**

1. Rodgman A.P., Thomas A., 2009. The chemical components of tobacco and tobacco smoke. Boca Raton; FL: CRC Press <http://lcn.loc.gov/2008018913>. Retrieved 2013-02-02.
2. Metcalf R.L., 2007. Insect Control Ullmann's Encyclopedia of Industrial Chemistry (7th ed.), Wiley. pp. 9
3. Beckman J., Lips K.S., 2013. The Non-Neuronal Cholinergic System in Health and Disease. *Pharmacology*. 92, 286 - 302

4. Kishioka S., Kiguchi N., Kobayashi Y., Saika F., 2014. Nicotine effects and the endogenous opioid system". *Journal of Pharmacological Sciences*. 125(2), 117 - 24.
5. Connolly G.N., Alpert H.R., Wayne G.F., Koh H., 2007. Trends in nicotine yield in smoke and its relationship with design characteristics among popular US cigarette brands; 1997-2005". *Tobacco Control* 16:e5.
6. Hollway A.C., 2014. *Encyclopedia of Toxicology, Nicotine*, 3<sup>rd</sup> edition, Elsevier Inc. pp, 514-516.
7. Bonde J.P., Giwercman A., Ernest E., 1996. Identifying environmental risk to male reproductive function by occupational sperm studies: logistics and design problems. *Occup Environ Med*. 53, 511-9
8. Kunzle R., Muller M.D., Hanggi W., Birkhauser M.H., Drescher H., Bersinge N.A., 2003. Semen quality of male smokers and nonsmokers in fertile couples. *Ferile. Steril*. 79, 287-91
9. Bray C., Son J.H., Meizel S., 2005. Mice deficient in the  $\alpha 7$  subunit of the nicotinic acetylcholine receptor produce sperm with impaired motility. *Biol Reprod*. 73, 807 - 814.
10. Haberberger R.V., 2002. Expression of the high-affinity choline transporter, CHT1, in the neuronal and non-neuronal cholinergic system of human neuronal cholinergic system in the endothelium: evidence and possible pathobiological significance. 119, 943-948.
11. McGehee D.S., Role L.W., 1995. Physiological diversity of nicotinic acetylcholine receptors expressed by vertebrate neurons. *Annu Rev Physiol*. 57, 521-46.
12. Animal research ethics, 2005. A handbook of USP researchers. 1st ed. Research office publisher, South Pacific. 2, 3-4.
13. Oyem J.C., Odokuma E.I., 2018. Histomorphological Effects of Nicotine on Selected Parts of the Brain of Adult Wistar Rats. *Galician Medical Journal*. 25(2), 4
14. Festing M.F.W., 2020. How to Reduce the Number of Animals Used in Research by Improving Experimental Design and Statistics, ANZCCART Human Science Fact Sheet T10.
15. Jatinder S., 2012 National centre for replacement, refinement, and reduction animals in research.

Experimental design/statistics. *J Pharmacol Pharmacother.* 3(1), 8789.

16. Obernier J.A., Baldwin R.L., 2008. Establishing an appropriate period of acclimatization following transportation of laboratory animals. *ILAR J.* 47(4), 364-369

17. Reilley J.S., 2000. Euthanasia of animals used for scientific purposes. 1<sup>st</sup> ed. ANZCCART, Australia. 1, 11

18. Burnett D., Crocker J., 2005. Specimen handling and preparation for routine diagnostic histopathology. In: *The science of laboratory diagnosis.* 2nd ed. John Wiley and sons, England. 1, 5-7.

19. Ross M.H., Pawlina W., 2016. *Histology: a text and atlas: with correlated cell and molecular biology* (7<sup>th</sup> Edition). WoltersKluwer. pp. 984.

20. Rieger J., Pelckmann L.M., Drewes B., 2021. Preservation and processing of intestinal tissue for assessment of histopathology. *Methods in Molecularbiology.* (Clifton, N.J.) 2223, 267 - 280.

21. Jamshidian H., Amini E., 2019. Effects of Opium Dependency on Testicular Tissue in a Rat Model: An Experimental Study. *Urol J.* 16, 375-79.

22. Bolat S.M., Akdeniz E., 2015. Smoking and Lower Urinary Tract Symptoms. *Urol J.* 12, 2447-51.

23. Dalila R., Aicha J., 2018. Semen Parameter Alteration, Histological Changes and Role of Oxidative Stress in Adult Rat Epididymis on Exposure to Electronic Cigarette Refill Liquid. *Chinese Journal of Physiology.* 61(2), 75-84.

24. Abeer R.H.M., Nashwa M.M.S., 2019. Ameliorative Effect of Zinc Oxide Nanoparticles on Nicotine Induced Testicular Dysfunction; Biochemical and Histological Study. *Toxicol Environ Health Sci.* 11(2), 104-113.

25. Davoud K., Seyyed M.M.S., Ahmed A., Leila K., Farhad R., 2021. Administration of Nicotine Exacerbates the Quinine-induced Structural and Functional Alterations of Testicular Tissue in Adult Rats: An Experimental Study. *Urology Journal.* 18(1), 103-110.

26. Oyeyipo I.P., Adeyemi D.H., Abe T.R., 2018. Testosterone and testicular changes in F1 offspring of Wistar rats maternally exposed to nicotine during gestation. *JBRA Assisted Reproduction.* 22(3), 162-166.

27. Ibraheem M.G., Nanyak Z.G., Adamu G., Ayaka L., Ali A.H., Mohammed M.B., Najimuddeen B., Ahmed M.R., Samuel O.O., 2013. The effect of aqueous leave extract of *nicotianatabacum* (tobacco) on some reproductive parameters and micro-anatomical architecture of the testis in male albino wistar rats. *Journal of Natural Sciences Research.* 3(5), 2224-3186

28. Bisong S.A., Ukoh I.E., Nna V.U., Ebong P.E., 2018. Vitamin E attenuates nicotine and noise- induced reproductive impairment in male albino Wistar rats, *Andrologiae*13050. <https://doi.org/10.1111/and.13050>

29. U.S. Environmental Protection Agency Guidelines for Reproductive Toxicity Risk Assessment Proposed Guidelines: Proposed Guidelines for Female Reproductive Risk and Proposed Guidelines for Male Reproductive Risk. Report No:EPA/630/R-96/009 [accessed: 10 March 2019] Available from, [https://www.epa.gov/sites/production/files/201411/documents/guidelines\\_repro-toxicity.pdf](https://www.epa.gov/sites/production/files/201411/documents/guidelines_repro-toxicity.pdf). (1996).

30. Wang X., Zheng M., Liu J., Huang Z., Bai Y., Ren Z., Wang Z., Tian Y., Qiao Z., Liu W., Feng F., 2017. Differences of first pass effect in the liver and intestine contribute to the stereoselective pharmacokinetics of rhynchophylline and isorhynchophylline epimers in rats. *Journal of Ethnopharmacology.* 209, 175 - 183.

31. Benowitz N.L., 2009. Pharmacology of nicotine: addiction, smoking-induced disease and therapeutics. *Annual review of Pharmacology and Toxicology.* 49, 57 - 71.

32. Rang H.P., Dale M.M., Ritter J.M., Flower R.J., 2007. *Rang and Dale's Pharmacology*, 6<sup>th</sup> edition, Churchill Livingstone Elsevier, 2007, edition, Section 1 Chapter 8. pp. 104-108

33. Jensen K.P., DeVito E.E., 2016. Intravenous Nicotine Self-Administration in Smokers: Dose-Response Function and Sex Differences. *Neuro Psychopharmacology.* 41(8), 2034 - 2040.

34. Jensen K.P., DeVito E.E., Sofuoglu M., 2016. How Intravenous Nicotine Administration in Smokers Can Inform Tobacco Regulatory Science. *Tob Regul Sci.* 2(4), 452 - 463.

35. Goodwin A.K., Hiranita T., Paule M.G., 2015. The Reinforcing Effects of Nicotine in Humans and Nonhuman Primates: A Review of Intravenous Self-Administration Evidence and Future Directions for Research. *Nicotine Tob Res.* 17(11),1297-1310
36. Benowitz N.L., Henningfield J.E., 1994. Establishing a nicotine threshold for addiction. The implications for tobacco regulation. *N Engl J Med.* 331(2), 123 - 125.
37. Hatsukami D.K., Benowitz N.L., 2013. Nicotine Reduction: Strategic Research Plan. *Nicotine & Tobacco Research.* 15(6), 1003 - 1013.
38. Ichipi-Ifukor P.C., Asagba S.O., Nwose C., 2022. Palm oil extracts protected against cadmium chloride poisoning via inhibition of oxidative stress in rats. *Bull Natl Res Cent.* 46(5), 1-11
39. Oyem J.C., Chris-Ozoko L.E., Enaohwo M.T., Otabor F.O., Okudayo V.A., Udi O.A., 2021. Antioxidative properties of *Ocimum gratissimum* alters Lead acetate induced oxidative damage in lymphoid tissues and hematological parameters of adult Wistar rats. *Toxicol Rep.* 10(8), 215-222.
40. Mujittapha S.U., Kauthar M., Azeez I.O., Oyem J.C., 2020. Ascorbic acid improves extrapyramidal syndromes and corpus striatal degeneration induced by dopamine-2 receptor inhibition in Wistar rats. *Drug Metab Pers Ther.* 2020 Nov 2:/j/dmdi.ahead-of-print/dmdi-2020-0137/dmdi-2020-0137.xml.
41. Chris-Ozoko L.E., Okpe O., Iju W.J., Oyem J.C., 2018. Histomorphological Effects of Cottonseed Oil on Testes in Adult Male Wistar Rats. *Galician Medical Journal.* 25(4), 1-5.
42. Malczewska-Jaskóła K., Jasiewicz B., Mrówczyńska L., 2016. Nicotine alkaloids as antioxidant and potential protective agents against in vitro oxidative haemolysis. *Chem Biol Interact.* 5(243), 62-71.
43. Newman M.B., Arendash G.W., Shytle R.D., Bickford P.C., Tighe T., Sanberg P.R., 2002. Nicotine's oxidative and antioxidant properties in CNS. *Life Sci.* 71(24), 2807-20.