

Expression of Toll-Like Receptor4 (TLR4) in Pancreas of Obese Chicken

Research Article

S.K. Pathak^{1*}, P. Suvaneeth² and E. Raja Ravi Teja¹

¹ Department of Veterinary Anatomy, Faculty of Veterinary and Animal Science, Institute of Agricultural Science, Rajiv Gandhi South Campus, Banaras Hindu University, Barkachha, Mirzapur, Uttar Pradesh, India

² Department of Veterinary Pathology, Faculty of Veterinary and Animal Science, Institute of Agricultural Science, Rajiv Gandhi South Campus, Banaras Hindu University, Barkachha, Mirzapur, Uttar Pradesh, India

Received on: 14 Sep 2022

Revised on: 11 Nov 2022

Accepted on: 8 Dec 2022

Online Published on: Mar 2023

*Correspondence E-mail: satishpathak26@gmail.com

© 2010 Copyright by Islamic Azad University, Rasht Branch, Rasht, Iran

Online version is available on: www.ijas.ir

ABSTRACT

Present study tried to explore the expression of TLR4 in different parts of pancreas in relation to obesity. Broiler chicken of slaughter age (42±2 days) were selected for the study (n=30). The birds were grouped into two categories based on their body weight. Group I included birds of ≤ 1.7 kg (n=15), and group II contained birds weighing > 1.7 kg (n=15). Abdominal fat content and distribution was taken in all groups. Representative samples from dorsal, ventral and splenic lobes of pancreas were subjected to histopathology and immunohistochemistry. Obese birds showed a higher proportion of fat deposits mainly at the caudal part of abdominal cavity. The pancreatic cells in normal as well as in obese birds were devoid of any signs of cellularity, hypo/hyperplasia, degeneration and inflammation. TLR4 was detected in all three lobes of pancreas and both exocrine and endocrine parts of pancreas in all obese birds. Our results indicated that there is a direct link between obesity or visceral fat deposition and expression of TLR4 in birds.

KEY WORDS chicken, obesity, pancreas, TLR4.

INTRODUCTION

Toll-like receptors being pattern recognition receptors play a crucial role in innate immune response. The most analyzed receptor in mammals is toll-like receptors 4 (TLR4). The expression of TLR4 was reported in mammals in response to lipopolysaccharide (LPS) of gram-negative bacteria and several types of tumors. Recent studies showed that TLR4 expressed in response to endogenous ligands such as lipids (Fessler *et al.* 2009). There were few findings related to non-immune expression of TLR4 in endocrine (Vives-Pi *et al.* 2003; Goldberg *et al.* 2007) and exocrine parts (Li *et al.* 2005) of pancreas. Although Eguchi *et al.* (2012) suggested that saturated fatty acid can induce inflammation in β-cells of pancreas via TLR4 pathway, the relationship be-

tween expression of TLR4 and obesity have not been well studied yet. Present study tried to explore the expression of TLR4 in different parts of pancreas in relation to obesity.

MATERIALS AND METHODS

Birds

Broiler chicken of slaughter age (42±2 days) were selected for the study (n=30). The birds were grouped into two categories based on their body weight. Group I included birds of ≤ 1.7 kg (n=15), and group II contained birds weighing > 1.7 kg (n=15). Abdominal fat content and distribution was taken in all groups. Representative samples from dorsal, ventral and splenic lobes of pancreas were subjected to histopathology and immunohistochemistry.

Preparation of slides for immunohistochemistry

Microscope slides with one end frosted (Borosil, India) were thoroughly cleaned by detergent based washing, rinsed in distilled water (three changes), and was followed by air drying in dust free chamber at room temperature overnight. The slides were coated with two percent (3-Aminopropyl) triethoxysilane (Sigma-Aldrich, USA) in acetone for a period of 30 minutes, followed by single dip in acetone and two changes of distilled water. The slides were dried in an incubator at 37 °C for 24 hrs and were stored in slide box till use.

Immunostaining

The tissues were fixed in 10% neutral buffered formalin for 72 hours. Tissues were processed through alcohol- xylene- paraffin processing technique and sections of 5 µm thick were cut. Sections were taken on adhesive coated slides (as described above). Slides were kept at room temperature overnight. Sections were deparaffinised by keeping in xylene (three changes and 3 minutes each). Sections were rehydrated in graded series of ethanol (two changes of absolute alcohol and 3 minutes each, single change in 90% and 80% alcohol and 3 minutes each). Antigen retrieval was performed in citrate buffer (pH: 6) in microwave oven (700 Watt for 20 minutes). The sections were then incubated overnight in moist chamber at 4 °C with rabbit anti-TLR4 antibody (Sigma Aldrich, USA) at a dilution of 1:200. The immunostaining was carried out using Anti-Rabbit HRP-DAB Cell and Tissue Staining Kit (R&D Systems, Minneapolis, MN, USA) following the manufacturer's protocol. Sections were counterstained with Meyer's hematoxylin.

RESULTS AND DISCUSSION

Distribution of abdominal fat

The distribution of abdominal fat in all the birds was compared. Obese birds showed a higher proportion of fat deposits mainly at the caudal part of abdominal cavity. The visceral organs like gizzard, portion of large intestine and reproductive organs had fairly good accumulation of yellowish fat (Figure 1). Birds in the lighter weight group showed a fair accumulation of fat around the abdominal musculature and minimal deposition around the visceral organs.

Topographic relations of pancreas

Pancreas was situated in a loop formed by descending and ascending parts of duodenum in chicken. Splenic lobe of pancreas was attached with spleen. Visceral fat deposits were found near the duodenal loop in few obese birds.

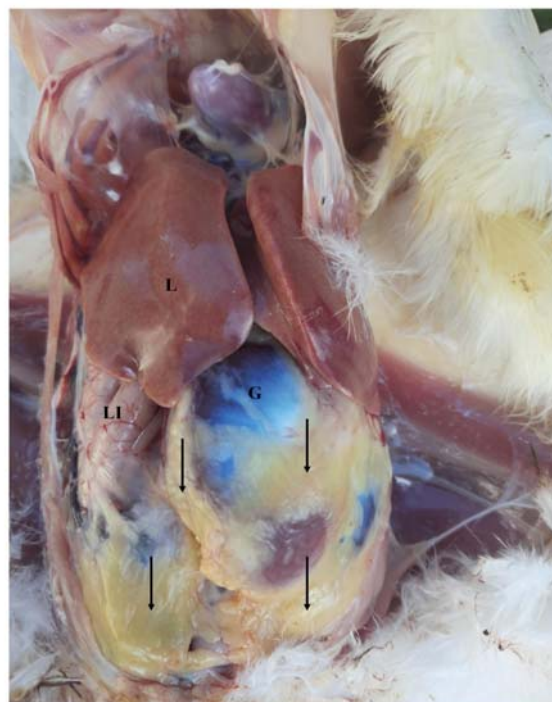

Figure 1 Photograph showing distribution of abdominal fat (arrows), L: liver, G: gizzard and LI: large intestine

Histopathology

Histopathological observations of all the three lobes, viz. dorsal, ventral and splenic lobes of the pancreas revealed that each lobe was divided into indistinct lobules and had both exocrine and endocrine parts. Exocrine parts (pancreatic acini) formed the major part of the parenchyma in all lobes. Endocrine parts (Islets of Langerhans) were few and were found scattered all over the parenchyma. The splenic lobe had a higher proportion of endocrine parts compared to dorsal and ventral lobes. The pancreatic cells in normal as well as in obese birds were devoid of any signs of cellularity, hypo/hyperplasia, degeneration and inflammation.

Immunohistochemistry

TLR4 was detected in all three lobes of pancreas and both exocrine and endocrine parts of pancreas in all obese birds (Figure 2 and Figure 3). In most of the cases, capsule and nearby areas were positive. The staining of TLR4 was negative in all three lobes of pancreas in case of normal weight group (Figure 4).

In the present study, birds are categorized as obese based on its body weight and distribution and deposition of abdominal fat which is considered as an important reliable parameter for evaluating total body fat (obesity) in avian species (Becker *et al.* 1979; Thomas *et al.* 1983).

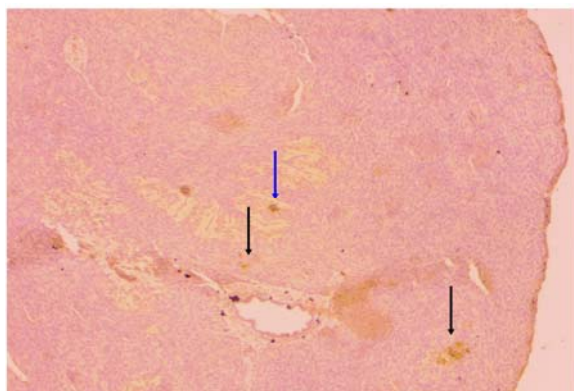


Figure 2 Immunohistochemical detection of TLR4 in splenic lobe of pancreas of obese chicken in endocrine (blue arrow) and exocrine (black arrows) parts (Magnification, X 100)

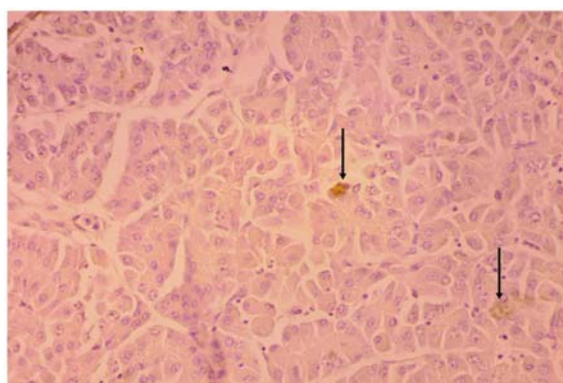


Figure 3 Immunohistochemical detection of TLR4 in dorsal lobe of pancreas of obese chicken in exocrine (black arrows) part (Magnification, X 400)

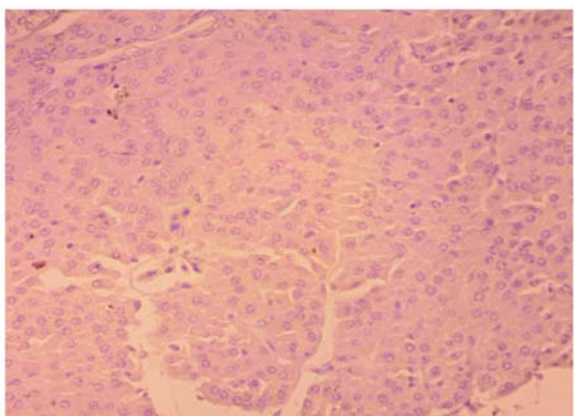


Figure 4 Immunohistochemical detection of TLR4 in dorsal lobe of pancreas of normal chicken (Magnification, X 400)

The higher weight groups naturally had a higher percentage of abdominal and visceral fat depositions and were grouped as obese birds for the purpose of the study.

Presently, there are no studies correlating effect of obesity and TLR4 based inflammatory pathway in any *in vivo* experimental study model. Dietary induced excess body fat

can stimulate an inflammatory response through the TLR4 signaling pathway (Lee *et al.* 2001; Hwang *et al.* 2016). In the present study, the TLR4 immunostaining was detected in the pancreas of obese birds only, suggesting that TLR4 expression has a direct correlation with fat deposition in the body.

The expression of TLR4 reported in endocrine part of pancreas (beta cells) in experimental mice has led to the rejection of graft after transplantation (Vives-Pi *et al.* 2003; Goldberg *et al.* 2007).

Li *et al.* (2005) showed that TLR4 is expressed in exocrine part of rat pancreas (pancreatic ductal epithelium and vascular endothelium) in cerulein-induced pancreatitis. TLR4 suppress the proliferation of adipose tissue macrophages for a short period in high fat diet exposed mice (Griffin *et al.* 2018). The nonmicrobial origin endogenous ligands such as fatty acids can stimulate the expression of TLR4 in mice (Weatherill *et al.* 2012). Excess circulating saturated fatty acids are potential dietary trigger for the initiation of chronic inflammation (as also seen in type-2 diabetes) in mice via expression of TLR4 (McKernan *et al.* 2020). The above studies were based on dietary induced expression of TLR4 in both exocrine and endocrine parts of pancreas in obese animals but in present study we tried to explore the expression of TLR4 in relation to excess accumulation of body fat in bird model. Our results indicated that there is a direct link between obesity or visceral fat deposition and expression of TLR4 in birds.

The present study indicates that a higher expression of Toll-like receptors 4 is seen in birds when the body fat content is higher. High fat diet has already been proven to affect pancreatic functions (Lee *et al.* 2003; Hwang *et al.* 2016). This study suggests that a higher body fat content can also trigger TLR4 based inflammatory pathways in pancreas and that can result in various detrimental effects including insulin resistance (Kim and Sears, 2010). Though avian species are not an ideal model for insulin resistance studies, the activation of TLR4 associated immune pathway in obesity indicates that specific experimental models may be sought for unspecified obesity and its role in pancreatic inflammation/insulin resistance.

CONCLUSION

The present study indicates toll-like receptors 4 were expressed in both exocrine and endocrine portion of pancreas of obese birds.

ACKNOWLEDGEMENT

We thank Dr. Kaushik Satyaprakash and Dr. Pesingi Pavan Assistant Professors, department of Veterinary Public Health and Epidemiology, Faculty of Veterinary and Ani-

mal Science, Banaras Hindu University for the help and assistance.

REFERENCES

- Becker W.A., Spencer J.V., Mirosh L.W. and Verstrate J.A. (1979). Prediction of fat and fat free live weight in broiler chickens using back skin fat, abdominal fat and live body weight. *Poult. Sci.* **58**, 835-842.
- Eguchi K., Manabe I., Oishi-Tanaka Y., Ohsugi M., Kono N., Ogata F., Yagi N., Ohto U., Kimoto M. and Miyake K. (2012). Saturated fatty acid and TLR signaling link β cell dysfunction and islet inflammation. *Cell Metab.* **15**, 518-533.
- Fessler M.B., Rudel L.L. and Brown J.M. (2009). Toll-like receptor signaling links dietary fatty acids to the metabolic syndrome. *Curr. Opin. Lipidol.* **20**, 379-385.
- Goldberg A., Parolini M., Chin B.Y., Czismadia E., Otterbein L.E., Bach F.H. and Wang H. (2007). Toll-like receptor 4 suppression leads to islet allograft survival. *FASEB J.* **21**, 2840-2848.
- Griffin C., Eter L. and Lanzetta N., Abrishami S., Varghese M., McKernan K., Muir L., Lane J., Lumeng C.N. and Singer K. (2018). TLR4, TRIF, and MyD88 are essential for myelopoiesis and CD11c(+) adipose tissue macrophage production in obese mice. *J. Biol. Chem.* **293**(23), 8775-878.
- Hwang D.H., Kim J.A., Lee J.Y. and Heikkinen A. (2016). Mechanisms for the activation of Toll-like receptor 2/4 by saturated fatty acids and inhibition by docosahexaenoic acid. *European J. Pharmacol.* **785**, 24-35.
- Kim J.J. and Sears D.D. (2010). TLR4 and insulin resistance. *Gastroenterol. Res. Pract.* **2010**, 1-11.
- Lee J.Y., Sohn K.H., Rhee S.H. and Hwang D. (2001). Saturated fatty acids, but not unsaturated fatty acids, induce the expression of cyclooxygenase-2 mediated through Toll-like receptor 4. *J. Biol. Chem.* **276**, 16683-16689.
- Lee J.Y., Plakidas A., Lee W.H., Heikkinen A., Chanmugam P., Bray B. and Hwang D.H. (2003). Differential modulation of Toll-like receptors by fatty acids: preferential inhibition by n-3 polyunsaturated fatty acids. *J. Lipid Res.* **44**(3), 479-486.
- Li Y., Zhou Z.G., Xia Q.J., Zhang J., Li H.G., Cao G.Q., Wang R., Lu Y.L. and Hu T.Z. (2005). Toll-like receptor 4 detected in exocrine pancreas and the change of expression in cerulein-induced pancreatitis. *Pancreas.* **30**(4), 375-381.
- McKernan K., Varghese M., Patel R. and Singer K. (2020). Role of TLR4 in the induction of inflammatory changes in adipocytes and macrophages. *Adipocyt.* **9**(1), 212-222.
- Thomas V.G., Mainguy S.K. and Prevett J.P. (1983). Predicting fat-content of geese from abdominal fat weight. *J. Wildl. Manage.* **47**, 1115-1119.
- Vives-Pi M., Somoza N., Fernández-Alvarez J., Vargas F., Caro P., Alba A., Gomis R., Labeta M.O. and Pujol-Borrell R. (2003). Evidence of expression of endotoxin receptors CD14, toll-like receptors TLR4 and TLR2 and associated molecule MD-2 and of sensitivity to endotoxin (LPS) in islet beta cells. *Clin. Exp. Immunol.* **133**, 208-218.
- Weatherill A.R., Lee J.Y. and Zhao L., Lemay D.C., Youn H.S. and Hwang D.H. (2012). Saturated and polyunsaturated fatty acids reciprocally modulate dendritic cell functions mediated through TLR4. *J. Immunol.* **174**(9), 5390-5397.