



## Original Article

# Determining the normal diameter of cystic and common bile ducts in adult German Shepherd dogs by ultrasonography method

Samin Ziadlou<sup>1</sup>, Siamak Alizadeh<sup>2\*</sup>, Mohammadreza Hosseini<sup>3</sup>

<sup>1</sup> Department of Clinical Sciences, Faculty of Veterinary Medicine, Urmia Branch, Islamic Azad University, Urmia, Iran

<sup>2</sup> Department of Veterinary Medicine, Naghadeh Branch, Islamic Azad University, Naghadeh, Iran

<sup>3</sup> Department of Basic Sciences, Faculty of Veterinary Medicine, Urmia Branch, Islamic Azad University, Urmia, Iran

## ARTICLE INFO

Received: 04 February 2024

Accepted: 22 July 2024

## KEYWORDS :

Common bile duct

Cystic duct

German Shepherd dog

Ultrasonography

## ABSTRACT

The current study aimed to evaluate the normal diameter size of cystic and common bile ducts by ultrasound method in adult German Shepherd dogs with 95% confidence to be used in the interpretation of results and clinical decisions. In this cross-sectional descriptive study used 12 adult German Shepherd dogs (6 males and 6 females) with an average weight of  $24.37 \pm 3.65$  kg and a mean age of  $2.40 \pm 0.495$  years. Ultrasonography of these dogs were obtained from dorsoventral, left and right lateral recumbency in the inspiration phase of the animal's breathing. Anatomical studies were performed following anesthesia and during surgery of each dog. According to the results of this study, the mean diameter of the cystic duct in gallbladder level was  $4.17 \pm 0.58$  mm, and the mean diameter of the common bile duct in the hepatis porta and major duodenal papilla levels were  $3.23 \pm 0.48$  and  $3.14 \pm 0.63$  mm, respectively. The diameter of the cystic duct in the gallbladder level is greater in males than in females, and the mean diameter of the common bile duct in the hepatis porta and major duodenal papilla levels is larger in females than in males but the differences are not significant ( $p > 0.05$ ). The findings obtained in this study can be utilized to interpret the findings and clinical decisions about the normal and abnormal size of the diameter of the cystic and the common bile duct in adult German Shepherd dogs.

## تعیین اندازه استاندارد قطر مجرای سیستیک و مجرای مشترک صفراوی در سگ‌های ژرمن شپرد با روش اولتراسونوگرافی

ثمین زیادللو<sup>۱</sup>، سیامک علیزاده<sup>۲\*</sup>، محمد رضا حسینی<sup>۳</sup>

<sup>۱</sup> گروه علوم درمانگاهی، دانشکده دامپزشکی، واحد ارومیه، دانشگاه آزاد اسلامی، ارومیه، ایران

<sup>۲</sup> گروه دامپزشکی، واحد تقه، دانشگاه آزاد اسلامی، تقه، ایران

<sup>۳</sup> گروه علوم پایه، دانشکده دامپزشکی، واحد ارومیه، دانشگاه آزاد اسلامی، ارومیه، ایران

## چکیده

هدف از این مطالعه تعیین اندازه قطر مجرای سیستیک و مجرای مشترک صفراوی با روش اولتراسونوگرافی در سگ‌های ژرمن شپرد بالغ با اطمینان ۹۵ درصد بود تا در تفسیر نتایج و تصمیم‌گیری‌های بالینی استفاده شود. در این مطالعه توصیفی - مقطعی از ۱۲ قلاده سگ ژرمن شپرد بالغ (۶ قلاده نر و ۶ قلاده ماده) با میانگین وزنی  $24.37 \pm 3.65$  کیلوگرم و میانگین سنی  $2.40 \pm 0.495$  سال استفاده شد. در سگ‌های تحت مطالعه اولتراسونوگرافی در حالت خوابیده به پشت و خوابیده به پهلو راست و چپ و در مرحله دم حیوان انجام گرفت. مطالعات آناتومی نیز متعاقب بی‌هوشی و در حین جراحی هر حیوان انجام گرفت. بر اساس نتایج این مطالعه در روش اولتراسونوگرافی، میانگین قطر مجرای سیستیک در سطح کیسه صفرا  $4.17 \pm 0.58$  میلی‌متر بوده و میانگین قطر مجرای مشترک صفراوی در سطوح پورتا هپاتیس و پایپای بزرگ دوازده به ترتیب  $3.23 \pm 0.48$  و  $3.14 \pm 0.63$  میلی‌متر بود. قطر مجرای سیستیک در سطح کیسه صفرا در جنس نر بزرگ‌تر از جنس ماده و قطر مجرای مشترک صفراوی در سطح پورتا هپاتیس و پایپای بزرگ دوازده در جنس ماده بزرگ‌تر از جنس نر بود ولی این اختلاف‌ها معنی‌دار نبودند ( $p > 0.05$ ). استانداردهای دقیق به دست آمده در این مطالعه می‌تواند در تفسیر نتایج و ارزیابی‌های بالینی برای تعیین اندازه طبیعی و غیرطبیعی قطر مجرای سیستیک و مجرای مشترک صفراوی در سگ‌های ژرمن شپرد بالغ مورد استفاده قرار گیرد.

**واژه‌های کلیدی:** مجرای مشترک صفراوی، مجرای سیستیک، سگ ژرمن شپرد، اولتراسونوگرافی

\* Corresponding author: [s\\_alizadeh01@yahoo.com](mailto:s_alizadeh01@yahoo.com)

©2024 Islamic Azad University, Urmia Branch.

This work is licensed under a [Creative Commons Attribution 4.0 International License](https://creativecommons.org/licenses/by/4.0/).



## INTRODUCTION

The gallbladder of dogs is located on the visceral surface of the liver between the square and middle right lobes and in the 8th to 10th intercostal space. In the liver, bile drains through channels into the interlobular ducts. Then these ducts unite and form the hepatic duct that leaves the lobes of the liver. There are usually three to five hepatic ducts that drain into the cystic duct, which this duct in turn drains into the gallbladder. After entering the last hepatic duct, the cystic duct becomes the bile duct (sometimes called the common bile duct) which also drains into the duodenum at the major duodenal papilla [1]. Complications of hepatic bile ducts are common disorders that are affected by various factors, such as the presence of tumors in these ducts, tumors of the head of the pancreas, enlarged lymph nodes, and gallstones that cause inflammation and dilatation of the gallbladder. These structural changes in the bile ducts can interfere with the flow of bile and cause disturbances in the emptying of the gallbladder and lead to complications such as cholestasis [2, 3]. In fact, one of the main signs of these complications will be change in the diameter of these ducts, and therefore, to identify abnormal cases, it is necessary to know the normal range. The natural size and range of body organs is influenced by sex, breed, size, age and type of nutrition and differs in various breeds of animals [4, 5]. These parameters are changeable and may have a relationship with other variables, and the scope of these changes and differences between healthy animals does not exceed a certain range [6]. Various studies have been conducted in relation to evaluating the diameter of the bile ducts in dogs. In one study, the authors reported that the average diameter of the common bile duct is 3 mm in normal state, 5-6 mm diameter is suspicious, and dilatation is 6.5 mm [7]. Prak et al. (2018) announced that

the diameter of the common bile duct in normal dogs weighing less than 15 kg at the levels of the hepatis porta and duodenal papilla is less than 3 mm and 3.5 mm, respectively [8]. In another study, it has been reported that the diameter of the cystic duct in dogs with the age group of 2 to 3 years was  $2.6 \pm 1.2$  mm, in the age group of 4 to 5 years of  $4.6 \pm 1.4$  mm, in the age group of 5 to 6 of  $4.4 \pm 1.2$  mm, in the age group of 6 to 7 years of  $4.8 \pm 1.8$  mm and in the age group over 7 years of  $4.6 \pm 1.8$  mm, which in the adult group, for each year of age increase, 0.05 mm is added to the duct diameter [9]. Rahmani et al. (2022) reported that if the diameter of the extrahepatic bile ducts is more than 6 mm and the diameter of the intrahepatic bile ducts is more than 4 mm, it indicates their dilatation. Of course, they did not mention the normal values of these ducts in this study [10]. In veterinary examinations, ultrasonography is an easy, accurate and inexpensive method to evaluate the gallbladder and dilatation of the hepatic bile ducts and usually the first evaluation is done with it [11]. Examining the gallbladder and common bile duct by ultrasound depends on factors such as the skill of the operator and the different shapes of the gallbladder [12]. In addition, the evaluation of these ducts can be difficult due to the artifacts caused by the presence of gas in the intestines and the change in their diameter when the animal breathes [13]. Since there has been no study on the determination of the normal diameter of the extrahepatic bile ducts in German Shepherd dogs, this research was conducted. The main aim of this study was to determine the standard values of cystic and common bile duct diameter by ultrasound method in adult German Shepherd dogs with 95% confidence and the secondary purpose was to investigate the statistical analysis of the presence or absence of a significant difference between the mean diameter of these ducts among male and female dogs of this breed.

## MATERIALS AND METHODS

### *Study Design and Animals*

In this cross-sectional descriptive study used 12 adult German shepherd dogs (6 males and 6 females) with an average weight of  $24.37 \pm 3.65$  kg and a mean age of  $2.40 \pm 0.495$  years with a standard deviation of 1, error of 0.2, and wrong level of 5%. For this purpose, used German shepherd dogs, which were referred to Islamic Azad Urmia University Veterinary Clinic for non-emergency abdominal surgery. Dogs that had symptoms related to complications of the liver, biliary system, pancreas or ascites were excluded from this study. First, each of these dogs underwent ultrasonography and was performed anatomical examination following anesthesia and abdominal surgery.

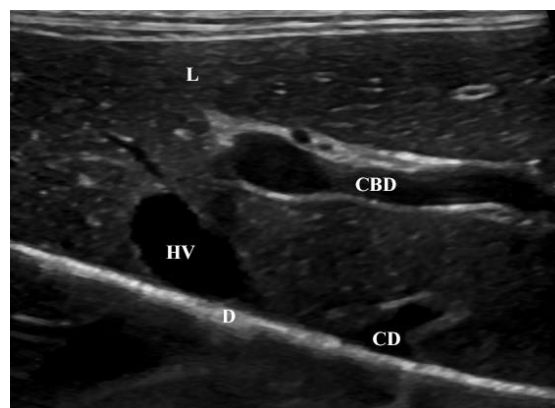
### *Description of the Method*

Ultrasonography of these dogs were obtained from dorsoventral, and left and right lateral recumbency and in the inspiration phase of the animal's breathing to obtain the best view of the cystic duct in the gallbladder level and the common bile duct in the porta hepatis and major duodenal papilla levels in the sagittal axes (Figure 1). The measurement of the diameter of each of these ducts was repeated three times and the obtained values were entered in the

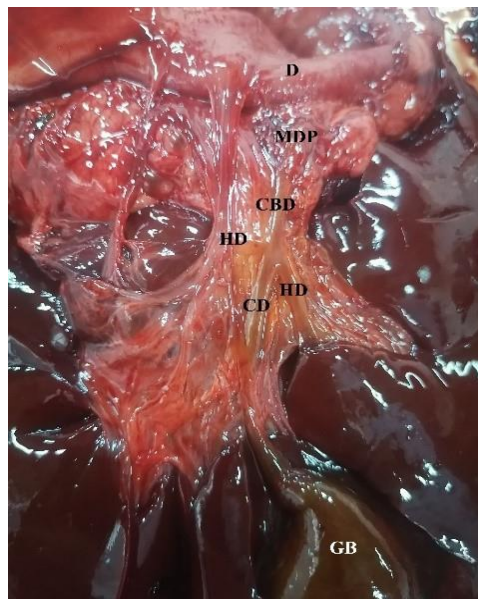
respective tables. All ultrasounds were performed under the direct supervision of a veterinary radiologist. The ultrasound machine used for color Doppler ultrasonography was EUB-525, Hitachi, Japan and multi-frequency probes convex 8-12 MHz. Anatomical studies were performed following anesthesia and during surgery. For this purpose, pre-anesthesia was performed by injecting Acepromazine 2% (0.2 mg/kg) intramuscularly, and 20 minutes later, sequence anesthesia was induced by intravenous sodium thiopental 2.5% (10 mg/kg). Anesthesia was maintained with a mixture of 1–1.5% halothane-oxygen in the closed system of the inhalation anesthesia machine. After preparing the surgical region and incision in the midline of the abdomen, the gallbladder, cystic duct, hepatic ducts and common bile duct were examined and measured based on their topographical position (Figure 2). Following surgery and anatomical studies, the laparotomy incision was closed in the conventional method and post-surgery care was performed.

### *Statistical Analysis*

Data were analyzed with t-test and SPSS 11.5 software. All values were expressed as the mean and standard deviation (mean  $\pm$  SD), and the value of  $p \leq 0.05$  was used as statistical significance. All data presented are three replicates.



**Figure 1:** Sagittal sonogram of the bile ducts of a 3-year-old male German shepherd dog. Liver (L), common bile duct (CBD), hepatic vein (HV), cystic duct (CD), diaphragm (D).



**Figure 2:** Anatomy of the liver bile ducts of the same German shepherd dog. Duodenum (D), major duodenal papilla (MDP), common bile duct (CBD), hepatic duct (HD), cystic duct (CD), gallbladder (GB).

## RESULTS

According to the results of this study, the average diameter of the cystic duct in gallbladder level was  $4.17 \pm 0.58$  mm, and the mean diameter of the common bile duct in the hepatis porta and major duodenal papilla levels was  $3.23 \pm 0.48$  and  $3.14 \pm 0.63$  mm, respectively (Table 1). Also, the average of these statistical indices in the anatomy examination was  $4.36 \pm 0.72$ ,  $3.27 \pm 0.55$ , and  $3.27 \pm 0.58$  mm, respectively (Table 2).

In Table 3, the statistical Parameters of ultrasonography and anatomy are listed according to gender. The results show that the diameter of the cystic duct in the gallbladder level is greater in males than in females, and the mean diameter of the common bile duct in the hepatis porta and major duodenal papilla levels is larger in females than in males, but these differences are not significant ( $p > 0.05$ ).

**Table 1.** The mean diameter of the cystic duct in gallbladder level and the mean diameter of the common bile duct in the hepatis porta and major duodenal papilla levels in German Shepherd dogs by ultrasonography (mm).

Dog	Cystic duct in GB level	Common bile duct in HP level	Common bile duct in MPD level
1	$4.14 \pm 0.49$	$3.34 \pm 0.29$	$3.12 \pm 0.22$
2	$4.22 \pm 0.47$	$3.12 \pm 0.30$	$3.04 \pm 0.24$
3	$4.15 \pm 0.31$	$3.41 \pm 0.32$	$3.34 \pm 0.25$
4	$4.04 \pm 0.44$	$3.15 \pm 0.23$	$3.11 \pm 0.27$
5	$4.12 \pm 0.38$	$3.22 \pm 0.15$	$3.19 \pm 0.25$
6	$4.29 \pm 0.45$	$3.19 \pm 0.29$	$3.12 \pm 0.36$
Mean female	$4.16 \pm 0.51$	$3.24 \pm 0.39$	$3.15 \pm 0.45$
7	$4.25 \pm 0.40$	$2.95 \pm 0.15$	$2.90 \pm 0.29$
8	$4.19 \pm 0.39$	$3.18 \pm 0.28$	$3.14 \pm 0.15$
9	$4.15 \pm 0.45$	$3.45 \pm 0.19$	$3.29 \pm 0.45$
10	$4.14 \pm 0.33$	$3.34 \pm 0.36$	$3.15 \pm 0.25$
11	$4.14 \pm 0.29$	$3.28 \pm 0.25$	$3.20 \pm 0.33$
12	$4.25 \pm 0.35$	$3.19 \pm 0.29$	$3.11 \pm 0.39$
Mean male	$4.18 \pm 0.53$	$3.21 \pm 0.42$	$3.13 \pm 0.56$
Total	$4.17 \pm 0.58$	$3.23 \pm 0.48$	$3.14 \pm 0.63$

$p \leq 0.05$  is considered significant and the confidence limit is 95%.

**Table 2.** The mean diameter of the cystic duct in gallbladder level and the mean diameter of the common bile duct in the hepatis porta and major duodenal papilla levels in German Shepherd dogs in anatomical examination (mm).

Dog	Cystic duct in GB level	Common bile duct in HP level	Common bile duct in MPD level
1	4.03 ± 0.24	3.27 ± 0.25	3.25 ± 0.19
2	4.31 ± 0.53	3.22 ± 0.27	3.24 ± 0.21
3	4.44 ± 0.42	3.42 ± 0.30	3.25 ± 0.35
4	4.34 ± 0.19	3.26 ± 0.17	3.33 ± 0.17
5	4.27 ± 0.25	3.19 ± 0.27	3.37 ± 0.20
6	4.39 ± 0.39	3.34 ± 0.28	3.29 ± 0.28
Mean female	4.29 ± 0.65	3.28 ± 0.52	3.28 ± 0.46
7	4.55 ± 0.27	3.10 ± 0.18	3.05 ± 0.20
8	4.40 ± 0.19	3.30 ± 0.19	3.27 ± 0.24
9	4.44 ± 0.33	3.25 ± 0.29	3.22 ± 0.36
10	4.29 ± 0.24	3.23 ± 0.25	3.28 ± 0.29
11	4.49 ± 0.18	3.38 ± 0.22	3.36 ± 0.29
12	4.41 ± 0.32	3.29 ± 0.30	3.39 ± 0.31
Mean male	4.43 ± 0.45	3.25 ± 0.39	3.26 ± 0.54
Total	4.36 ± 0.72	3.27 ± 0.55	3.27 ± 0.58

$p \leq 0.05$  is considered significant and the confidence limit is 95%.

**Table 3.** The statistical indices of ultrasonography and anatomy according to gender.

Measurement criteria	Gender	Minimum		Maximum		Mean ± SD	
		Sonography	Anatomy	Sonography	Anatomy	Sonography	Anatomy
Cystic duct in GB level	Female	4.04	4.03	4.29	4.44	4.16 ± 0.51	4.29 ± 0.65
	Male	4.14	4.29	4.25	4.55	4.18 ± 0.53	4.43 ± 0.45
Common bile duct in HP level	Female	3.12	3.19	3.36	3.42	3.24 ± 0.39	3.28 ± 0.52
	Male	2.95	3.10	3.45	3.38	3.21 ± 0.42	3.25 ± 0.39
Common bile duct in MPD level	Female	3.04	3.24	3.34	3.37	3.15 ± 0.45	3.28 ± 0.46
	Male	2.90	3.05	3.29	3.39	3.13 ± 0.56	3.26 ± 0.54

$p \leq 0.05$  is considered significant and the confidence limit is 95%.

## DISCUSSION

In veterinary medicine, ultrasound is a useful diagnostic method to evaluate the biliary system [13]. Since quick and definitive diagnosis of liver-biliary diseases in animals is particularly important, ultrasound method can be prioritized as an accessible, inexpensive and non-invasive diagnostic method. Also, in most cases, there is no need to prescribe sedatives when using this method. In the present study, the diameter of the extrabiliary ducts of healthy adult German Shepherd dogs was measured by ultrasonography method, that the mean diameter of the cystic duct in gallbladder level was  $4.17 \pm 0.58$  mm, and the mean diameter of the common bile duct in the hepatis porta and major duodenal papilla levels were  $3.23 \pm 0.48$  and  $3.14 \pm 0.63$  mm, respectively. The diameter of

the cystic duct in the gallbladder level is greater in males than in females, and the mean diameter of the common bile duct in the hepatis porta and major duodenal papilla levels is larger in females than in males, but these differences are not significant ( $p > 0.05$ ). In previous studies, the normal range of common bile duct diameter in dogs was reported to be 3 mm, which cannot be a specific and reliable measure for different dog breeds [15]. Also, in most studies related to measuring the diameter of the common bile duct, there is no report about measuring the diameter of these ducts in their different parts, while in terms of anatomy, the diameter of these ducts in their proximal and distal parts can be different [16]. Kanai et al. (2022) investigated 47 dogs of different breeds who had hepatobiliary diseases and announced that these types of diseases increase the diameter of the bile ducts, which ultrasound can be a useful

method for their diagnosis [17]. Lee et al. (2014) by measuring the diameter of the bile ducts of 200 dogs of different breeds announced that in 121 dogs the diameter of these ducts was the same and more than 8 mm. Of course, the main purpose of the aforementioned survey was not to obtain the diameter of these ducts, and the method and place of its measurement were not explained [18]. The results of our study show that the diameter of the cystic duct in the gallbladder level is greater in males than in females, and the mean diameter of the common bile duct in the hepatis porta and major duodenal papilla levels is larger in females than in males, but these differences are not significant. All these measurements were repeated three times. The size of these ducts changed during the inspiration and expiration phase of the dogs, so that sometimes this size difference reached more than 1 mm, so in order to obtain a standard value of the diameter of these ducts, we tried to perform these measurements in the inspiration phase of the dogs and note down the maximum diameter taken in each examination. In some studies, the diameter of the bile ducts has been reported to be more than the results of our research, which is probably due to the measurement method [16, 19]. The measurement method is important because in the deep inspiration phase of some dogs, the duct diameter was increased by about 1 mm and in most cases the diameter of these ducts was larger in their distal part. Hill et al. (2022) reported an increase in the diameter of the bile ducts by examining dogs with cholestasis, but they did not specify the age range of the dogs in this research, while the age range can be important in evaluating the diameter of these ducts [20]. In our study, the mean weight of the dogs were  $24.37 \pm 3.65$  kg and the mean age of  $2.40 \pm 0.495$  years and have been reported the results obtained from the normal diameter of the bile ducts in this age and weight range. Marvel and Monnet (2014)

conducted a necroscopic study on the liver of large breed dogs and reported the diameter of the cystic duct in this type of dogs to be more than 6 mm [21]. In the present study, we investigated the diameter of the cystic duct in German shepherd dogs by both ultrasound and anatomical methods and based on the results obtained, the diameter of this duct was the same in both methods. Therefore, examining the diameter of these ducts by ultrasonography method in clinical evaluations of dogs suffering from hepatobiliary diseases with high confidence limits (95%) can be useful and practical. Park et al. (2018) reported that the diameter of the common bile duct in normal beagle dogs weighing less than 15 kg was more than 3 mm and 3.5 mm at the hepatis porta and duodenal papilla levels, respectively [8]. Also, they stated that Ultrasonography is a useful modality in the estimation of gallbladder volume because ejection fraction and common bile duct diameter from ultrasonography were not significantly different from those of anatomical examination. These results are consistent with our study.

## CONCLUSION

In conclusion, the precise standards acquired in this study can be utilized to interpret the findings and clinical decisions about the normal and abnormal size of the diameter of the cystic and the common bile duct in adult German shepherd dogs.

## ACKNOWLEDGMENTS

The authors thank the Vice Chancellor for Research of Islamic Azad University of Urmia for financial supports (Protocol Code: 4/39822). This article is the outcome of DVM thesis.

## ETHICS

Approved.

## CONFLICT OF INTEREST

The authors declare that there is no conflict of interest.

## REFERENCES

- [1] Neer TM. A review of disorders of the gallbladder and extrahepatic biliary tract in the dog and cat. *Journal of Veterinary Internal Medicine*. 1992; 6(3): 186-92. **doi:10.1111/j.1939-1676.1992.tb00335.x.**
- [2] Bruyette D. *Clinical Small Animal Internal Medicine*: John Wiley & Sons. 2020. **doi:10.1002/9781119501237.ch9.**
- [3] Malik MY, Jaiswal S, Sharma A, Shukla M, Lal J. Role of enterohepatic recirculation in drug disposition: cooperation and complications. *Drug metabolism reviews*. 2016; 48(2): 281-327. **doi:10.3109/03602532.2016.1157600.**
- [4] Flanagan J, Bissot T, Hours MA, Moreno B, Feugier A, German AJ. Success of a weight loss plan for overweight dogs: The results of an international weight loss study. *PLoS One*. 2017; 12(9): e0184199. **doi:10.1371/journal.pone.0184199.**
- [5] Morelli G, Bastianello S, Catellani P, Ricci R. Raw meat-based diets for dogs: survey of owners' motivations, attitudes and practices. *BMC Veterinary Research*. 2019; 15: 1-10. **doi:10.1186/s12917-019-1824-x.**
- [6] Scott JP, Fuller JL. *Genetics and the Social Behavior of the Dog*. University of Chicago Press. 2012.
- [7] Zeman R, Taylor K, Rosenfield A, Schwartz A, Gold J. Acute experimental biliary obstruction in the dog: sonographic findings and clinical implications. *American Journal of Roentgenology*. 2020; 136(5): 965-7. **doi:10.2214/ajr.136.5.965.**
- [8] Park HY, Cho YG, Lee YW, Choi HJ. Evaluation of gallbladder and common bile duct size and appearance by computed tomography in dogs. *Journal of Veterinary Science*. 2018; 19(5): 653-9. **doi:10.4142/jvs.2018.19.5.653.**
- [9] Koh R. Improve Seizure Control with Integrative Medicine *World Small Animal Veterinary Association Congress Proceedings*. 2018.
- [10] Rahmani V, Spillmann T, Halttunen J, Syrjä P, Ruohoniemi M. Diagnostic value of endoscopic retrograde cholangiopancreatography and therapeutic value of endoscopic sphincterotomy in dogs with suspected hepatobiliary disorders. *BMC Veterinary Research*. 2022; 18(1): 1-15. **doi:10.1186/s12917-022-03241-4.**
- [11] Meomartino L, Greco A, Di Giancamillo M, Brunetti A, Gnudi G. Imaging techniques in Veterinary Medicine. Part I: Radiography and Ultrasonography. *European Journal of Radiology Open*. 2021; 8:100382.
- [12] Köster L, Shell L, Illanes O, Lathroum C, Neuville K, Ketzis J. Percutaneous ultrasound-guided cholecystocentesis and bile analysis for the detection of *Platynosomum spp.*-induced cholangitis in cats. *Journal of Veterinary Internal Medicine*. 2016; 30(3): 787-93.
- [13] Assawarachan SN, Chuchalermporn P, Maneesaay P, Thengchaisri N. Evaluation of hepatobiliary ultrasound scores in healthy dogs and dogs with liver diseases. *Veterinary World*. 2019; 12(8): 1266. **doi:10.14202/vetworld.2019.1266-1272.**
- [14] Väättäjä HK, Pesonen EK. Ethical issues and guidelines when conducting HCI studies with animals. *CHI'13 Extended Abstracts on Human Factors in Computing Systems*. 2013; 2159-68.
- [15] Berent A, Weisse C, Schattner M, Gerdes H, Chapman P, Kochman M. Initial experience with endoscopic retrograde cholangiography and endoscopic retrograde biliary stenting for treatment of extrahepatic bile duct obstruction in dogs. *Journal of the American Veterinary Medical Association*. 2015; 246(4): 436-46. **doi:10.2460/javma.246.4.436.**
- [16] Yoo ES, Yoo BM, Kim JH, Hwang JC, Yang MJ, Lee KM. Evaluation of risk factors for recurrent primary common bile duct stone in patients with cholecystectomy. *Scandinavian Journal of Gastroenterology*. 2018; 53(4): 466-70.
- [17] Kanai H, Minamoto T, Nukaya A, Kondo M, Aso T, Fujii A. Intraoperative cholangiography and bile duct flushing in 47 dogs receiving laparoscopic cholecystectomy

- for benign gallbladder disease: A retrospective analysis. *Veterinary Surgery*. 2022; 51: O150-O9. **doi:10.1111/vsu.13731.**
- [18] Lee SS, Song TJ, Joo M, Park DH, Seo DW, Lee SK. Histological changes in the bile duct after long-term placement of a fully covered self-expandable metal stent within a common bile duct: a canine study. *Clinical Endoscopy*. 2014; 47(1): 84-93. **doi:10.5946/ce.2014.47.1.84.**
- [19] Mattolini M, Citi S, Gianni B, Carozzi G, Caleri E, Puccinelli C. CT features of divisional bile ducts in healthy Labrador Retrievers. *Veterinary Radiology & Ultrasound*. 2023. **doi:10.1111/vru.13222.**
- [20] Hill FI, Speelman J, Hui K, Nekouei O, Beczkowski P, Barrs V. High frequency of cholecystitis in dogs with gallbladder mucocoele in Hong Kong. *Veterinary Journal*. 2022; 287: 105881. **doi:10.2139/ssrn.4017418.**
- [21] Marvel S, Monnet, E. Use of a vessel sealant device for cystic duct ligation in the dog. *Veterinary Surgery*. 2014; 43(8): 983-7. **doi:10.1111/j.1532-950X.2014.12274.x.**