



Case Report

An ovarian fibrosarcoma in a Rabbit

Hesam Savadkoohi <sup>1</sup>, Farshid Khorshidi <sup>2</sup>, Alireza Salehi <sup>2</sup>, Seyed Mohammad Hosseini <sup>2\*</sup>

<sup>1</sup> Department of Clinical Sciences, Faculty of Veterinary Medicine, Babol Branch, Islamic Azad University, Babol, Iran

<sup>2</sup> Department of Pathology, Faculty of Veterinary Medicine, Babol Branch, Islamic Azad University, Babol, Iran

ARTICLE INFO

Received: 04 March 2023

Accepted: 01 August 2023

DOI: 10.30495/jbcvm.2023.1981673.1041

ABSTRACT

Fibrosarcoma is a deadly tumor rarely derived from fibrous connective tissue. A 3.5-year-old rabbit was referred to the veterinary clinic due to anorexia. After the examination, an ultrasound of the abdominal area was performed, which showed evidence of a tumor. The case was subsequently referred to radiography to investigate for any metastasis. After that, surgery was performed to remove the tumor mass from the ovaries and uterus, which weighed 120 grams. After taking a tissue sample and fixating it in a 10% buffered formalin buffer solution, it was referred to the pathology laboratory. The tissue was processed, sliced into 5-micron sections, and stained with Hematoxylin and Eosin as well as Masson's trichrome staining. Our findings showed malignant changes such as spindle-shaped cells with unusual nuclei and mitotic figures, random growth patterns, and collagen fibers in all directions, in addition to the infiltration of inflammatory cells. Finally, the sample was diagnosed as fibrosarcoma. It should be noticed that regarding this tumor type, surgery is the recommended approach. However, if surgery is not possible, radiotherapy and chemotherapy can also be used. Same as this case, even after successful surgery, the animal should be monitored due to the possibility of recurrence. It should be noted that after 7 months, the animal's condition was reported to be good.

KEYWORDS :

Malignant  
Fibrosarcoma  
Tumor  
Ovary  
Rabbit

فیبروسارکوم تخمدان در یک رأس خرگوش

حسام سوادکوهی <sup>۱</sup>، فرشید خورشیدی <sup>۲</sup>، علیرضا صالحی <sup>۲</sup>، سید محمد حسینی <sup>۲\*</sup>

<sup>۱</sup> گروه علوم درمانگاهی، دانشکده دامپزشکی، واحد بابل، دانشگاه آزاد اسلامی، بابل، ایران

<sup>۲</sup> گروه پاتولوژی، دانشکده دامپزشکی، واحد بابل، دانشگاه آزاد اسلامی، بابل، ایران

چکیده

فیبروسارکوم یک تومور نادر کشنده بوده که از بافت همبند فیبروزی مشتق می شود. یک خرگوش ۳.۵ ساله به دلیل بی اشتها به کلینیک دامپزشکی ارجاع شد. پس از معاینه، سونوگرافی از ناحیه شکم انجام شد که شواهدی از وجود تومور را نشان داد. پس از آن به رادیوگرافی ارجاع داده شد تا از نظر وجود تومور بررسی شود. سپس، عمل جراحی برای برداشتن توده تومور از تخمدان ها و رحم که ۱۲۰ گرم وزن داشت، انجام شد. نمونه پس از اخذ و ثبوت در محلول بافر فرمالین ۱۰ درصد، به آزمایشگاه پاتولوژی ارجاع داده شد. مقاطع بافتی با ضخامت ۵ میکرومتر برش داده شد و با روش های هماتوکسیلین-انوزین و تریکروم ماسون رنگ آمیزی شد. یافته های ما تغییرات بدخیم مانند سلول های دوکی شکل با هسته ها و شکل های میتوزی غیرمعمول، الگوهای رشد تصادفی و رشته های کلاژن در همه جهات و همچنین نفوذ سلول های التهابی را نشان داد. در نهایت، نمونه به عنوان فیبروسارکوم تشخیص داده شد. لازم به ذکر است که در مورد این نوع تومور، جراحی توصیه می شود اما اگر جراحی امکان پذیر نبود، می توان از رادیوتراپی و شیمی درمانی نیز استفاده کرد. حتی پس از یک عمل جراحی موفقیت آمیز، به دلیل احتمال عود، حیوان باید تحت نظر باشد. لازم به ذکر است پس از ۷ ماه حال این حیوان، خوب گزارش شد.

واژه های کلیدی: بدخیم، فیبروسارکوم، تومور، تخمدان، خرگوش

\* Corresponding author: dr.m.hosseini2323@gmail.com

©2023 Islamic Azad University, Urmia Branch. All rights reserved.

This work is licensed under a [Creative Commons Attribution 4.0 International License](https://creativecommons.org/licenses/by/4.0/).



## INTRODUCTION

Fibrosarcoma is a malignant tumor that arises from fibroblasts, which are cells that produce connective tissue. This type of cancer can occur in various parts of the body, including bones, soft tissues, and organs. Fibrosarcoma is a rare cancer, accounting for less than 1% of all cancers. In addition, ovarian fibrosarcoma is an extremely rare condition in rabbits. It can be said that there is no solid evidence of this type of cancer in the literature yet. However, several fibrosarcoma case studies were reported for other tissues, such as the interscapular and oral [1,2]. Fibrosarcoma is a malignant type of neoplasm that rarely occurs and is composed of spindle-shaped fibroblasts with a high mitosis index and collagen production. The number of cases diagnosed with fibrosarcoma has been reduced over the past years due to some changes in the soft tissue tumor classification, differentiation of subtypes of fibrosarcoma, and increasing knowledge about many other mesenchymal and non-mesenchymal tumors that look like fibrosarcoma [3,4]. They are commonly observed in deep soft tissue or next to the bones. Fibrosarcoma is rarely derived from the cutis. More accurately, the tendons and fascia of deep soft tissues are more common places. While fibrosarcoma can occur in any part of the body, it can develop inside the bones as a main or second tumor [3,5]. A tumor is a mass of tissue that does not serve any physiological function and might be benign or malignant. Cancer is defined as a malignant disease caused by unregulated cell division in the body, which results in the formation of a mass of tissue. These cells have the potential to infiltrate neighboring or adjoining organs or expand to distant places, where they can continue to grow uncontrollably and cause serious lesions or death. It should be noted that not all tumors or inflammations are malignant,

such as benign tumors, which are not classified as carcinogenic because they don't spread to other regions [6]. Based on the level of differentiation, there are three groups of tumor cells: one low grade (differentiated), two intermediate malignancies, and three high malignancies (anaplastic). In most cases, fibrosarcoma occurs in the mouth and is locally invasive. This tumor often comes back after surgery in dogs. Fibrosarcoma is the tumor that happens often in adults and older cats and dogs [7]. Two main types of fibrosarcoma are likely to be seen: the infantile-congenital type of fibrosarcoma, which is an intermediate malignant tumor that barely metastasizes, and the adult-type fibrosarcoma, which is a highly malignant tumor [3]. Previous studies demonstrated that animals with benign tumors were younger than those with malignant tumors [8]. Fibrosarcoma in rabbits is also a rare condition, but it is more common than in other species. This type of cancer typically affects the skin, but it can also occur in other tissues, such as muscle and bone. The exact cause of fibrosarcoma in rabbits is unknown, but it is believed to be related to genetic and environmental factors. As was observed in an earlier study, in this case, the treatment was nearly impossible and the survival chance was low, so the prognosis was very poor [9]. Consequently, aggressive surgical excision was chosen as the main therapeutic approach [10].

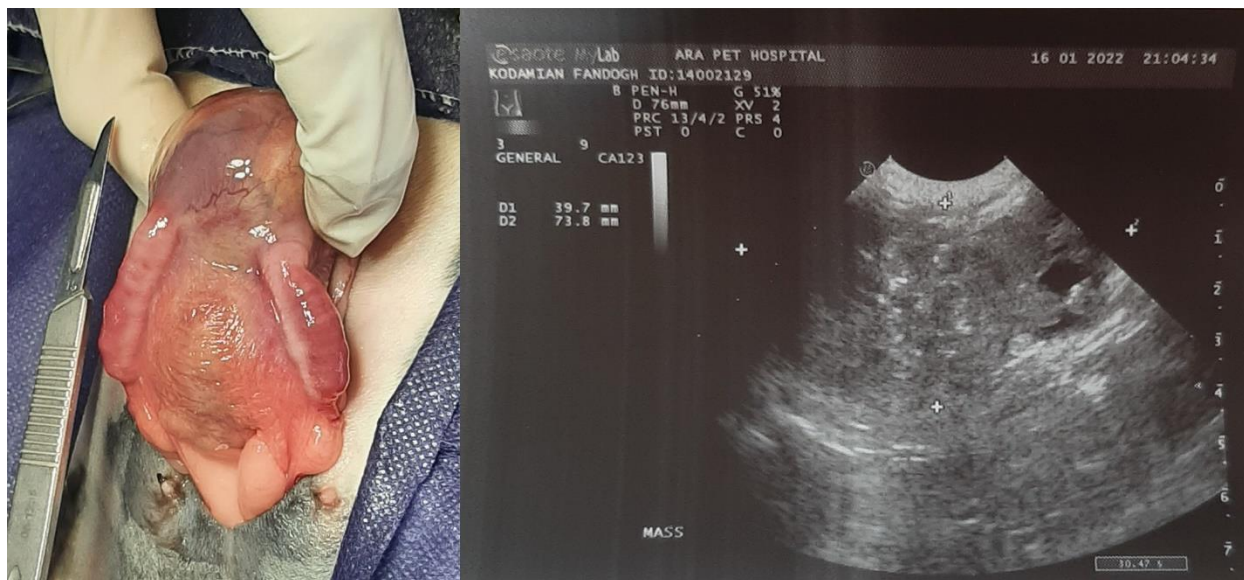
## CASE PRESENTATION

A 3.5-year-old female rabbit was referred to the veterinary clinic on January 2022, with symptoms of anorexia and chronic weight loss. Surprisingly, it gained 200 grams in the last 10 days. After the clinical examination, an ultrasound of the animal's abdomen was conducted to focus on the urogenital system.

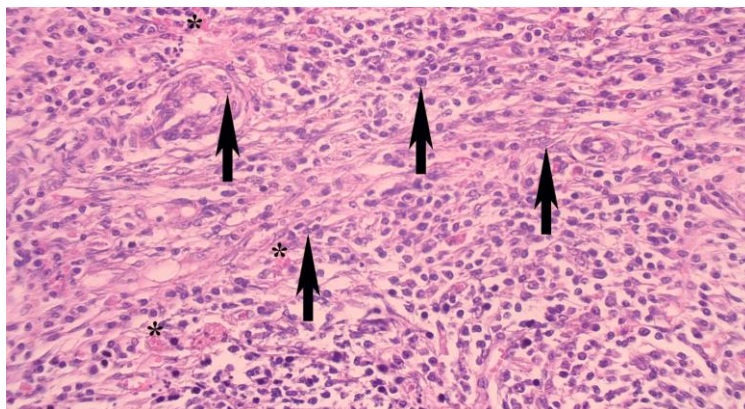
The size of the left ovary was reported to be 6.2 mm. The body of the uterus was swollen to a maximum size of 1.4 cm. A well-defined hypoechoic mass with abnormal margins containing fluid was observed on the left side, measuring  $7.3 \times 3.9$  cm. It should be noted that the blood pressure was low. Radiography was also performed, which revealed a tumor-like mass, which was analyzed after surgery (Figure 1). So, tumor removal surgery was performed in addition to the Ovariohysterectomy (OHE), and no metastatic lesion was observed.

### *Pathological findings*


The weight of the tumor was 120 grams. After taking a tissue sample, it was fixed in 10% neutral buffered formalin. The sample was processed in a tissue processor, and then a paraffin block was prepared, and a 5-micron tissue section was stained with hematoxylin-eosin. The section was examined by a light microscope. Histopathological findings showed spindle cells with atypical nuclei, a haphazard growth pattern, mitotic figures, and hyperemia (Figure 2). Moreover, Masson's trichrome stain was performed to highlight collagen fibers, which differentiate the collagen and muscle fibers on tumor tissue (Figure 3).



**Figure 1.** Tumor mass removed surgically (Left image). A large well-defined mass-like lesion with irregular margins was observed in ultrasonography (Right image).



**Figure 2.** Malignant changes. Mitosis (arrow) and hyperemia (asterisk) are shown.



**Figure 3.** Ovarian fibrosarcoma. Interlacing bundles of fibroblast-type neoplastic cells and considerable collagen bundles that were synthesized by tumor cells are shown. Masson's Trichrome.  $\times 40$ .

## DISCUSSION

Cancer can affect both humans and animals. Tobacco use, obesity, poor nutrition, a lack of physical exercise, and alcohol are all common cancer risk factors in humans [6]. Numerous studies about the microscopic characteristics of smooth muscle tumors have been conducted over the last two decades [11,12]. However, almost no similar research has been conducted on ovarian fibromatous tumors in rabbits, of which the majority include fibrosarcoma [13]. Uterine adenocarcinoma, lymphoma (sometimes disseminated), and thymoma were the most common tumor types found in Bertram's necropsy cases in rabbits between 2018-2021 [14,15]. Briefly, skin, mammary glands, and testicular tumors were reported on occasion.

In this study, the tumor tissue consisted of spindle-shaped cancerous cells in herringbone patterns or interlacing bundles. They went through cellular pleomorphism and turned into oval or round shapes, with slightly hyperchromatic cores and plenty of eosinophilic cytoplasm [5]. Unclear cell borders and abnormal mitotic figures and nuclei were also observed [16]. The intact sections had dense cellularity and low to moderate collagen synthesis [13].

Usually, ovarian fibrosarcoma is assumed to have developed independently or as a result of a benign fibroma transformation [17]. Due to its aggressive characteristics, adult-type fibrosarcoma has a low overall survival rate [3].

Regarding fibrosarcoma, the amount of nuclear atypia must be an important signal for diagnosis [17]. The autopsies of pet rabbits in 2014 revealed that the mammary gland, female reproductive tract, GI tract, hematopoietic organs, skin, and testicles mostly suffered from cellular lesions [14].

## ETHICS

Approved.

## CONFLICT OF INTEREST

All authors disclose any relationships with other people or organizations that could inappropriately influence this research.

## REFERENCES

- [1] Petterino C, Modesto P, Strata D, Vascellari M, Mutinelli F, Ferrari A, et al. A case of interscapular fibrosarcoma in a dwarf rabbit (*Oryctolagus cuniculus*). *Journal of veterinary diagnostic investigation*. 2009; 21(6): 900-5.  
**doi: 10.1177/104063870902100626**
- [2] Brower M, Goldstein GS, Ziegler LE, Matise I. Spontaneous oral fibrosarcoma in a New Zealand rabbit. *Journal of Veterinary Dentistry*. 2006; 23(2): 96-9.  
**doi: 10.1177/089875640602300206**
- [3] Augsburger D, Nelson PJ, Kalinski T, Udelnow A, Knösel T, Hofstetter M, et al. Current diagnostics and treatment of fibrosarcoma—perspectives for future therapeutic targets and strategies. *Oncotarget*. 2017; 8(61): 104638.  
**doi: 10.18632/oncotarget.20136**

- [4] Folpe AL. Fibrosarcoma: a review and update. *Histopathology*. 2014; 64(1): 12-25.
- [5] Musal B, Ulutas P, Aydogan A. Vaginal fibrosarcoma in a cow. *Irish Veterinary Journal*. 2007; 60(7): 1-2. **doi:10.1111/his.12282**
- [6] Christy AO, MacDonald I, Olaposi OI. Effect of *Spondias mombin* leaves' extracts on chemically induced tumor. *Journal of Medicinal Herbs*. 2022; 13(2): 7-17. **doi: 10.30495/medherb.2022.693887**
- [7] Hesaraki S, Abedi G, Rismanchi S. Penile fibrosarcoma tumor in a bull. *Iranian Journal of Veterinary Research*. 2010; 11(3): 283-6. **doi: 10.22099/IJVR.2010.145**
- [8] Sapiernyński R, Malicka E, Bielecki W, Krawiec M, Osińska B, Sendecka H, et al. Tumors of the urogenital system in dogs and cats. Retrospective review of 138 cases. *Polish Journal of Veterinary Sciences*. 2007; 10(2): 97-103.
- [9] Huang L, Liao L-M, Wang H-Y, Zheng M. Clinicopathologic characteristics and prognostic factors of ovarian fibrosarcoma: the results of a multi-center retrospective study. *BMC cancer*. 2010; 10(1): 585.
- [10] Davis KM, Hardie EM, Lascelles BDX, Hansen B. Feline fibrosarcoma: perioperative management. *Compendium on Continuing Education for the Practicing Veterinarian*. 2007; 29(12): 712-32.
- [11] Ip PP, Tse KY, Tam KF. Uterine smooth muscle tumors other than the ordinary leiomyomas and leiomyosarcomas: a review of selected variants with emphasis on recent advances and unusual morphology that may cause concern for malignancy. *Advances in Anatomic Pathology*. 2010; 17(2): 91-112. **doi: 10.1097/PAP.0b013e3181cfb901**
- [12] Atkins KA, Arronte N, Darus CJ, Rice LW. The use of p16 in enhancing the histologic classification of uterine smooth muscle tumors. *American journal of surgical pathology*. 2008; 32(1): 98-102. **doi: 10.1097/PAS.0b013e3181574d1e**
- [13] Prat J, Scully RE. Cellular fibromas and fibrosarcomas of the ovary: a comparative clinicopathologic analysis of seventeen cases. *Cancer*. 1981; 47(11): 2663-70. **doi:10.1002/10970142(19810601)47:11<2663::aid-cnrcr2820471124>3.0.co;2-v**
- [14] Bertram CA, Bertram B, Bartel A, Ewringmann A, Fragoso-Garcia MA, Erickson NA, et al. Neoplasia and tumor-like lesions in pet rabbits (*Oryctolagus cuniculus*): a retrospective analysis of cases between 1995 and 2019. *Veterinary Pathology*. 2021; 58(5): 901-11. **doi: 10.1177/0300985820973460**
- [15] Bertram C, Müller K, Klopffleisch R. Genital tract pathology in female pet rabbits (*Oryctolagus cuniculus*): a retrospective study of 854 necropsy examinations and 152 biopsy samples. *Journal of Comparative Pathology*. 2018; 164: 17-26. **doi: 10.1016/j.jcpa.2018.08.003**
- [16] Ray S, Biswas BK, Mukhopadhyay S. Giant primary ovarian fibrosarcoma: Case report and review of pitfalls. *Journal of Cytology*. 2012; 29(4): 255. **doi: 10.4103/0970-9371.103946**
- [17] Zhang Z, Yao A, Xin Q, Shi Y, Zhang A. Nuclear atypia is a necessary factor for diagnosis of primary ovarian fibrosarcoma: a case report and literature review. *Gynecologic and Obstetric Investigation*. 2020; 85(5): 437-45. **doi: 10.1159/000510875**