

Original Article

The Evaluation of Thyroid Gland Volume in the Foals by Ultrasonography

Siamak Alizadeh^{1*}, Arash Araghi-Sooreh¹, Kaveh Azimzadeh¹

¹ Department of Clinical Sciences, Faculty of veterinary medicine, Urmia Branch, Islamic Azad University, Urmia, Iran

ARTICLE INFO

Received: 6 September 2017

Accepted: 8 November 2017

KEYWORDS:

Ultrasonography

Foal

Volume of the thyroid gland

ABSTRACT

Ultrasonography of the thyroid gland is a non-invasive method for evaluating its size, which can be used to examine the initial increase in the volume of the gland in live foals. In this study, the ultrasonography, as a standard method, was used to measure the extent of the thyroid gland. For this purpose, 14 Kurdish foals were selected which the age of those was between 2 and 90 days. In each of the foals, the size of the thyroid gland was measured with ultrasonographic method of three standardized axes and total volume (VSON) was calculated using the formula for an ellipsoid body. Variability of ultrasonographic measurements was dependent on side and axis, and ranged between 3.04-7.35 percent. The relationship between body weight and thyroid volume was significant. Generally, the thyroid size of the foals can be calculated by evaluating ultrasonography in three axes and comparing with predicted values based on body weight.

ارزیابی حجم غده تیروئید کره اسب ها با استفاده از اولتراسونوگرافی

سیامک علیزاده^{۱*}، آرش عراقی سوره^۱، کاوه عظیمزاده^۱

^۱ گروه علوم درمانگاهی، دانشکده دامپزشکی، واحد ارومیه، دانشگاه آزاد اسلامی، ارومیه، ایران

چکیده

اولتراسونوگرافی از غده تیروئید برای ارزیابی اندازه آن یک روش غیر تهاجمی بوده که می توان به وسیله آن افزایش اولیه در حجم این غده را در کره اسب های زنده بررسی کرد. در این تحقیق سعی بر آن شد که یک روش استاندارد برای ارزیابی اندازه غده تیروئید با استفاده از اولتراسونوگرافی به دست آوریم. برای این منظور ۱۴ کره اسب از نژاد کردی که سن آنها بین ۲ تا ۹۰ روز بود انتخاب شدند. در هر یک از این کره ها اندازه غده تیروئید به روش اولترا سونوگرافی در سه محور استاندارد اندازه گیری گردید و حجم غده تیروئید با استفاده از فرمولی که برای اعضای بیضی شکل تعریف شده است محاسبه گردید. (VSON) تغییر پذیری اندازه های اولتراسونوگرافی وابسته به سمت و محور بوده و در محدوده ۷/۳۵ - ۳/۰۴ درصد بود. ارتباط بین وزن بدن و اندازه تیروئید معنی دار بود. بطور کلی اندازه تیروئید کره اسب ها را می توان با ارزیابی اولتراسونوگرافیک در سه محور و مقایسه با مقادیر پیش بینی شده بر اساس وزن بدن محاسبه کرد.

واژه های کلیدی: اولتراسونوگرافی، کره اسب، حجم غده تیروئید

* Corresponding author: s_alizadeh01@yahoo.com

©2019 Islamic Azad University, Urmia Branch.

This work is licensed under a [Creative Commons Attribution 4.0 International License](https://creativecommons.org/licenses/by/4.0/).



INTRODUCTION

Iodine deficiency is seen in some areas of the soil, especially in areas that are far from the shores of the sea, and foals are born in those areas and fed forage from these soils, suffer from thyroid gland disorders such as goiter. In closed breeding systems that use a balanced diet, these deficiencies are eliminated by adding minerals and nutrients into the diet [1]. In some cases, selenium deficiency can also lead to iodine deficiency [2]. Secondary deficiency of iodine is observed in cases such as high calcium diet, contamination of drinking water with a variety of bacteria and nutrition with plants that cause goiter (white clover, rapeseed, etc.) [3]. In cases of suspected iodine deficiency, the concentration of iodine or thyroxine (T4) and triiodothyronine (T3) can be evaluated. However, serum concentrations of T3 and T4 in the evaluation of newborn foals cannot be reliable because they have normal or moderate changes in the four weeks after birth. The T3/T4 ratio seems to be more reliable [4]. But in horses with no clinical symptoms, the ratio between diseased ones and healthy ones is not different. In addition, the costs of these types of trials are high and subclinical forms of this disease cannot be detected [5]. In recent decades, iodine deficiency mediated goiter has been reported frequently in food and congenital mediated goiter in veterinary clinics [6]. Goiter is a non-specific term used to describe the enlargement of the thyroid gland [7]. In terms of pathology, the size of the thyroid gland is based on weight [8]. There is a lot of association between the weight and volume of the tissues [9]. Therefore, measuring the volume of tissues by ultrasonography is a known method for detecting changes in the size of the thyroid gland in humans and small animals [10]. The ultrasonography of the thyroid gland is a non-

invasive method for assessing its size, which can be used to examine the initial increase in the volume of this gland in live horses. There is little information about the thyroid gland ultrasound in the horses. Considering the increasing use of ultrasound in diagnosis of thyroid diseases and the accuracy of this method in determining the thyroid volume for radiologist, it is necessary first to determine the normal thyroid volume and the physiological variables (such as age, sex, and body weight). The volume of the gland in the horses are well known to distinguish pathological cases from normal ones. In addition to the above factors, the amount of daily iodine, genetic background, and body surface area affect the amount of normal thyroid volume in this animal. The determination of thyroid volume by ultrasonography, due to availability, cost, noninvasiveness, and high reliability of the above diagnostic method as well as the possibility of performing it in all age groups is preferred to other diagnostics methods such as radioisotope scan that radioactive iodine. In about 30% of cases, goiter is not detected by clinical examination, but it can be better detected in ultrasonographic examination. Also, thyroid volume is significantly associated with age and especially weight [7,11].

MATERIALS AND METHODS

In this study, 14 Kurdish foals were surveyed in the Somaye Bradost region of Urmia. Each of these foals was kept by their owners and added to their diet mineral supplements containing iodine. Their weights were between 30.5-117.2kg (Mean \pm standard deviation: 58.1 \pm 19.6) and their age was between 2 and 90 days. These foals were evaluated for thyroid functional tests, especially T3 and T4 and TSH in serum, and their health was confirmed on

the basis of normal values. Five foals were female and nine were male. In each of these foals, the thyroid gland size was evaluated by ultrasonography in three standard axes.

Evaluation of thyroid gland ultrasonography:

The ultrasound device that was used for ultrasonography was EUB-8500 XP (Hitachi Medical Corporation, Tokyo, Japan) and a linear probe with a frequency of 6.5 MHz. Ultrasonography of the foals carried out in the standing position. The hair of the neck region was initially shaved and after rubbing gel on

the desired area, in the first stage a transverse plan was taken from the thyroid gland. The probe was placed perpendicular to the jugular vein and with a little pressure on the dorsocaudal of larynx trying to make the thyroid gland completely appear on the monitor. Path of beams penetration was ventrolateral-dorsolateral oblique with an angle of about 45 degrees with the middle axis. In this plane, Isthmus was visible. In this transverse plane, the axis A (width) and axis B (thickness) of the thyroid gland lobe were measured (Fig. 1). Then, to evaluate the

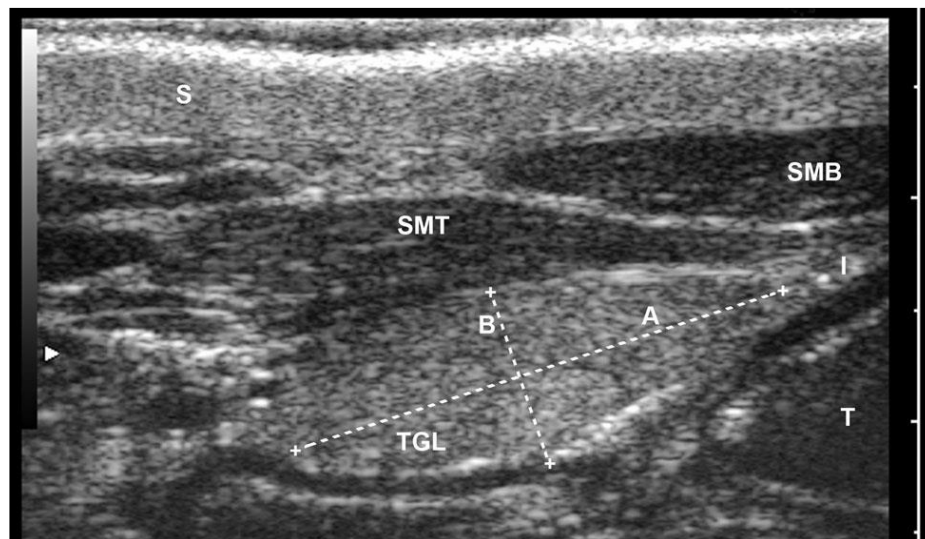


Figure 1. An ultrasonogram of the thyroid gland (left lobe) on the foal in a transverse plane. (A) Width, (B) Thickness, (I) Isthmus, (S) Skin, (T) Trachea, (TGL) Thyroid gland (lips), SMT, M. Sternocleidomastoideus pars mastoidea, SMB, M. Sternocleidomastoideus pars mandibularis. The scale between each tick is 0.5 centimeters.

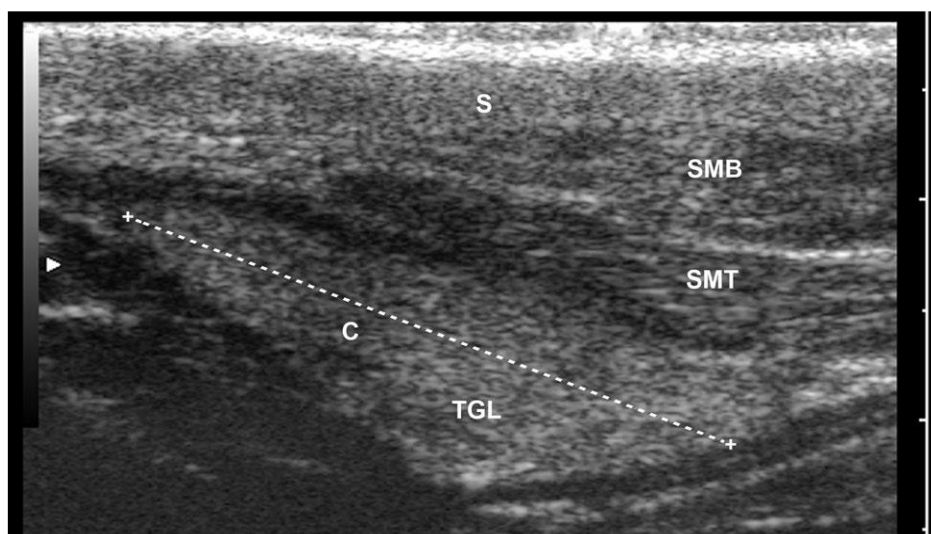


Figure 2. An ultrasonogram of the thyroid gland (right lobe) on the foal in a sagittal plan. (C) Axle length, (S) Skin, SMT, M. Sternocleidomastoideus pars mastoidea, SMB, M. Sternocleidomastoideus pars mandibularis. The scale between each tick is 0.5 centimeters.

sagittal plane, The probe was rotated 90 ° (parallel to the jugular vein) and the maximum length of the thyroid gland (axis C) was measured (Fig. 2). The same method for measuring the opposite lobe of the thyroid gland was also performed. Each study was repeated 3 times and the frozen images were saved.

Image analysis:

The size of the thyroid gland was measured using an image viewer software (Image viewer software “Version 06–01X 080204”) on a personal computer.

Statistical analysis of data:

The results of sonographic measurements were entered in the formula for the volume of an ellipsoid Body [$\text{Pi}/6 \times (\text{A} \times \text{B} \times \text{C})$, $\text{pi}=3.14159$] and by adding results for the left and right lips (Al, Bl, Cl and Ar, Br, Cr, respectively), thyroid volume was calculated for (VSON). Statistical calculations were performed using PASW software. The coefficient of variation of three repeated measurements was used as a degree of variability. Data distribution was investigated using box and whisker platforms and Q-Q plots. To compare the volume between the left and right lobes and paired t-test was used to evaluate the ultrasonography value and Pearson correlation coefficient (r)

was used for correlational evaluation. For other comparisons, t-test was used. Regression analysis was used for prediction in which the coefficient of determination (R²) was used to verify the relationship. The significance level for all tests was $\alpha < 0.05$.

RESULTS

Thyroid gland ultrasound image is characterized by a uniform echogenicity that has finely granules and the echogenicity of this gland is somewhat more than the muscle tissue around it. This gland is surrounded by thin capsule fibers. The adjacent tissues of this gland include trachea and muscles of Sternoccephalicus pars mastoidea and Sternoccephalicus pars mandibularis (Figures 1 and 2). In the transverse plan, the lobes of the thyroid gland are oval.

Dimensions determined by ultrasonography method:

No significant difference was found between the left and right lobes in the A and C axes, and the difference was less than 0.2 mm. But the difference of 0.7 mm on the B axis was significant (Table 1).

Measuring variation:

As shown in Table 1, coefficient variation (Vc) among three repeated measurements for

Table 1. Average length of the axes and correlation coefficient from three repeated measurements of ultrasonography of the thyroid gland of the horses and comparison of the obtained values by ultrasonography

All of the Foals				
Axis	Lobe	Number	Ultrasound Length(Mean ± (standard deviation))	Coefficient of variation
Width(A)	Right	14	22.1±2.5	3.89
	Left	13	22±2.7	3.21
Thickness (B)	Right	14	9.7±1.5*	7.26
	Left	13	10.4±1.7*	7.35
Length(c)	Right	12	30.1±3	3.04*
	Left	13	30±3.6	3.97*

* The values in a column between the left and right lobes with a significant difference (P < 0.05).

A and C axes was less than 4% and the highest for B axis was 7.35%.

Thyroid volume and body weight:

Volume of thyroid gland in foals by Ultrasonography:

VSON: 6.5 ± 1.7 ml (Mean \pm SD)

Significant differences ($P < 0.01$) were observed every three times when the size of a thyroid gland was measured. The mean body weight (\pm standard deviation) was 58.1 ± 19.6 . VSON and body weight were considerably high and they were 7.7 ± 2.1 ml and 64.4 ± 20.5 kg, respectively.

DISCUSSION

In this study, we tried to develop a precise method for estimating thyroid volume in a foal using ultrasonography (by determining three axes from each thyroid gland lobe). An ultrasonography of every foal takes about 5-10 minutes, which is not time consuming. Based on another study done in cattle, short axes were called thick and Long axes were called [12]. The coefficient of variation, as the repeatability for the thickness (the B axis) was the worst and for the width (axis A) and length (C axis) was quite good. In contrast, in the assessment of dogs, the length was the most variable [13]. This is probably due to the difficulty in determining the posterior end of the thyroid gland. Similar observations are found by other researchers in dogs [10]. In addition, the pressure that the probe places on the thyroid gland may cause compression and deformation of this gland which can lead to change in the length of the axis. Based on this, tried as much as possible probe pressure is lower in the topographic region of the thyroid gland. The difference between axis lengths determined by ultrasonography for axes A and C was less than 1 mm and for axis B was more than 3 mm. The use of the formula for

ellipsoid bodies underestimates both VSON and VCPR in comparison with VAQU. This is especially noticeable in the comparison between VAQU and VCPR. However, the correlation between the dependent variables VAQU and the independent variable VSON is strong.. Since the constant used in the regression model for VAQU is not significant in the ultrasonography, therefore a simplified formula for calculating volume can be used to estimate thyroid volume based on ultrasound measurements. A positive correlation between thyroid gland weight and body weight in calves is described by the normal histology of the thyroid gland [14,15].

The results of this study indicate that there is a correlation between thyroid volume and body weight. In dogs, no difference in sonographically determined thyroid volume was found between euthyroid sick and healthy dogs [10,16,17]. The difference found in the VSON between horses is the difference in body weight. Therefore, body mass must be known when thyroid volume of foals is evaluated.

CONSLUSION

The results of this study indicate that thyroid gland ultrasonography in foals can be done in a standing position. The described methods represent a precise estimate of the thyroid gland volume based on ultrasound measurement and its correlation with body weight in foals between 30 and 135 kilograms.

ETHICS

All ethical standards have been respected in this study.

CONFLICT OF INTEREST

None declared.

REFERENCES

- [1] Laiblin C, Stöber M. Stoffwechsel- und mangelbedingte Krankheitender. In: Dirksen G, Grönder H-D, Stöber M (eds). *Innere Medizin und Chirurgie des Rindes*. Stuttgart: Parey. 2006; 110–113.
- [2] Schlemmer I, Reese S, Ebert U, Metzner M. Jodmangel als Bestandsproblem in einem ökologisch geführten Milchviehbetrieb. *Tierärztl Prax*. 2008; 36: 179–184.
- [3] Radostits OM, Gay CC, Hinchcliff KW, Constable PD. Iodine deficiencies. In: Radostits OM, Gay CC, Hinchcliff KW, Constable PD (eds): *Veterinary medicine*. Edinburgh: Saunders Elsevier. 2008; 1722–1725.
- [4] Takahashi K, Takahashi E, Ducusin RJ, Tanabe S, Uzuka Y, Sarashina T. Changes in serum thyroid hormone levels in newborn calves as a diagnostic index of endemic goiter. *J Vet Med Sci*. 2001; 63: 175–178.
- [5] Randhawa CS, Randhawa SS. Epidemiology and diagnosis of subclinical iodine deficiency in crossbred horse of Punjab. *Aust Vet J*. 2001; 79: 349–351.
- [6] VanWuijckhuise L, Groeneveld AG, Couston GH, Kock P. Suffocating, slow foals with a thick neck. Iodine deficiency in horse. *Tijdschrift voor Diergeneeskunde*. 2009; 128: 348–351.
- [7] Capern CC. Thyroid gland. In: McGavin MD, Calton WW, Zachary JF (eds). *Thomson's special veterinary pathology*, 3rd ed. St. Louis: Mosby. 2005; 295–305.
- [8] Bakeer AM, Shaheed IB, El Gayed SSE, Korany RMS, and Ragaa NM. Spontaneous Pathological Affections of Thyroid Glands in Different Animal Species with Special Reference to Related Biochemical Parameters. *Egypt J Comp Path & Clinic Path*. 2012; 25 (1): 131- 147.
- [9] Paltiel HJ, Diamond DA, Di Canzio J, Zurakowski D, Borer JG, Atala A. Testicular volume: comparison of orchidometer and US measurements in dogs. *Radiology*. 2002; 222: 114–119.
- [10] Reese S, Breyer U, Deeg C, Kraft W, Kaspers B. Thyroid sonography as an effective tool to discriminate between euthyroid sick and hypothyroid dogs. *J Vet Intern Med*. 2005; 19: 491–498.
- [11] Watson PJ, Scholes SF. Congenital goitre and alopecia in pedigree Saler horse. *Vet Rec*. 2010; 166: 29–30.
- [12] Braun U, Föhn J, Pusterla N. Ultrasonographic examination of the ventral neck region in cows. *Am J Vet Res*. 1994; 55: 14–21.
- [13] Taeymans O, Duchateau L, Schreurs E, Kramer M, Daminet S, Saunders JH. Intra- and interobserver variability of ultrasonographic measurements of the thyroid gland in healthy Beagles. *Vet Radiol Ultrasound*. 2005; 46: 139–142.
- [14] Metzner M, Uebelhack S, Sauter-Louis C, Reese S, Klee W. Developing and accurate method for estimating thyroid volume in calves using ultrasonography. *Veterinary Radiology and Ultrasound*. 2014; 53:13, 301-306.
- [15] Schlemmer I, Reese S, Ebert U, Metzner M. Jodmangel als Bestandsproblem in einem ökologisch geführten Milchviehbetrieb. *Tierärztl Prax*. 2008; 36: 179–184.
- [16] Semiz S, Senol U, Bircan, Gumuslu S, Bilmen S, Bircan I. Correlation between age, body size and thyroid volume in an endemic area. *J Endocrinol Invest*. 2001; 24: 559–563.
- [17] Wisner ER, Nyland TG. Ultrasonography of the thyroid and parathyroid glands. *Vet Clin North Am Small Anim Pract*. 1998; 28: 973–991.