



## Ameliorative potentials of *Aju Mbaise* extract (AME) on Dutasteride induced oxidative stress and hepatic injury in rats

Robert Ikechukwu Uroko<sup>\*1</sup>, Ogwo Elisha Uko<sup>2</sup>, Paul Chukwemaka Nweje-Anyalow<sup>3</sup>, Obiwuru Ikenna<sup>4</sup>, Chinomso Friday Aaron<sup>4</sup>, Obinna Joseph Mba<sup>1</sup>

<sup>1</sup>Department of Biochemistry, College of Natural Sciences, Michael Okpara University of Agriculture, Umudike, Abia State, Nigeria;

\*Email: [ir.uroko@mouau.edu.ng](mailto:ir.uroko@mouau.edu.ng)

<sup>2</sup>Department of Human Physiology, College of Medicine and Health Sciences, Abia State University, Uturu, Nigeria;

<sup>3</sup>Department of Biochemistry, Faculty of Science, Clifford University, Owerinta, Abia State, Nigeria;

<sup>4</sup>Department of Biochemistry, Faculty of Biological and Physical Sciences, Abia State University, Uturu, Nigeria;

### ARTICLE INFO

**Type:** Original Research

**Topic:** Medicinal Plants

**Received:** August 16<sup>th</sup> 2022

**Accepted:** December 21<sup>st</sup> 2022

### Key words:

- ✓ *Aju Mbaise*
- ✓ Antioxidants
- ✓ Dutasteride
- ✓ Hepatic injury
- ✓ Liver markers
- ✓ Oxidative stress

### ABSTRACT

**Background & Aim:** *Aju Mbaise* is a polyherbal extract with nutraceutical properties that helps to replenish the volume of blood lost during childbirth and improves breast milk secretion and the general wellbeing of the mother. This study evaluated the ameliorative potentials of *Aju Mbaise* extract (AME) on Dutasteride-induced oxidative stress and hepatic injury in rats. Twenty-one rats were used to assess the acute toxicity of AME.

**Experimental:** The study for the hepatoprotective effects of AME had five groups of rats, including normal control, Dutasteride only, AME only, Dutasteride + AME (500 mg/kg) and Dutasteride+ AME (1000 mg/kg).

**Results:** The acute toxicity result showed that AME is relatively safe for consumption. Dutasteride caused significant elevation of liver marker enzymes, including aspartate transaminase (AST), alanine transaminase (ALT), transaminase (AST), alkaline phosphatase (ALP), total bilirubin, malondialdehyde (MDA) and significantly reduced catalase, superoxide dismutase (SOD), glutathione peroxidase (GPx), reduced glutathione (GSH), total proteins, albumin, and globulin levels in the rats received only Dutasteride. In contrast, Dutasteride induced rats treated with AME showed a significant decline in the AST, ALT, ALP, MDA, and bilirubin and significantly increased SOD, GSH, GPx, total proteins, albumin, and globulin levels compared to Dutasteride induced untreated rats. The AME-treated rats showed normal liver histo-architecture, unlike the Dutasteride-induced untreated rats that showed mild to moderate vacuolar degeneration of the hepatocytes.

**Recommended applications/industries:** The findings show that AME ameliorates Dutasteride caused rats oxidative stress and hepatic injury.

### 1. Introduction

The liver is the primary organ in the body that handles biosynthesis and catabolism of critical biomolecules, including protein synthesis, detoxification, and metabolism of numerous xenobiotics and drugs, with some of their metabolites

having harmful effects on the liver integrity and functions. Liver injury increases serum levels of malondialdehyde (MDA), cholesterol, low-density lipoprotein (LDL), triacylglyceride (TAG), and bilirubin and decreases the antioxidant system,

including superoxide dismutase (SOD), catalase (CAT), glutathione peroxidase (GPx), reduced glutathione (GSH) and glutathione S-transferase (GST) activities (Subramaniam *et al.*, 2015; Abou-Seif *et al.*, 2019). The antioxidant enzyme superoxide dismutase converts superoxide radicals to a less toxic radical, which can be efficiently detoxified to water and oxygen by either catalase or glutathione peroxidases and, thus, prevent oxidative stress (Zhu *et al.*, 2012). Some of the drugs and xenobiotics metabolised in the liver deplete the antioxidant enzymes in the liver and release excess free radicals making the liver cells vulnerable to oxidative attack, injury and decline in liver functions. Currently, there is no cure or complete treatment options for hepatic injury, but therapeutic agents with antioxidant activities have been found useful in managing and preventing hepatic injury (Yahya *et al.*, 2018). The elevation of serum hepatic enzyme activities, including alanine transaminase (ALT), aspartate transaminase (AST) and alkaline phosphatase (ALP) in the presence of liver cirrhosis, liver diseases, hepatitis, fibrosis, steatosis and necrosis are the standard features of liver injury (Tilahun, 2018). Liver injury causes liver malfunctions and decreases the capacity of the liver to carry out biotransformation, detoxification and synthesis of key macromolecules and deteriorates the life of an individual and could result in death if no adequate medical intervention is initiated on the patient on time (Abou-Seif *et al.*, 2019). There are various established hepatotoxic agents, including paracetamol, carbon-tetrachloride, cadmium and lead acetate, available for the experimental induction of hepatic injury in animal models for the evaluation of the effects of therapeutic agents on the liver, but in this study, Dutasteride was used.

Dutasteride is a therapeutic agent used for the management of BPH because it competitively inhibits type 1 and 2, 5 $\alpha$ -reductase enzyme activities and prevents the conversion of testosterone to dihydrotestosterone which halts prostate enlargement (Kurczewski *et al.*, 2017). Despite the high therapeutic potency of Dutasteride against BPH progression, there have been reported cases of adverse health effects including low blood pressure, dizziness, headache, erectile dysfunction, ejaculatory disorder, low sperm counts and impotence (Roehrborn *et al.*, 2008). There have been reported cases of increased glycated haemoglobin levels, abnormal lipid profile, serum hepatic enzymes (ALT, AST, and ALP) activities,

hepatotoxicity and impaired liver functions in animals treated with Dutasteride (Mohamad *et al.*, 2017; Traish *et al.*, 2017). Recently, prolonged use of Dutasteride has been linked to an increased incidence of both type 1 and 2 diabetes, dry eye disease, and kidney diseases (Livingstone *et al.*, 2015).

*Aju Mbaise* is a polyherbal medicine indigenous to the Mbaise communities in Imo State, Nigeria, popularly consumed as a nutraceutical by nursing mothers for the first 1-2 months after delivery to ease stomach and uterus relaxation, remove residual placenta after birth and blood flow (Ogueke *et al.*, 2016). *Aju Mbaise* contains six medicinal plants, including *Euphorbia convolvuloids*, *Uvaria chamae*, *Spondias mombine*, *Ceiba petandra*, *Napoleona vogelli* and *Barteria fistulosa* in varying proportions (Ijioma *et al.*, 2017). The pharmacological activities exhibited by *Aju Mbaise* extract (AME) are attributed to the constituent plants' phytochemical constituents and medicinal properties. AME also is a rich source of essential minerals, vitamins and amino acids needed for proper biochemical and physiological functions in the body (Ogueke *et al.*, 2016). It has been reported to be safe for consumption, prevents dyslipidaemia, has analgesic anti-anaemic effects and is also helpful in managing menstrual cramps (Ijioma *et al.*, 2017). *Aju Mbaise* extract (AME) has shown to be medicinally invaluable, safe, cheap and readily available. This study was designed to evaluate the ameliorative potentials of AME on Dutasteride-induced oxidative stress and hepatic injury in rats.

## 2. Materials and Methods

### 2.1. Experimental animals

Fifty-one normal male albino rats weighing 148-160 g were purchased from the animal production unit of the Department of Zoology and Environmental Sciences, University of Nigeria, Nsukka and acclimatised for 14 days at the Animal House at the Department of Biochemistry, Michael University Nsukka. The animals had unhindered access to the regular standard finisher feed and clean drinking water *ad libitum*. The animals were humanely handled as stipulated in the guidelines for the care and use of laboratory animals in adherence to the ethical approval for the study (MOUAU/VPP/EC/21/006).

## 2.2. Chemicals and reagents

Standard analytical grade chemicals and reagents were used in this study, including ethanol and chloroform obtained from Sigma-Aldrich at St. Louis, MO, United States. Commercial assay kits for hepatic enzymes (aspartate transaminase, alanine transaminase and alkaline phosphatase) activities were purchased from Randox Laboratories, United Kingdom. Dutasteride drug was purchased from the GlaxoSmithKline group of companies in the United Kingdom.

## 2.3. Collection and preparation of plants amples

Fresh *Aju Mbaise* polyherbal samples were used for this study. The fresh *Aju Mbaise* was purchased from Afor-Ogbe, Ahiara Mbaise, Imo State, Nigeria. The plant sample was dried to a constant weight under shade and pulverised into a coarse powder with a mechanical grinder. Afterwards, 750 g of the crude powder was macerated in 2.5 L ethanol solvent for 72 hours of regular agitation and filtered with a mesh cloth followed by a Whatman No. 1 filter paper. The filtrate was concentrated at 70°C in a rotary evaporator to remove the solvent, and a percentage yield of 9.64 % corresponded to 72.3 g of the *Aju Mbaise* extract (AME), which was refrigerated and used for the study.

## 2.4. Experimental design

Thirty male albino rats were selected into six groups (n= 6) and used to evaluate the hepatoprotective and antioxidant modulatory effects of AME against Dutasteride-induced hepatic injury. The groups include the normal control, Dutasteride-induced untreated, 1000 mg/kg AME, Dutasteride + 500 mg/kg AME, and Dutasteride + 1000 mg/kg AME. Dutasteride was administered orally to the rats and allowed to stay for 1 hour before the oral administration of AME. The administration of Dutasteride and AME lasted for 28 days consecutively before the rats were fasted overnight, anaesthetised with chloroform, blood samples were collected by cardiac puncture for biochemical analyses and livers were harvested for histopathological evaluation.

## 2.5. Acute toxicity (LD50) study of AME

The acute toxicity of AME was conducted with 21 rats using Lorke's method (1983) with partial modification. Concisely, the 21 rats were selected into

seven groups containing three rats each, three groups each were used for the phase I and II of the acute toxicity study, respectively, while the remaining one group was used for the confirmation of phase I and II results. The three groups in the phase study were given 10, 100 and 1000 mg/kg AME, respectively, via the oral route and monitored for the next 24 hours. After no signs or symptoms of toxicity of AME were observed in the rats, the three groups for phase II were administered 1600, 2900 and 5000 mg/kg AME, respectively, and observed for 24 hours. The confirmatory group was administered 5000 mg/kg AME and also observed for 24 hours which indicated no death or toxicity signs in the rats. Thus, the acute toxicity dose of AME was obtained according to Lorke's equation:

$$LD_{50} = \sqrt{A \times B}$$

A = Highest dose without mortality

B = Least dose with mortality

## 2.6. Biochemical analyses

The serum antioxidant enzymes catalase superoxide dismutase (SOD), catalase (CAT), and glutathione peroxidase (GPx) activities, were analysed, respectively, according to the methods of Kakkar *et al.* (1984), Aebi (1984), and Rotruck *et al.* (1973). The serum liver marker enzyme activities, including aspartate transaminase (AST), alanine transaminase (ALT), and alkaline phosphatase (ALP), were assayed according to the outlines in their respective Randox assay kits. The total serum protein, albumin and MDA concentrations were determined following the methods of Gornall *et al.* (1949), Doumas and Biggs (1972) and Wallin *et al.* (1993), respectively, while the serum globulin concentration was obtained as the difference between the total serum protein and albumin concentrations. Also, the methods of Jendrassik and Grof (1938) were employed to determine the total serum bilirubin and direct bilirubin concentration.

## 2.7. Histopathological evaluation

Liver sections collected from every group in the study were washed in normal saline, fixed with 10% buffered formalin, and in paraffin wax. It was allowed to undergo dehydration before being exposed to hematoxylin and eosin. Afterwards, it was sectioned into 5-µm thickness for the observation of the

morphological changes as described by Uroko *et al.* (2015).

### 2.8. Statistical analysis

The experimental data were subjected to one-way analysis of variance (ANOVA) and Duncan multiple range comparison tests with statistical significance attained at 95% ( $P < 0.05$ ) confidence level. The results were presented as mean  $\pm$  standard deviation ( $n = 6$ ).

## 3. Results and discussion

### 3.1. Acute toxicity effects of AME in rats

The acute toxicity study of AME in rats indicated that the extract caused no adverse signs or symptoms of toxicity and death even when a very high dose, 5000 mg/kg, was administered to the rats (Table 1). The

absence of death, symptoms or signs of toxicity in the rats 24 – 72 hours after administering low to a very high dose of AME showed that the polyherbal extract is not acutely toxic. This observation is consistent with its use by nursing mothers in southeast Nigeria, as none of the consumers has reported any adverse reactions despite the volume consumed and extended duration of its use in restoring the womb and stomach to normalcy, as claimed by the local consumers. However, some rare reactions may be associated with its prolonged usage that may be difficult to differentiate from the normal physiological and biochemical fluctuations. The safety level of AME observed in this study is in line with Ijioma *et al.* (2021) that *Aju Mbaise* polyherbal extract is safe for consumption but cautioned on its prolonged excessive intake over some time.

**Table 1:** Acute toxicity of AMEs in rats.

Groups	Dose (mg/kg)	Mortality	% Mortality	Observations
<b>Phase I</b>				
Group 1	10	0/3	0.00	No mortality. The animals showed no signs or symptoms and were physically stable.
Group 2	100	0/3	0.00	
Group 3	1000	0/3	0.00	
<b>Phase II</b>				
Group 1	1600	0/3	0.00	No mortality. The animals were physically stable.
Group 2	2900	0/3	0.00	
Group 3	5000	0/3	0.00	

The highest dose, 5000 mg/kg, was repeated on another set of 3 animals, but none of the rats showed toxicity or died after 24 hours.  $LD_{50} > 5000$  mg/kg. (Note: 0/3 = 0 death out of 3 rats).

### 3.2. Effects AME on the liver function parameters of rats induced liver injury with Dutasteride

The total protein concentrations declined significantly in the Dutasteride induced untreated rats and rats induced low Dutasteride and treated with 500 mg/kg AME compared with the normal control (Table 2). The rats that received 1000 mg/kg AME and induced Dutasteride, treated with 1000 mg/kg AME, had no significant ( $P > 0.05$ ) increase in their total protein concentrations relative to the normal control. The total protein concentrations in the rats that received 1000 mg/kg AME and rats induced Dutasteride, treated with 500 and 1000 mg/kg of AME, respectively, were significantly increased compared to those that received only Dutasteride.

The rats induced Dutasteride without treatment had significantly reduced albumin concentrations than the normal control (Table 2). Besides, the rats that received 1000 mg/kg AME only and those administered

Dutasteride treated with 1000 mg/kg AME showed no significant ( $P > 0.05$ ) elevation in their albumin concentration relative to the normal control. On the other hand, there was no significant decline in the serum albumin concentration of the Dutasteride-induced rats treated with 500 mg/kg AME compared to the normal control. Treatment of rats with 1000 mg/kg AME and Dutasteride induced rats with 500 and 1000 mg/kg AME, respectively, resulted in a significant elevation of the albumin concentrations compared to the Dutasteride induced untreated rats.

The data in Table 2 show that the Dutasteride-induced untreated rats significantly reduced serum globulin concentrations compared to the normal control. However, rats administered 1000 mg/kg AME only, and rats induced Dutasteride, treated with 500 and 1000 mg/kg AME, respectively, indicated no significant differences in their serum globulin concentrations relative to the normal control. However,

the total serum bilirubin of rats administered 1000 mg/kg AME only and Dutasteride-induced rats, treated with 500 and 1000 mg/kg AME, respectively, showed marked elevation compared with the Dutasteride-induced untreated rats.

The aspartate transaminase (AST) activities displayed a significant increase in the Dutasteride induced untreated and Dutasteride induced rats, treated with 500 mg/kg AME, respectively, compared to the normal control. The AST activity of rats that received only 1000 mg/kg AME decreased non-significantly. In contrast, the Dutasteride-induced rats treated with 500 and 1000 mg/kg AME, respectively, showed no significant increase in the AST activities relative to the normal control. Treatment of Dutasteride induced rats with 500 and 1000 mg/kg AME significantly reduced AST activities compared with the Dutasteride induced untreated rats.

The Dutasteride-induced untreated rats and Dutasteride-induced rats treated with 500 mg/kg AME showed a significant ( $P < 0.05$ ) increase in the alanine transaminase (ALT) activities compared to the normal control (Table 2). However, there was no significant decrease in the ALT activity of the rats treated with 100 mg/kg AME only and no significant rise in the Dutasteride induced rats treated with 1000 mg/kg AME respectively, relative to the normal control. Treatment of hepatic injury-induced rats induced with 500 and 1000 mg/kg AME, respectively, caused a significant decline in the ALT activities compared to the rats induced Dutasteride without any treatment.

The results in Table 2 indicated a significant rise in the alkaline phosphatase (ALP) activities of the Dutasteride-induced untreated rats and Dutasteride-induced rats treated with 500 mg/kg AME compared with the normal control. Besides, the rats that received 1000 mg/kg AME only and Dutasteride induced rats treated with 1000 mg/kg AME elicited no significant decline in the ALP activities compared to the Dutasteride induced untreated rats. The Dutasteride-induced rats treated with 500 and 1000 mg/kg AME had significantly reduced ALP activities compared to the Dutasteride-induced untreated rats.

The serum bilirubin levels were significantly elevated in the Dutasteride-induced untreated rats and those treated with 500 mg/kg AME relative to the normal control (Table 2). While there was no significant decrease in the serum bilirubin concentrations in rats administered 1000 mg/kg AME

and no significant increase in the serum bilirubin concentrations in the Dutasteride induced rats treated with 1000 mg/kg AME compared to the normal control. The Dutasteride-induced rats treated at 500 and 1000 mg/kg AME also had significantly diminished serum bilirubin concentrations compared with the Dutasteride-induced untreated rats.

Dutasteride is an anti-benign prostatic hyperplasia drug primarily metabolised in the liver that competitively inhibits  $5\alpha$ -reductase enzyme activity and prevents the conversion of testosterone to dihydrotestosterone which shrinks an enlarged prostate. Dutasteride causes numerous adverse side effects on prolonged use, including increased risk of low sperm quality, loss of sexual interest, diabetes, cholesterolemia, and liver disease (Abdulmaged *et al.*, 2017). The significantly elevated hepatic enzyme activities, including AST, ALT, and ALP, along with decreased total serum protein, albumin, and globulin and considerably elevated total bilirubin and direct bilirubin concentrations in the Dutasteride induced untreated rats to suggest liver injury in the rats in line with the report of Abou-Seif *et al.* (2019). The marked increase in the serum AST, ALT, and ALP activities in the Dutasteride-induced untreated rats indicated liver injury. The liver injury caused increased permeability of the hepatocyte membrane that caused increased leakage of these hepatic enzymes to the extrahepatic environments. These enzymes are confined to the hepatocytes making their concentrations and activities in the serum relatively low. Still, the hepatic integrity disruption and their cytosol leakage cause a significant rise in their serum concentrations and activities. The elevation in the serum activities of AST and ALT coupled with the ALP to a greater extent is considered an excellent indicator of hepatic injury since their contribution from other sources is considered insignificant due to their minute concentrations in other organs, unlike the liver (Uroko *et al.*, 2015). Healthy liver cells are responsible for protein synthesis, including albumin, that transports hormones and low-density lipoproteins to their sites of action and metabolism, respectively, and for the synthesis of globulin, a critical component of immunoglobulin for the body's defence system. The highly reduced serum total protein, albumin and globulin in the Dutasteride-induced untreated rats suggest defective liver cells with impaired ability to synthesise sufficient proteins to meet the body's needs, in line with Uroko *et al.* (2022).

These declined levels of total serum protein, albumin and globulin in Dutasteride induced untreated rats indicate the rats were predisposed to developing dyslipidaemia, compromised immune system and some impaired biochemical functions that would lead to some complications. The significantly elevated serum total bilirubin and direct bilirubin levels in the Dutasteride-induced untreated rats further showed that the rat suffered a liver injury and impaired liver functions, which made them unable to conjugate and clear bilirubin efficiently.

In contrast, the significantly reduced AST, ALT, and ALP activities in the Dutasteride-induced rats with AME showed that the extract possesses hepatoprotection that maintained intact liver cells, decreased hepatocyte membrane permeability and leakage of hepatic enzymes to the cytosol in line with the findings of Traish *et al.* (2017). The reduced levels of circulating AST, ALT, and ALP in the extrahepatic

environment significantly reduced their activities, and they showed the recovery of the Dutasteride-induced rats from hepatic injury. In addition, the substantially decreased total serum bilirubin and direct bilirubin concentrations and elevated complete protein, albumin and globulin concentrations in the Dutasteride induced rats treated with AME further indicated the recovery of the rats from liver injury caused by Dutasteride toxicity. Treatment of Dutasteride-induced rats with AME improved their protein synthesis and bilirubin detoxification, leading to the efficient transport of biomolecules by albumin and improved immunoglobulin synthesis for immunological responses. Contrary to the suggestion of Ijioma *et al.* (2021) that prolonged administration of AME above 400 mg/kg may be toxic, the rats administered 1000 mg/kg of AME for 28 days showed no signs or symptoms of hepatotoxicity.

**Table 2:** Liver function parameters of rats induced hepatic injury with Dutasteride and treated with AME.

Parameters	Normal control	Dutasteride (0.5 mg/kg)	AME (1000 mg/kg)	Dutasteride+ 500 mg/kg AME	Dutasteride+ 1000 mg/kg AME
AST (u/L)	27.80±0.84 <sup>a</sup>	62.80±5.22 <sup>c</sup>	26.20±1.30 <sup>a</sup>	33.00±2.24 <sup>b</sup>	28.60±2.41 <sup>a</sup>
ALT(u/L)	16.20±1.30 <sup>b</sup>	54.60±4.16 <sup>c</sup>	15.20±0.84 <sup>a</sup>	20.00±1.58 <sup>b</sup>	18.00±1.58 <sup>ab</sup>
ALP (u/L)	54.20±4.92 <sup>a</sup>	69.20±5.40 <sup>c</sup>	51.00±2.00 <sup>a</sup>	60.80±1.79 <sup>b</sup>	51.20±2.86 <sup>a</sup>
Total Protein (g/dl)	8.59±0.57 <sup>c</sup>	5.19±0.45 <sup>a</sup>	8.79±0.68 <sup>c</sup>	7.73±0.25 <sup>b</sup>	8.98±0.74 <sup>c</sup>
Albumin (g/dl)	4.63±0.75 <sup>b</sup>	3.10±0.57 <sup>a</sup>	4.95±0.41 <sup>b</sup>	4.39±0.22 <sup>b</sup>	4.86±0.38 <sup>b</sup>
Globulin (g/dl)	3.97±0.21 <sup>b</sup>	2.08±0.82 <sup>a</sup>	4.12±0.95 <sup>b</sup>	3.34±0.28 <sup>b</sup>	3.84±0.73 <sup>b</sup>
Bilirubin (mg/dl)	0.45±0.04 <sup>ab</sup>	0.66±0.07 <sup>d</sup>	0.42±0.01 <sup>a</sup>	0.54±0.03 <sup>c</sup>	0.48±0.03 <sup>b</sup>

Values in the table display mean ± standard deviation (n = 6), and with a different letter, superscripts are significantly different (P<0.05) from any paired mean across the row.

### 3.3. Effects of AME on the antioxidant parameters of rats induced hepatic injury with Dutasteride

The glutathione (GSH) activities in Table 3 significantly diminished in the Dutasteride-induced untreated rats and Dutasteride-induced rats that received 500 mg/kg AME compared to the normal control. On the other hand, rats which were administered 1000 mg/kg AME only and Dutasteride-induced rats treated with 1000 mg/kg AME showed a minimal increase in GSH activities compared to the normal control. Contrarily, rats that received only 1000 mg/kg AME and Dutasteride-induced rats treated with 500 and 1000 mg/kg of AME had significantly increased GSH activities compared to the Dutasteride-induced untreated rats.

The results in Table 3 indicated a massive decline in the GPx activities of the Dutasteride-induced untreated rats and Dutasteride-induced rats treated with 500 and

1000 mg/kg of AME, respectively, relative to the normal control. Also, the rats administered 1000 mg/kg AME only slightly increased GPx activity compared to the normal control. Besides, the treatment of Dutasteride-induced rats with 500 and 1000 mg/kg AME, respectively, elicited a dose-dependent rise in the GPx activities compared with the Dutasteride-induced untreated rats.

Table 3 displayed a significant reduction in the SOD activities in the Dutasteride induced untreated rats and Dutasteride induced rats administered 500 and 1000 mg/kg AME, respectively, relative to the normal control. The rats that received only 1000 mg/kg AME showed no significant rise in the SOD activities compared to the normal control. The administration of 500 and 1000 mg/kg AME to the Dutasteride-induced rats caused a significant elevation of SOD activities compared to the Dutasteride-induced untreated rats.

The administration of 1000 mg/kg AME to rats only caused a significant elevation of catalase activities in the rats when compared with the normal control. Contrarily, no significant rise in the catalase activities of the Dutasteride induced rat treated with 1000 mg/kg AME unlike the Dutasteride-induced untreated rats, and Dutasteride induced rats administered 500 mg/kg AME that showed significant decline compared to the normal control. It was observed that the Dutasteride-induced rats treated with AME had significantly elevated catalase activities relative to the Dutasteride-induced untreated rats.

The administration of 1000 mg/kg AME to rats only caused a significant elevation of catalase activities in the rats compared with the normal control. Contrarily, no significant rise in the catalase activities of the Dutasteride induced rat treated with 1000 mg/kg AME unlike the Dutasteride-induced untreated rats, and Dutasteride induced rats administered 500 mg/kg AME that showed a significant decline compared to the normal control. The Dutasteride-induced rats treated with AME had significantly elevated catalase activities relative to the Dutasteride-induced untreated rats.

The significantly diminished levels of GSH, GPx, SOD, and CAT activities, together with highly elevated MDA concentration in the Dutasteride-induced untreated rats, showed the adverse effects of Dutasteride on the antioxidant systems and increased lipid peroxidation and aligned with earlier findings by Uroko *et al.* (2021). The synergistic actions of SOD and CAT antioxidants coupled with GSH and GPx activities effectively scavenge superoxide and hydrogen peroxide in the body and convert them to harmless products, water and oxygen, which reduce oxidative stress substantially and oxidative attacks, including lipid peroxidation on biomolecules. The

decrease in the SOD, GSH, GPx and CAT activities in the Dutasteride induced untreated rats showed the toxic effects of Dutasteride on the antioxidant system, which could have repressed the expression of these antioxidant enzymes and proteins or increased their susceptibility to cross-linking and rapid destruction than they were synthesised Uroko *et al.* (2021). The increased serum MDA concentrations in the Dutasteride-induced untreated rats showed a high degree of lipid peroxidation that could have negatively altered membrane integrity. They damaged various biomolecules, which aligns with Adewole and Adebayo's previous findings (2017). Treatment of Dutasteride induced rats with AME significantly reversed the toxic effects of Dutasteride on the antioxidant parameters, as there were elevated levels of SOD, CAT, GSH, and GPx activities and decreased MDA concentrations significantly. The high antioxidant parameters and low MDA concentrations in the Dutasteride-induced rats treated with AME showed an improved antioxidant defence system against oxidative stress and lipid peroxidation. The administration of AME could have caused increased expression of these antioxidant enzymes and proteins by their respective genes, reduced their rate of destruction in the body and maintained optimal antioxidant levels to counter reactive free radicals and prevent oxidative stress. These findings suggest that AME improves the in vivo antioxidant status of Dutasteride-treated rats, which helped confer hepatoprotection to the rats. When taken by patients undergoing treatment with Dutasteride, it may prevent oxidative stress, hepatotoxicity and adverse health complications associated with prolonged use of Dutasteride, which is consistent with the findings of Kim *et al.* (2022).

**Table 3.** Antioxidant enzyme activities and malondialdehyde concentrations in rats induced hepatic injury with Dutasteride and treated with AME.

Parameters	Normal control	Dutasteride (0.5 mg/kg)	AME (1000 mg/kg)	Dutasteride + 500 mg/kg AME	Dutasteride+ 1000 mg/kg AME
GSH (u/mg protein)	44.34±1.22 <sup>c</sup>	27.82±0.86 <sup>a</sup>	46.28±0.85 <sup>c</sup>	40.60±1.13 <sup>b</sup>	44.97±2.67 <sup>c</sup>
GPx (u/mg protein)	36.82±0.87 <sup>c</sup>	25.33±0.83 <sup>a</sup>	39.67±2.07 <sup>d</sup>	31.96±1.33 <sup>b</sup>	35.48±1.42 <sup>c</sup>
SOD (u/mg protein)	16.45±0.77 <sup>c</sup>	10.75±0.85 <sup>a</sup>	17.29±1.01 <sup>c</sup>	14.47±0.77 <sup>b</sup>	14.99±0.89 <sup>b</sup>
CAT (u/mg protein)	15.17±0.81 <sup>c</sup>	9.48±0.91 <sup>a</sup>	16.23±0.74 <sup>d</sup>	14.07±0.50 <sup>b</sup>	14.77±0.72 <sup>b,c</sup>
MDA (mmol/mg protein)	0.38±0.03 <sup>a</sup>	2.02±0.05 <sup>d</sup>	0.36±0.03 <sup>a</sup>	0.60±0.08 <sup>c</sup>	0.48±0.04 <sup>b</sup>

Values in the table display mean ± standard deviation (n = 6), and with a different letter, superscripts are significantly different (P < 0.05) from any paired mean across the row.

### 3.4. Photomicrographs of liver sections from rats induced hepatic injury with and treated with AME

The photomicrographs in Figures 1a, c, d and e highlighted normal hepatic histo-architecture of a typical rodent liver with central vein and portal area indicated as (V) and (P), respectively. However, the liver photomicrograph of Dutasteride-induced untreated rats in Figure 1b showed mild to moderate vacuolar degeneration of the hepatocytes in the perivascular areas of the hepatic lobules. The affected hepatocytes appear swollen, with multiple clear cytoplasmic vacuoles (arrow) and tend to impede the adjacent sinusoids.

The normal hepatic histo-architectures observed from the histological examination of the hepatic tissue sections of the rats administered 1000 AME mg/kg. Rats induced Dutasteride treated with 500 and 1000 AME mg/kg, respectively, compared to the normal control rats, showed the hepatoprotective effects of AME and agrees with findings Kim *et al.* (2022). The healthy hepatic tissue sections observed in the Dutasteride-induced rats treated with AME are consistent with the low serum hepatic enzyme activities (AST, ALT, and ALP) and improved antioxidant markers (GSH, SOD, CAT, GPx and MDA) observed in these rats which together showed that the treatment with AME prevented oxidative stress and hepatic injury in the rats. The elevated serum MDA concentrations in the Dutasteride-induced untreated rats indicated an increased lipid peroxidation level and aligned with the findings of Olayinka *et al.* (2015). In contrast, the mild to moderate vacuolar degeneration of the hepatocytes in the perivascular areas of the hepatic lobules in which the affected hepatocytes appear swollen, with multiple clear cytoplasmic vacuoles and tend to impede the adjacent sinusoids are evidence that Dutasteride administration caused hepatic injury in the rats. The vacuolar degeneration of the hepatocytes in the Dutasteride-induced untreated rats is in line with the elevated hepatic enzyme activities, lipid peroxidation and decreased antioxidant system in the rats and suggests that Dutasteride should be administered with antioxidant supplements to prevent oxidative stress and the associated hepatic damage and agrees with the reports of Mohamad *et al.* (2017).

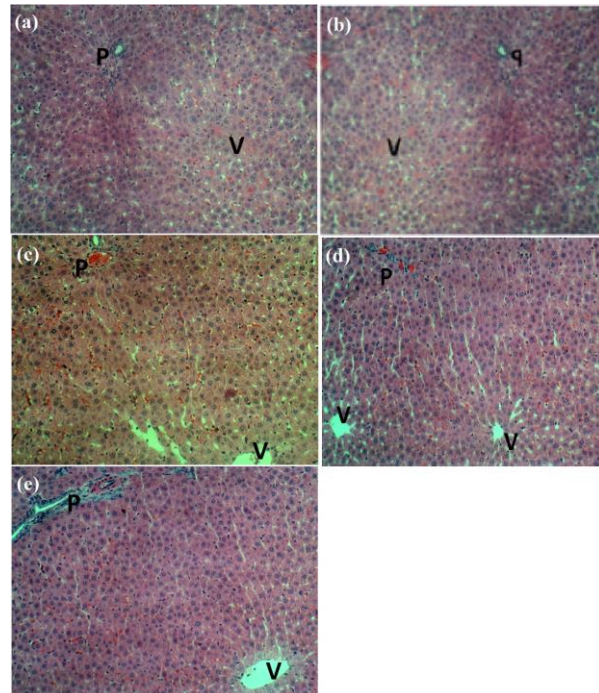


Figure 1. The photomicrographs a-e are kidney sections of rats from the normal control, Dutasteride only, 1000 mg/kg AME, Dutasteride+500 mg/kg AME, and Dutasteride+1000 mg/kg AME, respectively.

## 4. Conclusion

The findings showed that AME is relatively safe for consumption and ameliorates Dutasteride-induced oxidative stress and hepatic injury, suggesting it could be beneficial in managing oxidative stress, lipid peroxidation and preventing complications in hepatic injury. Further study is required to evaluate its bioactive composition and chronic effects on humans.

## 5. Acknowledgements

Authors grateful to Dr. SN Ijioma and Prof. C.K. Ezeasor for their technical support and assistance throughout the study.

## 6. References

Abdulmaged, T., Haider, K.S., Gheorghe, D. and Ahmad, H. 2017. Long-term Dutasteride therapy in men with benign prostatic hyperplasia alters glucose and lipid profiles and increases the severity of



- erectile dysfunction. *Hormone Molecular Biology and Clinical Investigation*, 30(3): 20170015.
- Abou-Seif, H.S., Hozayen, W.G. and Hashem, K.S. 2019. *Thymus vulgaris* extract modulates dexamethasone-induced liver injury and restores the hepatic antioxidant redox system. *Beni-Suef University Journal of Basic and Applied Sciences*, 8:21-29.
- Adewole, K.E. and Adebayo, J.O. 2017. Antioxidant defence system induced by cysteine stabilised peptide fraction of aqueous extract of *Orinda lucida* leaf in selected tissues of *Plasmodium berghei*-infected mice. *Journal of Integrative Medicine*, 15:388-397.
- Aebi, H. 1984. Catalase *in vitro*. *Methods in Enzymology*, 105: 121-126.
- Doumas, B.T. and Biggs, H.G. 1972. Determination of Serum Albumin. In: *Standard Methods of Clinical Chemistry*. Cooper GA, Ed. NY Academic Press Inc. pp. 7:175.
- Gornall, A.G., Bardawill, J.C. and David, M.M. 1949. Determination of serum proteins by means of Biuret reaction. *Journal of Biological Chemistry*, 177: 751-760.
- Ijioma, S.N., Emmanuel, O., Nosiri, C.I. and Ugbogu, E.A. 2021. Evaluation of toxicity profile and pharmacological potentials of *Aju Mbaise* polyherbal extract in rats. *Scientific African*, 11 (2021) e00681.
- Ijioma, S.N., Osim, E.E., Nwankwo, A.A., Nwosu, C.O., Nwankudu, O.N. and Ekeleme, C.M. 2017. Antioxidant potentials and effects on the haematology and osmotic fragility scores of a polyherbal formulation used in Southeast Nigeria. *Journal of Basic and Clinical Physiology and Pharmacology*, 2017: 1-10
- Jendrassik, L. and Grof, P. 1938. Simplified Photometric: Methods for the determination of bilirubin. *Biochemical Journal*, 297: 81-89.
- Kakkar, P., Das, B. and Viswanathan, P.N. 1984. A modified spectrophotometric assay of superoxide dismutase. *Indian Journal of Biochemistry and Biophysics*, 21(2):130-132.
- Kim, S.M., Diao, W.J., An, W., Kim, H.J., Lim, H.J., Kim, K.N., Bae, G.W. and Kang, J.S. 2022. Effect of porcine placental extract mixture on alcohol-induced hepatotoxicity in rats. *Current Issues in Molecular Biology*, 44: 2029-2037.
- Kurczewski, R., Bowen, C., Collins, D., Zhu, J., Serbest, G. and Manyak, M. 2017. Bioequivalence studies of a reformulated dutasteride and tamsulosin hydrochloride combination capsule and a commercially available formulation. *Clinical Pharmacology in Drug Development*, 6: 508-516.
- Livingstone, D.E., Barat, P., Di Rollo, E.M., Rees, G.A., Weldin, B.A. and Rog-Zielinska, E.A. 2015. 5 $\alpha$ -Reductase type 1 deficiency or inhibition predisposes to insulin resistance, hepatic steatosis, and liver fibrosis in rodents. *Diabetes*, 64:447-58.
- Lorke, D. 1983. A new approach to practical acute toxicity testing. *Archives of Toxicology*, 54: 275-87.
- Mohamad, B.J., Obaid, H.H., Mohamad, D.I. and Salim, M. 2017. Study the toxic effect of different doses of duprost in liver and blood of albino mice. *Iraqi Journal of Science*, 58: 1381-1392.
- Ogueke, C.C., Clifford, I., Owuamanam, C.O., Iroanya, A., Bede, E.N. and Nwachukwu, I.N. 2016. Antibacterial activity, phytochemical properties and mineral content of *Aju Mbaise* decoction: a liquid extract administered to nursing mothers. *Nigerian Journal of Nutritional Sciences*, 37: 114–120.
- Olayinka, E.T., Ore, A. and Adeyemo, O.A. 2015. Quercetin, a flavonoid antioxidant, ameliorated procarbazine-induced oxidative damage to murine tissues. *Antioxidants*, 4: 304-321.
- Roehrborn, C.G., Siami, P., Barkin, J., Damião, R., Major-walker, K., Morrill, B. and Montorsi, F. 2008. The effects of Dutasteride, tamsulosin and combination therapy on lower urinary tract symptoms in men with benign prostatic hyperplasia and prostatic enlargement: 2-year results from the combat study. *Journal of Urology*, 179: 616-621.
- Rotruck, J.T., Pope, A.L., Ganther, H.E., Swanson, A.B., Hafeman, D.G. and Hoekstra, W.G. 1973. Selenium: Biochemical role as a component of glutathione peroxidase. *Science*, 179(4073): 588-590.
- Subramaniam, S., Khan, H.B.H., Elumalai, N. and Lakshmi, S.Y.S. 2015. Hepatoprotective effect of ethanolic extract of whole plant of *Andrographis paniculata* against CCl<sub>4</sub>-induced hepatotoxicity in rats. *Comparative Clinical Pathology*, 24: 1245-1251.
- Tilahun, T.J.M.M. 2018. Ethnobotanical study of medicinal plants used to treat human diseases in Berbere District, Bale Zone of Oromia Regional State, South East Ethiopia. *Evidence-Based Complementary and Alternative Medicine*, 18(5): 2-15.
- Traish, A., Haider, K., Doros, G. and Haider, A. 2017. Long-term dutasteride therapy in men with benign

prostatic hyperplasia alters glucose and lipid profiles and increases severity of erectile dysfunction. *Hormone Molecular Biology and Clinical Investigation*, 30: 1-16.

Uroko, R.I., Sangodare, R.S.A., Muhammad, K.H. and Asadu, C.L. 2015. Effect of methanol extract of *Abrus precatorius* leaves on male Wistar albino rats induced liver damage using carbon tetrachloride. *Journal of Biological Sciences*, 15 (3): 116-123.

Uroko, R.I., Agbafor, A., Egba, S.I., Nwuke, C.P. and Kalu-Kalu, S. 2021. Evaluation of antioxidant activities and haematological effects of *Asystasia gangetica* leaf extract in monosodium glutamate-treated rats. *Lekovite Sirovine*, 41: 5-11.

Uroko, R.I., Nweje-Anyalowu, P.C., Aaron, C.F. and Chukwu, C.N. 2022. Combined extract of *Spermacoce radiata* (DC.) Hiern and *Hypselodelphys poggeana* (K. Schum.) Milne-Redh leaves (CEESH) confer hepatoprotection in rat induced benign prostatic hyperplasia. *Plant Biotechnology Persa*, 4(1): 78-88.

Wallin, B., Rosengren, B., Shertzer, H.G. and Camejo, G. 1993. Lipoprotein oxidation and measurement of thiobarbituric acid reacting substances formation in a single microtiter plate: Its use for evaluation of antioxidants. *Analytical Biochemistry*, 208(1):10-15.

Yahya, F., Sfouq, F., Mahmoud, A.Z. and Nayyar, N. 2018. Chemical composition and antimicrobial, antioxidant, and anti-inflammatory activities of *Lepidium sativum* seed oil. *Saudi Journal of Biological Sciences*, 3(1): 2-5.

Zhu, R., Wang, Y., Zhang, L. and Guo, Q. 2012. Oxidative stress and liver disease. *Hepatology Research*, 42: 741-749.