



Comparison of the eyebrow elevation using subcutaneous and subperiosteal dissection plans in temporal eyebrow lifting procedure: A review article

Alireza Sedighi^{1*}, GholamReza Shirani²

Received: 2024-04-15/ Accepted: 2024-06-28 / First publication date: 2024-11-03

© The Author(s) 2024

Abstract

Background: Eyebrow position is one of the most critical features of facial beauty. Patients undergo rejuvenation procedures due to the congenital condition of drooping eyebrows and senile changes in the area around the eyes, which often cause drooping eyebrows. This study reviews the subcutaneous and subperiosteal (endoscopic) dissection techniques in the temporal eyebrow lift procedures.

Materials & Methods: In this review study, the PubMed, Embase, and Scopus databases and 100 first hits of Google Scholar were searched from 2000 to 2023. The following keywords were included: temporal lift, lateral brow lift, lateral brow hooding, lateral brow ptosis, subcutaneous dissection, subperiosteal dissection, endoscopic brow lift, and dissection plan. Articles meeting the inclusion criteria were included in this study.

Results: Thirteen studies met the inclusion criteria. Most of the studies were retrospective and reported high patient satisfaction with an acceptable risk profile. The subcutaneous dissection method has advantages, including safety, shorter operation time, the possibility to perform under local anesthesia, long-term and stable outcomes with a low probability of complications, and high patient satisfaction. The best indications for an endoscopic brow lift are patients with short or normal forehead height, flat forehead, and those whose hairline has receded, with no or a minimum amount of excess skin medially. On the other hand, eyebrow lift with the endoscopic method is minimally invasive as an advantage.

Conclusion: The subcutaneous dissection method is a reliable, safe, cheap, and repeatable option for lateral eyebrow lift. Clinical studies with standardization of outcome criteria in eyebrow rejuvenation are recommended. On the other hand, the endoscopic method has the same efficacy for eyebrow lift procedures and is minimally invasive.

Keywords: Endoscopy, Eyebrows, Lifting, Rejuvenation

Introduction

The eyebrow is a complex structure of the human face, representing people's individual appearance (1-3). In men, the eyebrow is wider and heavier than in women. It is located on the upper orbital rim with a slight arch in the horizontal plane. In contrast, the eyebrow starts from the middle or below the rim in women, rises

laterally with an arch, reaches the highest level in the lateral third, and narrows (2, 4).

A small deviation from this standard configuration may cause abnormal results. Excessive and exaggerated lift of the entire eyebrow or the inner part can create a surprised look. The distinct lift of this side with the lower medial part might create a disturbing appearance for the patient (2, 5). Anatomical changes such as congenital drooping eyebrows and senile changes around the eyes often cause lateral ptotic brows (6). The most important indications for eyebrow lifting, according to Matarasso and Torino (7), are as follows: eyebrow ptosis, forehead wrinkle lines, frown muscle imbalance, upper eyelid beauty, lateral temporal hooding, and abnormal face (angry/sad) (1).

Corresponding author: Alireza Sedighi

Cranio-maxillofacial Research Center, Tehran University of Medical Sciences, Department of Oral and Oral and Maxillofacial Surgery, School of Dentistry, Tehran University of Medical Sciences, Tehran, Iran
Email: arsadighi@gmail.com

¹Cranio-maxillofacial Research Center, Tehran University of Medical Sciences, Department of Oral and Oral and Maxillofacial Surgery, School of Dentistry, Tehran University of Medical Sciences, Tehran, Iran.

²Cranio-maxillofacial Research Center, Tehran University of Medical Sciences, Department of Oral and Oral and Maxillofacial Surgery, School of Dentistry, Tehran University of Medical Sciences, Tehran, Iran.

Ptosis causes additional folds in the lateral tissues of the eyebrow (8), a tired face, and heavy eyelids (1). To choose the best method to correct eyebrow ptosis, it is important to evaluate some of their characteristics, including the degree and extent of ptosis and eyebrow thickness, the presence of dermatochalasis, glabella, and frontal wrinkles, and the length of the hairline (3). Many eyebrow lift techniques have been approved for rejuvenation, but no gold-standard treatment works for everyone. Recognizing and matching each patient's characteristics with the appropriate method makes the maximum functional and aesthetic effect possible. The techniques include raising part of the eyebrow to performing a full forehead lift (9). The subcutaneous plan can be used in patients with distinct forehead wrinkles, lateral eyebrow drooping, and repeated surgeries (6, 10-12).

The subcutaneous plan can be used in patients with distinct forehead wrinkles and lateral eyebrow drooping and cases of revision surgery (3).

There are also various techniques to correct eyebrow ptosis, including coronal, endoscopic, hairline anterior, and temporal approaches. Eyebrow dissection methods can be subcutaneous, subgaleal, or subperiosteal (11). In this type of brow lift, which is especially used for lateral brow ptosis, incisions are made in or on the hairy scalp (approximately 3.5 cm from the midline). Excess skin is then cut elliptically according to the preferred eyebrow correction (1, 13). Following this, the lower frontalis muscle is cut to the upper edge of the eyebrow, and the wound is closed in layers. This technique effectively improves lateral eyebrow ptosis and creates acceptable scars without causing neurological complications (1, 13). Although there is higher accuracy in eyebrow positioning, the risk of flap necrosis, alopecia, and desensitization is also higher (3). In the subgaleal plane, which lacks vascular involvement, allows for raising the eyebrow with a lower risk of flap necrosis without tension (3). The subperiosteal plan involves making an incision in the hairy part of the temple. The dissection is performed in the area where the lateral and midface are separated from their attachments and placed 2–3 cm higher. In this dissection method, the entire soft tissue of the face is lifted (14). This method has the advantage of preserving the integrity of the galea, making the flap thicker and less likely to become necrotic, as well as preserving the frontoparietal innervation, and creating more tension for the eyebrow lift. The flap can be fixed by raising the skin and sutures or by fixing the flap to the periosteum using mesh or screws. The ratio between skin

removal and eyebrow lift might be between 2:1 and 5:1 (3).

This review study aimed to compare the subcutaneous and subperiosteal dissection plans in brow lifts to provide a comprehensive overview of the impact of dissection plans on brow lift outcomes.

Methods

In this review, Scopus, Embase, Pubmed, and Google Scholar databases were searched for the first 100 hits from 2000 to 2023. The following terms were searched as keywords.

(((((Temporal lift) OR Lateral brow lift) OR Lateral brow hooding) OR Lateral brow ptosis)) AND (((Subcutaneous dissection) OR Subperiosteal dissection OR Subperiosteal brow lift) OR Endoscopic brow lift OR Subgaleal dissection) OR Dissection plan)

PubMed: (((((Temporal lift) OR Lateral brow lift) OR Lateral brow hooding) OR Lateral brow ptosis)) AND (((Subcutaneous dissection) OR Subperiosteal dissection OR Subperiosteal brow lift) OR Endoscopic brow lift OR Subgaleal dissection) OR Dissection plan)
--

Scopus: (((((Temporal lift) OR Lateral brow lift) OR Lateral brow hooding) OR Lateral brow ptosis)) AND (((Subcutaneous dissection) OR Subperiosteal dissection OR Subperiosteal brow lift) OR Endoscopic brow lift OR Subgaleal dissection) OR Dissection plan)
--

Embase: (((((Temporal lift) OR Lateral brow lift) OR Lateral brow hooding) OR Lateral brow ptosis)) AND (((Subcutaneous dissection) OR Subperiosteal dissection OR Subperiosteal brow lift) OR Endoscopic brow lift OR Subgaleal dissection) OR Dissection plan)
--

Google Scholar: (((((Temporal lift) OR Lateral brow lift) OR Lateral brow hooding) OR Lateral brow ptosis)) AND (((Subcutaneous dissection) OR Subperiosteal dissection OR Subperiosteal brow lift) OR Endoscopic brow lift OR Subgaleal dissection) OR Dissection plan) 100 first hit
--

Studies were reviewed based on a series of inclusion and exclusion criteria. First, two researchers analyzed the titles and abstracts of the searched studies. Selected articles were evaluated in terms of inclusion and exclusion criteria.

Inclusion criteria

Randomized controlled trials, case reports, and prospective and retrospective studies on the effects of

subcutaneous and subperiosteal dissection plans on temporal brow lift; full-text English language studies and articles relevant to the topic published from 2000 to 2023.

Exclusion criteria

Inability to access the full texts of the articles (articles for which only the abstract was available in English and the full text was in a language other than English), systematic reviews, animal studies, and studies that performed blepharoplasty, temple, and face-lift procedures at the same time; studies with other eyebrow procedures were not included due to their potential impact on brow lift outcomes; studies with changes in dissection techniques

were not included; and studies evaluating different fixation methods were not included.

Data were extracted from the studies by one researcher.

Results

Search results

A total of 560 studies were retrieved from the specified databases through an electronic search. After removing duplicate results, 245 articles remained. Subsequently, 160 articles were excluded from the study based on title and abstract screening. Based on the inclusion and exclusion criteria, 72 articles were excluded after a full-text review. Finally, 13 studies were included in the review (Figure 1).

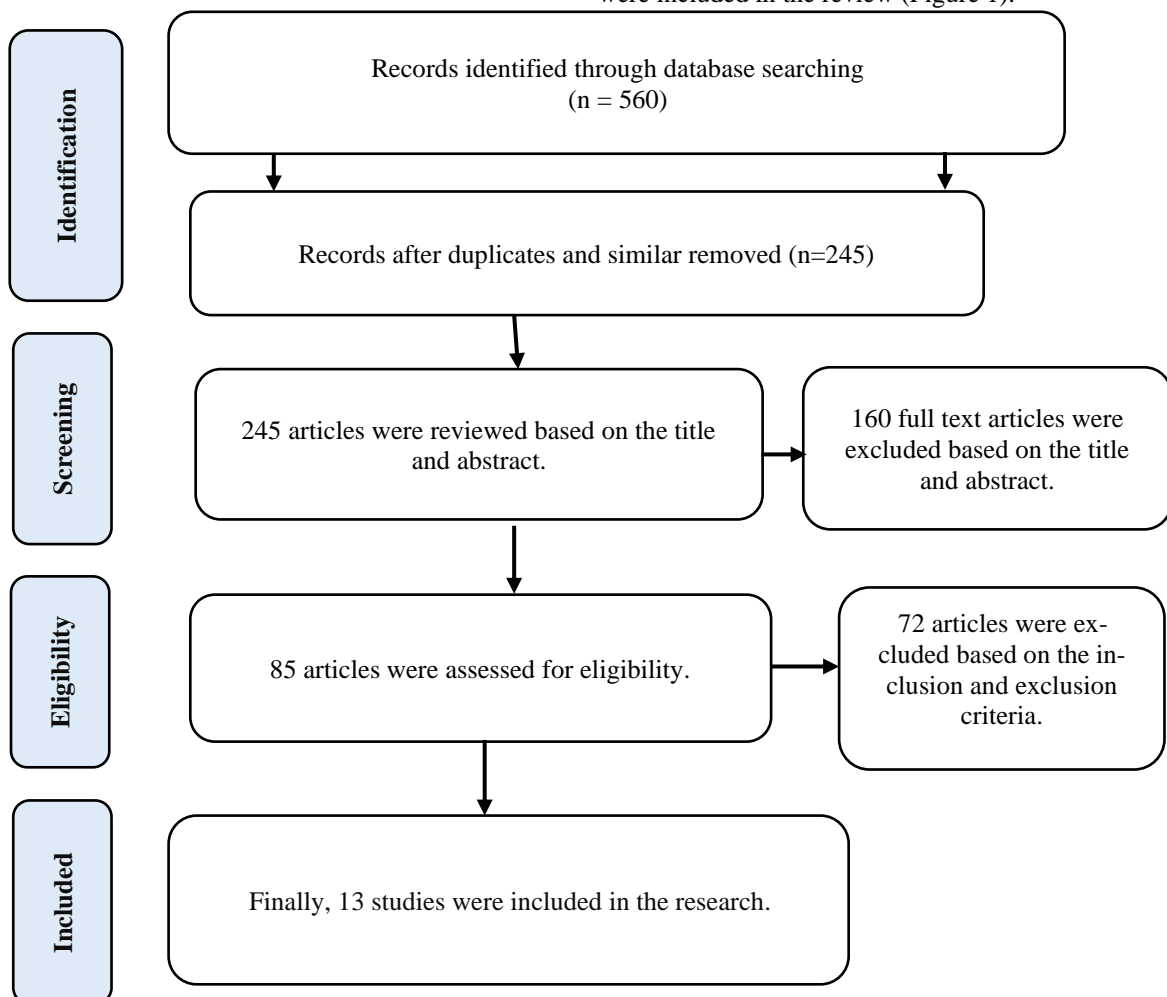


Figure 1. Study selection steps (study flow chart).

Characteristics of studies

In all studies, the majority of samples consisted of women. The follow up period for the patients varied from 2 to 192 months. Four studies reported a high level of patient satisfaction with the subcutaneous technique, while the remaining studies did not

evaluate patient satisfaction (6, 11, 15, 16). All the articles reported the effectiveness of this technique in raising the lateral eyebrows. Table 1 presents the details of studies on the subcutaneous dissection plan. Table 2 presents the complications of the subcutaneous brow lift technique.

Studies were conducted in Turkey, China, America, Iran, and Brazil. The samples' ages ranged from 20 to 68 years. In all studies, most of the samples were women. The patients were followed up for periods ranging from 5 to 24.7 months. Only one study

reported a 95.2% patient satisfaction rate after surgery (17). All studies reported the effectiveness of this technique in elevating the eyebrows. Tables 3 and 4 present the details and complications of the subperiosteal (endoscopic) brow lift dissection plan.

Table 1. Results of studies on subcutaneous brow lift dissection plan

Author, Year	Country	Study design	Sample size	Sex	Age (years)	Surgery types	Patient satisfaction	Conclusion	Follow-up duration (months)
Şibar et al. (2023) (18)	Turkey	Retrospective	42	82 f, 4 m	38-66	gliding brow lift (GBL)	nr	The use of this technique resulted in achieving a safe profile and eyebrow rejuvenation.	17.3 (Mean)
Pascali & Massarelli (2023) (15)	Italy	Retrospective	298	91% f, 9% m	22-64	subcutaneous brow lift (TSBL) associated with an orbicularis oculi muscle (OOM) elastic flap lateral temporal subcutaneous brow lifts	High satisfaction (83%)	The proposed TSBL with the OOM elastic flap technique was a reliable, effective, and highly reproducible method for the treatment of drooping and age changes of the lateral orbital region.	12
Savetsky & Matarasso (2020) (6)	USA	Retrospective	500	nr	32-84	Lateral brow lift using temporal (pretrichial) subcutaneous	High satisfaction	This technique was accepted as a reliable technique for lifting lateral eyebrows with very low risk. Temporal/lateral eyebrow lift using pretrichial incision with subcutaneous dissection can be performed under local anesthesia with effective and safe results and with high patient satisfaction.	12-192
Taban (2016) (19)	USA	Retrospective	45	44 f, 1 m	37-78	Lateral subcutaneous brow lift	nr	Lateral subcutaneous brow lift was durable, and all patients were satisfied.	nr
Mahmood & Baker (2015) (11)	USA	Clinical trial	100	99 f, 1 m	33-82	subcutaneous temporal brow lift	All patients were satisfied.	The effectiveness of the eyebrow lift was also rated as "good" or "excellent" by all but one patient. In this technique, it is possible to repair all the damaged tissues around the eyes, including the forehead, eyebrows, eyelids, canthal ligaments, orbicularis muscle, malar fat, and the skin around the eyes and cheeks. This is a safe and easy technique. LSBL is a safe and simple technique with few complications and a high patient acceptance rate, and the application of this technique allowed us to achieve favorable aesthetic results around the upper periorbita.	10.8 (Mean)
Bidros et al. (2010) (20)	USA	Retrospective	28	27 f, 1 m	54	subcutaneous	nr	LSBL is a safe and simple technique with few complications and a high patient acceptance rate, and the application of this technique allowed us to achieve favorable aesthetic results around the upper periorbita.	24 (Mean)
Guerrissi (2010) (16)	Argentina	Clinical trial	144	134 f, 8 m	35-55	lateral subcutaneous brow lift (LSBL)	91%	Lateral subcutaneous brow lift was successful in raising the lateral brow permanently.	14
Bernard et al. (2006) (21)	nr	Clinical trial	31	nr	nr	lateral subcutaneous brow lift at	nr		2-40

the temporal
hairline

nr: not reported, F: female, M: male.

Table 2. Complications of subcutaneous brow lift dissection plan

Author, Year	Stitch Abscess	Complete Relapse	Transient Monolateral Palsy/ Nerve Palsy	Hematomas	Dysesthesia	Asymmetry	Reoperation	Alopecia	Pruritus	Infection	Scarring
Şibar et al. (2023) (18)	-	-	3	-	-	-	-	-	-	-	-
Pascali & Massarelli (2023) (15)	-	-	6	3	3	-	-	-	-	0	5
Savetsky & Matarasso (2020) (6)	-	-	-	3	0	0	2	2	0	0	2
Taban (2016) (19)	-	-	-	•	-	1	-	-	-	0	0
Mahmood & Baker (2015) (11)	-	-	-	•	0	-	-	-	-	0	0
Bidros et al. (2010) (20)	-	-	-	•	0	1	2	-	-	0	1
Guerrissi (2010) (16)	-	-	-	-	-	12	3	-	-	16	-
Bernard et al. (2006) (21)	-	-	-	2	6	0	-	0	-	-	0
Miller et al. (2000) (13)	-	-	-	-	0	-	-	0	0	-	0

nr: not reported

Table 3. Results of studies on subperiosteal (endoscopic) brow lift dissection plan

Author, Year	Country	Study Design	Sample size	Sex	Age (years)	Surgery Types	Patient satisfaction	Conclusion	Follow-up duration (months)
Şibar et al. (2023) (18)	Turkey	Retrospective	44	82 f, 4 m	35-67	endoscope-assisted polypropylene mesh lift (EAML)	nr	The use of this technique resulted in achieving a safe profile and eyebrow rejuvenation.	24.7 (mean)
Xu et al. (2022) (22)	China	Retrospective	97	87 f, 10 m	23-62	endoscopic brow lift	nr	Elevation of eyebrows after endoscopic lift was statistically significant in all three time periods, and patients did not complain of forehead lengthening.	6
Rohrich & Cho (2019) (23)	USA	Retrospective	71	99% f	56.6	endoscopic brow lift	nr	Endoscopic temporal lift can lift the medial and lateral eyebrows effectively and has a low side effect rate (1.4%).	7.7 (mean)
Shahmirzadi et al. (2017) (17)	Iran	Retrospective	20	18 f, 2 m	40-68	sub-periosteal endoscopic	95.2%	Endoscopic forehead rejuvenation surgery, which is used to rejuvenate the	nr

						brow lift surgery		upper third of the face, was effective and satisfactory in Iranian patients for raising eyebrows.	
Graf et al. (2008) (24)	Brazil	Retrospective	72	nr	nr	endoscopic brow lift	nr	Eyebrow lift with subperiosteal endoscopic method showed clinical and statistical effectiveness in correcting eyebrow ptosis and caused spontaneous and progressive increase of eyebrows, without increasing the distance between eyebrows.	5 (mean)

nr: not reported, F: Female, M: Male.

Table 4. Complications of subperiosteal (endoscopic) brow lift dissection plan

Author, Year	Stitch abscess	Complete relapse	Nerve palsy	Hematomas	Dysesthesia	Asymmetry	Reoperation	Alopecia	Pruritus	Infection	Scarring
Şibar et al. (2023) (18)	nr	nr	nr	nr	1	nr	nr	nr	nr	nr	nr
Xu et al. (2022) (22)	-	-	-	-	-	-	-	2	-	1	-
Rohrich & Cho (2019) (23)	-	-	-	-	-	-	1	1	-	-	-
Shahmirzadi et al. (2017) (17)	nr	nr	nr	nr	nr	nr	nr	nr	nr	nr	nr
Graf et al. (2008) (24)	nr	nr	nr	nr	nr	nr	nr	nr	nr	nr	nr

nr: not reported

Discussion

Creating the ideal shape and position of the eyebrow is an important goal in facial rejuvenation. One of the main challenges of a brow lift is to find a predictable method that balances the pros and cons of the available strategic techniques (10). Various techniques from the most invasive, like coronal brow lifting to less invasive one such as botox injection were introduced and described (23).

Miller et al. (13) performed subcutaneous lateral brow ptosis in 65 patients. Regarding side effects, light touch sensation was consistently reduced postoperatively in the central forehead but returned to normal within three months in all cases. There were no reports of reduced sensation or itching of the scalp above the incision for lateral brow lift. Additionally, alopecia was not observed, and in most patients, the hairline improved with frontal and temporal scalp advancement. Scars were acceptable because the brow lift was successful in all cases. These researchers also reported that for younger patient with lateral ptosis of the eyebrow, subcutaneous dissection allows eyebrow lift easier than a deeper incision, with no need to release the "orbital ligament" to create an effective lift. In addition, this method is useful in moderate lateral

eyebrow ptosis, although it may not be suitable for all patients.

Bernard et al. (21) performed lateral subcutaneous surgery on 23 patients with a 34-month follow-up. Alopecia and frontal nerve palsy was not seen in any of patients. All the patients regained full scalp sensation within 8 weeks. Additionally, all the patients considered their scars unrecognizable.

Guerrissi (16) studied 340 patients aged 25–55 years, using the subcutaneous technique with addition of suspension of orbicularis oculi muscle and malar fat pad to temporal oponeurosis. These researchers reported 91% satisfaction rate in patients. In terms of side effects, partial temporal wound infection was diagnosed in 16 patients (33%). Eyebrow asymmetry was reported in another 30 cases (9%), 9 cases (75%) were corrected after 3 months, and in 3 cases (25%), repetition of the surgical procedure was required.

In a study by Bidros et al. (20), the brow temporal subcutaneous technique was performed on 28 patients with an average age of 54 years. Five patients underwent unilateral eyebrow lift procedures due to asymmetry, and 23 underwent bilateral surgery. The average duration of follow-up was 10.8 months. Scarring was minimal and rated "good" or "excellent"

by patients and surgeons. The effectiveness of the eyebrow lift was also rated as "good" or "excellent" by all but one patient. Two patients underwent revision: one for scar revision and one for a higher lift. There were no cases of hematoma, infection, numbness, or excessive scarring.

A study conducted by Mahmood and Becker (11) used lateral subcutaneous method for eyebrow lift on 100 patients. The study found no associated side effects in the early postoperative period or long-term follow-up. None of the patients experienced numbness, unsightly or widened scars, or raised hairline, seromas or surgical site infections. No hematomas were observed as well. In addition, they reported a durable brow lift and overall patient satisfaction in this treatment method.

Taban (19) used the temporal/lateral eyebrow lift technique by subcutaneous dissection in 45 patients and did not observe side effects. The researcher suggested reported that this method is suitable for non-smoking patients with long hair and lateral eyebrow droop.

In the research by Savetsky and Matarasso (6), a sample of 500 patients underwent eyebrow lift by the temporal lateral subcutaneous method. No cases of permanent nerve damage or skin necrosis were reported. Patients were uniformly satisfied with their postoperative results. Out of 500 cases, there were 3 cases of hematomas/serums which necessitate aspiration, and 2 cases of shear alopecia and unfavorable scars requiring scar correction.

Pascali and Massarelli (15) evaluated the TSBL (subcutaneous brow lift) technique in 298 patients aged 22–64. They observed hematoma and dysesthesia in only 1% of patients. Scar formation was reported in five patients, and transient monolateral palsy was reported in six patients.

Şibar et al. (18) compared the gliding brow lift technique (GBL) with the endoscope-assisted polypropylene mesh lift technique (EAML) in 86 patients. These researchers finally found that both techniques were effective and similarly affected eyebrow rejuvenation. They also had similar side effects. In the EAML group, two patients had mesh irritation, and three had unilateral scalp dysesthesia. In the (GBL) group, three patients had frontal nerve palsy, one patient had dog ears in the scalp (Scar deformity), and one patient had skin pigment disorder in the early postoperative period.

Xu et al. (22) investigated the endoscopic technique in 97 patients to treat eyebrow ptosis; the drooping

eyebrows were resolved and raised effectively. Regarding complications, alopecia was observed in only two patients, with infection in three.

Rohrich and Cho (23) investigated the endoscopic technique in 71 patients to treat eyebrow ptosis. Eyebrow drooping was resolved, and medial and lateral eyebrows were effectively raised with minimal side effects (4.1%).

Shahmirzadi et al. (17) and Graf et al. (24) also evaluated the endoscopic technique to treat eyebrow ptosis in 20 and 72 patients and reported clinical and statistical effectiveness in correcting eyebrow ptosis. It should be remembered that side effects in any eyebrow lift technique are uncommon and unclear (1). It is necessary to have complete information about the choice of incision site and the risk of scarring before the procedure (25).

Typically, Asian patients tend to have more pronounced postoperative scarring. Patients undergoing surgery should be fully aware of the possible postoperative scar and the subsequent methods for its treatment. Skillful suturing and tension lifting can reduce the severity of the scar (25). In subcutaneous dissection, the skin extends to the outer third of the eye muscle (orbicularis oculi) and the lateral canthal ligament. Since this dissection plan is more superficial than the plan where the frontal branch of the facial nerve is located, damage to the nerve can be avoided (16).

In patients with drooping lateral eyebrows, subcutaneous temporal or lateral eyebrow lift has resulted in stable and effective results. This technique is well described in the literature and offers several advantages, including shorter operation time, the possibility of performing under local anesthesia, reducing the risk of hairline elevation, unclear scars, and decreased risk of dysesthesia and numbness of the scalp after surgery (11). The most satisfying aspect of the subcutaneous technique is rejuvenating the periocular wrinkles and preserving the original youthful identity of the patient (15). The best indications for endoscope-assisted eyebrow lift are patients with short or normal forehead height, flat forehead, and those with no receding hairline and a minimal amount of excess skin medially (26). On the other hand, endoscope-assisted eyebrow lift offers the advantage of being minimally invasive and a high recurrence rate (23). On the contrary, patients with a long forehead, convex forehead, deep rhytids, thick skin, and medial excess skin have a weak indication for eyebrow lift with the endoscopic technique (26).

One of the important things is that the Asian face shows differences in facial structure and beauty standards. It should be noted that Asian faces usually have wider, shorter, and more squarefaces than Westerns (25). Patients wish for a better-positioned eyebrow with long-lasting natural beauty and lift (1, 27). Therefore, success in modern eyebrow lift surgery depends on raising the eyebrow and improving or maintaining the shape of the eyebrow (26). Visibility of scars and intraoperative issues (such as the use of anesthesia and operation time [(surgery and anesthesia)], and operation costs influence the patient's final decision. Diagnosing the patient's characteristics and matching them with the appropriate method for eyebrow lift can have the maximum effect on beauty (1, 27).

Conclusion

The subcutaneous dissection method is a reliable, safe, cheap, and repeatable option for lateral eyebrow lift. Conducting clinical studies with standardization of outcome criteria in eyebrow rejuvenation is recommended. The endoscopic method has the same effectiveness for the eyebrow lift and offers the advantage of being minimally invasive.

Acknowledgments

The authors express their gratitude to the Craniomaxillofacial Research Center of the Faculty of Dentistry, Tehran University of Medical Sciences, for supporting this study.

Conflict of Interests

The authors of this manuscript declare that they have no conflicts of interest, real or perceived, financial or non-financial in this article.

References

- de Jongh FW, Sanches EE, Pouwels S, Kooiman LBR, Wehrens KME, van Heerbeek N, et al. An overview of surgical techniques and non-surgical treatments in lifting the eyebrow including current treatments available. *Eur J Plast Surg.* 2023;46(1):1-8.
- Karimi N, Kashkouli MB, Sianati H, Khademi B. Techniques of Eyebrow Lifting: A Narrative Review. *J Ophthalmic Vis Res.* 2020;15(2):218-35.
- Miranda RED, Matayoshi S. Surgical and non-surgical procedures for eyebrow lift: systematic review and decision flowchart. *Revista Brasileira de Cirurgia Plástica.* 2023;34:539-45.
- Omran D, Tomi S, Abdulhafid A, Alhallak K. Expert Opinion on Non-Surgical Eyebrow Lifting and Shaping Procedures. *Cosmetics.* 2022;9(6):116.
- Beck H, Egger K, Koller R. One-year sustainability of brow-lifting procedures. *J Plast Reconstr Aesthet Surg.* 2023;77:456-63.
- Savetsky IL, Matarasso A. Lateral Temporal Subcutaneous Brow Lift: Clinical Experience and Systematic Review of the Literature. *Plast Reconstr Surg Glob Open.* 2020;8(4):e2764.
- Matarasso A, Terino EO. Forehead-brow rhytidoplasty: reassessing the goals. *Plast Reconstr Surg.* 1994;93(7):1378-89; discussion 90-1.
- Farhadi H, Rezaei E, Shojaebabaei G. Modification of temporal brow lift procedure with transillumination. *Eur J Plast Surg.* 2023;46(6):979-84.
- Sundine MJ, Connell BF. The Open Browlift. *Facial Plast Surg.* 2018;34(2):128-38.
- Viterbo F, Auersvald A, O'Daniel TG. Gliding Brow Lift (GBL): A New Concept. *Aesthetic Plast Surg.* 2019;43(6):1536-46.
- Mahmood U, Baker JL, Jr. Lateral Subcutaneous Brow Lift: Updated Technique. *Aesthet Surg J.* 2015;35(5):621-4.
- Matarasso A, Smith D. Current trends in browlift and forehead rejuvenation. *International Society of Aesthetic Plastic Surgery (ISAPS).* 2016;10:35-42.
- Miller TA, Rudkin G, Honig M, Elahi M, Adams J. Lateral subcutaneous brow lift and interbrow muscle resection: clinical experience and anatomic studies. *Plast Reconstr Surg.* 2000;105(3):1120-7.
- Farhadieh, Bulstrode, Mehrara, Cugno S. Plastic surgery - principles and practice. Farhadieh R, Bulstrode N, Mehrara BJ, Cugno S, editors. Philadelphia, PA: Elsevier - Health Sciences Division; 2021.
- Pascali M, Massarelli O. The Temporal Subcutaneous Brow Lift with Orbicularis Oculi Muscle Elastic Flap: Technical Considerations, Systematic Review, and Terminology Standardization. *Facial Plast Surg.* 2023;39(6):691-702.
- Guerrissi JO. Periorbital rejuvenation: a safe subcutaneous approach to forehead, eyebrow, and orbicularis oculis muscle mobilization. *Aesthetic Plast Surg.* 2010;34(2):147-52.
- Shahmirzadi AAR, Fathi HR, Ghanbarzadeh K, Davudov M, Khorasani G. Brow Position after Endoscopic Brow Lift. *Iran Red Crescent Med J.* 2017;19(5):e44180.
- Şibar S, Erdal AI, Deniz E, Kılıç Ö, Tuncer S. Comparison of the effectiveness and safety of the "endoscope-assisted polypropylene mesh lift" and "gliding brow lift" techniques for the treatment of lateral brow ptosis. *J Plast Reconstr Aesthet Surg.* 2023;83:455-62.
- Taban MR. Lateral browlift using temporal (pretrichial) subcutaneous approach under local anesthesia. *Am J Cosmetic Surg.* 2016;33(3):116-20.
- Bidros RS, Salazar-Reyes H, Friedman JD. Subcutaneous temporal browlift under local anesthesia:

- a useful technique for periorbital rejuvenation. *Aesthet Surg J.* 2010;30(6):783-8.
21. Bernard RW, Greenwald JA, Beran SJ, Morello DC. Enhancing upper lid aesthetics with the lateral subcutaneous brow lift. *Aesthet Surg J.* 2006;26(1):19-23.
 22. Xu L, Lee EI, Ma T, Zhang J, Han X, Ahn TJ. Aesthetic Analysis of Alteration of Eyebrow and Forehead Position After Endoscopic Eyebrow lift. *Aesthetic Plast Surg.* 2022;46(5):2258-65.
 23. Rohrich RJ, Cho M-J. Endoscopic temporal brow lift: surgical indications, technique, and 10-year outcome analysis. *Plast Reconstr Surg.* 2019;144(6):1305-10.
 24. Graf RM, Tolazzi ARD, Mansur AEC, Teixeira V. Endoscopic periosteal brow lift: evaluation and follow-up of eyebrow height. *Plast Reconstr Surg.* 2008;121(2):609-16.
 25. Wang G, Zhao R, Bi R, Xie H. Subcutaneous Face and Neck lift: A Traditional Method With Definite Effects Among Asians. *Aesthet Surg J.* 2021;41(12):Np1890-903.
 26. Zins JE, Coombs DM. Endoscopic Brow Lift. *Clin Plastic Surg.* 2022;49(3):357-63.
 27. Miller TA. Lateral subcutaneous brow lift. *Aesthet Surg J.* 2003;23(3):205-10.