



ORIGINAL ARTICLE

The Effect of Bisphosphonates' Oncologic dose on the Static and Dynamic Bone Parameters of the Temporomandibular Joint's Condyle (A Randomized Animal Controlled Trial)

Israa A Radwan¹, Samah Mehanny², Marwa MS Abbass^{*3}

¹Lecturer, Oral Biology Department, Faculty of Dentistry, Cairo University, Egypt

²Professor, Oral Biology Department, Faculty of Dentistry, Cairo University, Egypt

³Associate Professor, Oral Biology Department, Faculty of Dentistry, Cairo University, Egypt

(Received: 13 August 2020

Accepted: 29 September 2020)

KEYWORDS

Zoledronic acid;
TMJ;
Bone remodeling;
Static and dynamic;
Bone parameter

ABSTRACT: The present study was conducted to assess the effect of oncologic dose of bisphosphonate on the condylar temporomandibular joint's (TMJ's) static and dynamic bone parameters. Forty adult male albino rats were utilized in the study. Animals were randomly assigned into four groups, each included ten rats that were intraperitoneally injected with saline (control groups I and II), or 0.2 mg.kg⁻¹ Zoledronic acid (experimental groups I and II). The rats were sacrificed at the end of 6 weeks (groups I) and 12 weeks (groups II). The right side TMJs condyles were used in histological and histomorphometric analysis while the left side condyles were utilized for assessing dynamic bone parameters. Bone volume/ Tissue volume (BV/TV) and trabecular thickness (Tb.Th) were significantly increased in ZOL group II as compared to control and Zoledronic acid (ZOL) group I ($p < 0.001$) while trabecular separation (Tb.Sp) was markedly increased in ZOL group I as compared to both control and ZOL group II ($p = 0.001$ and 0.012 , respectively). The ZOL group II showed a significant increase in mineral apposition rate as compared to the ZOL group I ($p < 0.001$). Our results demonstrated that oncologic dose of Zoledronic could have a catabolic effect on TMJ's condyles after six weeks which is reversed after 12 weeks as evidenced by enhanced endochondral and intramembranous ossification.

INTRODUCTION

The innumerable functions of bone can be jeopardized by number of disorders that affect the structural and functional integrity of bone. The ability of the skeletal system to provide its supportive, protective, ambulatory functions as well as its function as a reservoir for mineral and growth factor storage and its blood cell formation functions can be greatly hindered by number of systematic diseases [1]. Diseases which may affect the bone can be broadly classified into metabolic bone

diseases as Paget's disease, hyperparathyroidism, hyperthyroidism, hypothyroidism, hypophosphatasia, and acromegaly. Genetic abnormalities as cherubism, osteopetrosis, osteogenesis imperfecta, and cleidocranial dysplasia. Developmental disorders as fibrous dysplasia, dystrophic bone disease as osteoporosis, inflammatory bone diseases as osteomyelitis, nutritional deficiency disorders as rickets, osteomalacia and scurvy as well as malignant lesions of the bone as osteosarcoma [2].

*Corresponding author: marwa.magdy@dentistry.cu.edu.eg (M. MS. Abbass)
DOI: 10.22034/jchr.2020.1906596.1165

Several options are available for the management of bone diseases among which are anti-resorptive medications such as bisphosphonates (Bps) [3, 4], anabolic agents, and combination therapy [5, 6]. Bps are the most used anti-resorptive drugs for the treatment of osteoporosis. Their chemical structure contains two phosphate groups with a core of phosphate-carbon-phosphate atoms (P–C–P bond) and two R side-chains [7, 8]. Bps, owing to their high affinity to hydroxyl apatite, can attach to the hydroxyl apatite at sites of active bone resorption, to be slowly released during subsequent bone remodeling. This can account for the slow elimination and consequently extended inter dosage durations of Bps [9–11]. Bps' family includes non-nitrogen bisphosphonates and nitrogen BPs (N-Bps) which contain N group in the R side chain. N-Bps include alendronate (ALN), ibandronate, risedronate and zoledronate. N-Bps are more commonly used for osteoporosis treatment [12,13]. Zoledronic acid (ZOL) is a third generation N-Bps, with a great affinity for bone surface [14–16]. It is considered as one of the most potent Bps, owing to its strong ability to inhibit osteoclast function [17,18]. ZOL is usually prescribed as a single yearly dose of 5mg via intravenous injection [19]. Authors agree that patients are more likely to comply with yearly dosage of ZOL than with the frequent dosages of oral Bps [20, 21]. ZOL is successfully used for the management of postmenopausal osteoporosis [20–28], osteoporosis in men [29], and glucocorticoids induced osteoporosis [30]. Furthermore, ZOL can be administered as an adjunctive to anti-tumour therapy. The conventional oncologic dose of ZOL is 4mg administered intravenously every 3–4 weeks [31, 32]. Oncologic dose of ZOL can successfully control hypercalcemia and skeletal complications associated with bone metastases secondary to malignant tumours as multiple myeloma or malignancies of breast or prostate [33]. ZOL also has anti-angiogenic properties in vivo [34] and can help alleviate pain associated with bone metastasis [35, 36] which can further endorse its use alongside anti-tumour drugs.

ZOL is generally considered as a safe drug when used in low doses for osteoporosis treatment [37]. However, the administration of high or oncological dosages of ZOL can carry the risk of inducing Bps related osteonecrosis of the jaw [38]. Bps related osteonecrosis of the jaw can

be defined as an exposed bone area in the maxillofacial region, with no prior radio-therapy history, that does not resolve within eight weeks in a patient on Bps treatment [39]. Bps related osteonecrosis of the jaw is linked to the suppressive effect of Bps on bone remodelling. Defective osteoclast function and inadequate bone repairing mechanism can result in bone necrosis [40].

The current study was conducted to assess the effect of oncologic dose of zoledronic acid on static and dynamic bone parameters of TMJ condyles in rats.

MATERIALS AND METHODS

Experimental Procedures

Forty adult male albino rats with an average weight of about 200-250 gm were used in this study. All the experimental procedures were conducted in the animal house, Faculty of Medicine, Cairo University, Egypt, according to the recommendations of the Institutional Animal Care and Use Committee (IACUC), Cairo University. Animals were housed individually in wire mesh cages. They were fed a standard pelleted diet and tap water *ad-libitum*. Temperature and humidity conditions were controlled during the experimental period.

The animals were assigned randomly into control groups (n=20) sacrificed either after 6 weeks (n=10) or 12 weeks (n=10) (control group I and control group II, respectively) and ZOL groups (n=20) sacrificed either after 6 weeks (n=10) or 12 weeks (n=10) (ZOL group I and ZOL group II, respectively). The results of both intervals of the control group were averaged and used as a single value for each sample.

ZOL (Zometa®, Novartis Pharma AG, Basel, Switzerland) was administered as weekly intraperitoneal injection of 0.2 mg.kg⁻¹ body weight [41]. The solution was prepared by dissolving 4 mg ZOL powder in 100 ml sterile saline, each rat received 0.04 mg/ml. The control group rats received weekly intraperitoneal injection of 1 ml of saline. For determining the dynamic bone parameters, bone labelling was performed with 0.5 ml intravenous injection of oxytetracycline for two days consecutively, one week prior to the experiment and one week before sacrifice the same protocol used for labelling by calcein [42].

Rats were sacrificed with ketamine overdose either after 6 or 12 weeks from the beginning of the experiment. The heads were sagittally dissected, fixed in 10% neutral formalin for 48 h. Both right and left TMJ were used, the right side TMJs condyles were used in histological and histomorphometric analysis while the left side condyles were utilized for assessing dynamic bone parameters.

Light microscopic examination

The right side TMJs condyles from each experimental group were washed and soaked in 10% ethylene diamine tetra-acetic acid (EDTA) for 4-5 weeks for decalcification. The specimens were dehydrated in ascending grades of alcohol following decalcification, then cleared in xylol and embedded in paraffin blocks. Sections of 4-5 μ thickness were mounted on ordinary glass slides and stained by Hematoxylin and Eosin (H&E) for routine histological evaluation according to the conventional method.

Fluorescence microscopic examination for dynamic bone parameters

After fixation, the left side condyles were washed, dehydrated, and ground sections were prepared. The specimens were grinded to 0.1 mm (100 μ m) thickness. After that, specimens were cleaned, dried, and mounted on slides to be examined with fluorescence microscope. Fluorescent microscope was used to identify the fluorescent labelled mineralization front [43].

Histomorphometric analysis for static and dynamic bone parameters

In the hematoxylin and eosin stained sections, Fiji image J (image analysis software) [44] with trainable Weka segmentation [45] and bone J [46] plugins, were used to analyze static and dynamic bone parameters. Image analysis was performed on images acquired with X10 magnification. Ten fields were measured from each sample and the mean values were calculated.

Bone volume (BV) to tissue volume (TV), trabecular thickness (Tb.Th), trabecular separation (Tb.Sp), eroded surface to bone surface (ES/BS), and osteoblast surface to bone surface (OB/BS) were directly measured

[43,47,48], while trabecular number (Tb.N) was measured indirectly using the following equation [49]:

$$Tb.N = \frac{(BV/TV)}{Tb.Th}$$

Mineral appositional rate (MAR) which is the distance between the edges of two fluorescent labels divided by the time between the labels [43], was measured in the images acquired using a fluorescent microscope.

Statistical analysis

Values were presented as mean and standard deviation (SD). Kolmogorov-Smirnov test of normality was used to explore data normality. The results of the Kolmogorov-Smirnov test indicated that data were normally distributed. One-way analysis of variance (ANOVA) test was used to assess significance between groups, this was followed by Tukey's post hoc test when ANOVA yielded a significant difference. The significance level was set at $p < 0.05$. Statistical analysis was performed with SPSS 18.0 (Statistical Package for Scientific Studies, SPSS, Inc., Chicago, IL, USA) for Windows.

RESULTS

Light microscopic examination

Control group

The head of the rat's TMJ condyle consisted of spongy bone with radiating trabeculae to the cortex. The bony trabeculae appeared as interconnecting plates lined by osteoblasts along their borders and with entrapped osteocytes (Figure A).

A layer of hyaline cartilage could be distinguished with its characteristic oval shaped chondrocytes. The head was covered with a relatively thick layer of fibro-cartilaginous tissue. Regularly arranged fibroblasts oriented parallel to each other and to the joint cavity could be observed together with many dispersed chondrocytes (Figure 1A, B). The marrow spaces were filled with fibro-cellular tissue and were lined with osteoblasts (Figure C).

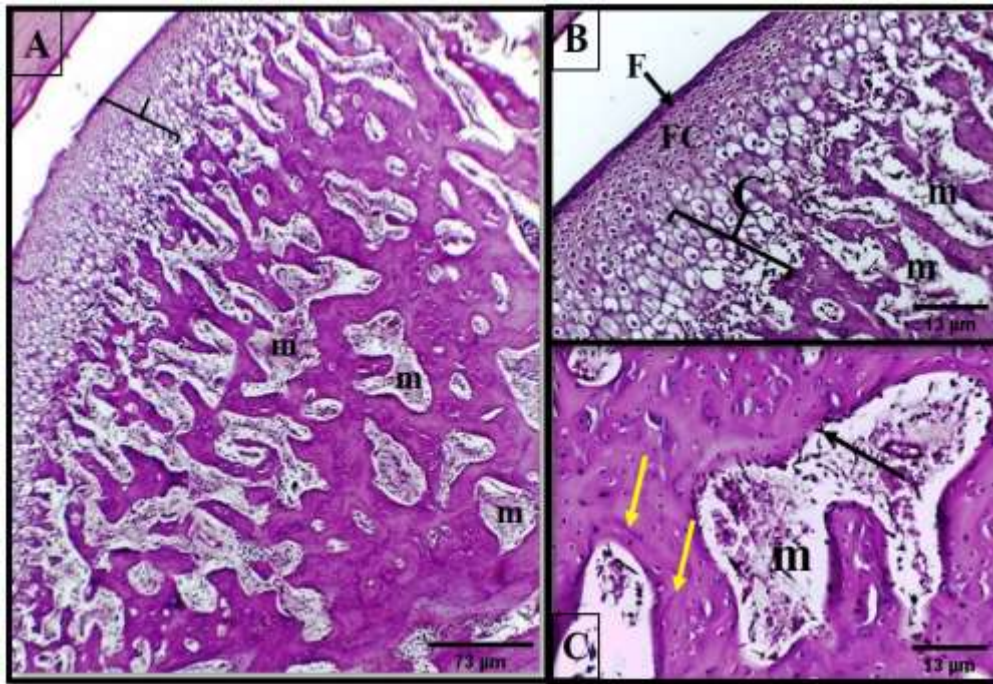


Figure 1. A photomicrograph of the condylar TMJ of control group showing; (A) Mandibular condyle composed of interconnected plates of spongy bone with its articulating surface covered by a thick layer of fibrocartilagenous tissue (bracket). (H&E staining. Scale bar represent 73µm)(B) A relatively thick layer of fibrocartilagenous tissue composed of fibrous layer (F), fibrocartilagenous layer (FC) and underlined by a layer of hyaline cartilage (C). (H&E staining. Scale bar represent 13µm)(C) Spongy bone with interconnecting bone trabeculae lined by osteoblasts (black arrow), enclosing marrow spaces (m), resting lines (yellow arrows) and osteocytes in their lacunae. (H&E staining. Scale bar represent 13µm)

ZOL group I (6 weeks)

The head of the condyle revealed marked thickening of the fibrous layer while thinning of the cartilaginous layer (Figure 1A). At the thin layer of hyaline cartilage, the chondrocytes displayed pleomorphism. In the deeper layers, they appeared spherical or ovoid and in the superficial layers; flattened or discoid. Some chondrocytic lacunae were completely empty; others were filled with amorphous material. In some lacunae, bone like material could be detected either partially or entirely filling them (Figure 1A, B).

The subchondral bone revealed widened marrow spaces enclosing vascular-cellular elements (Figure 1A, C). Thin

branching trabeculae with few entrapped osteocytes that appeared dispersed in widened lacunae; in some areas, the osteocytes lacunae completely disappeared (Figure 1). The architecture of the bone trabeculae exhibited abnormality regarding the presence of cracking and an enormous number of irregularly oriented reversal lines (Figure 1A, B). The bone trabeculae lost their regular osteoblastic lining except in focal dispersed areas, where the osteoblasts could be seen partially outlining their boundaries (Figure 1). Bone sequestration could be seen with small, detached pieces of necrotic bone (Figure 1A, C).

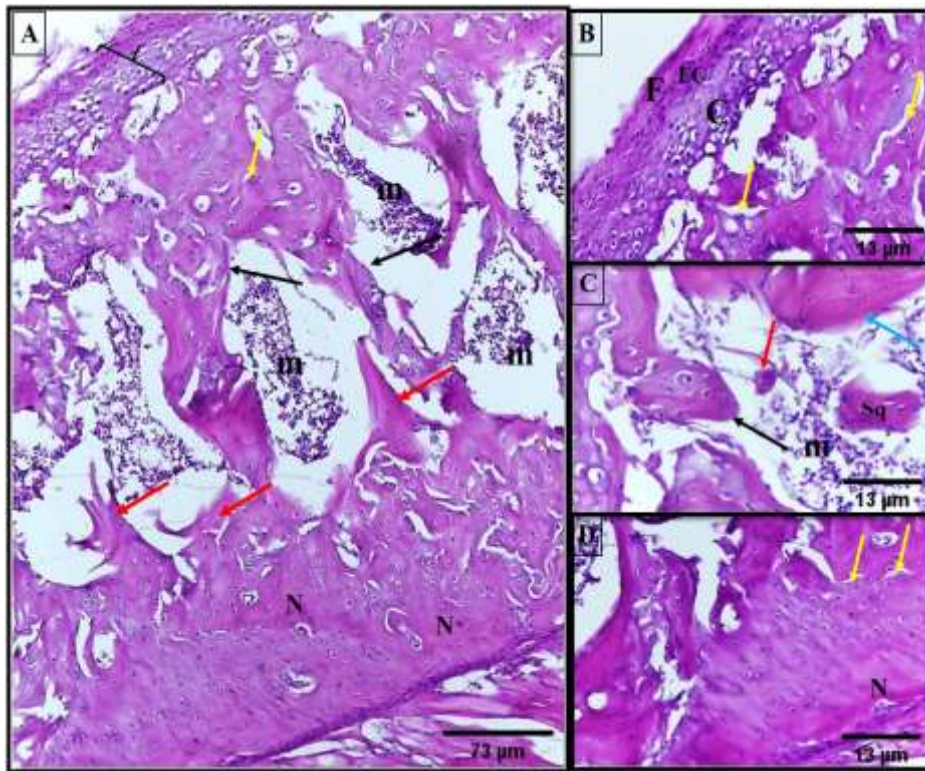


Figure 1. A photomicrograph of TMJ's condyle of ZOL group I (6 weeks) showing:(A) Atypical histology of the condylar head with extremely widened and interconnected marrow spaces (m), enclosing cellular elements with apparent loss of the osteoblastic lining (black arrows), cracks (yellow arrow), areas of necrotic (N) and punched or teared bone (red arrows). (H&E staining. Scale bar represent 73μm) (B) Apparent thickening of the fibrous lining (F) of the articular surface with decrease of the fibrocartilaginous (FC) and cartilaginous layers (C), multiple cracks (yellow arrows). (H&E staining. Scale bar represent 13μm)(C) Widened marrow space (m) occupied with cellular and vascular tissue enclosing sequestered bone (Sq); in some bone trabecula, few entrapped population of degenerated osteocytes (blue arrows); in other areas, complete loss of osteoblasts outlining bone boundaries (black arrows) as well as detached osteoclast (red arrow). (H&E staining. Scale bar represent 13μm)(D) Necrotic bone (N) and cracks (yellow arrows). (H&E staining. Scale bar represent 13μm)

ZOL group II (12 weeks)

After 12 weeks from ZOL administration, the fibrous layer and the fibrocartilaginous layer displayed marked thickening with a relative increase in the thickness of the cartilaginous layer (FigureA, B). The cartilage cells also displayed pleomorphism and appeared spherical or ovoid (FigureA, C). The cartilage cells undergo endochondral ossification (FigureA, C).

The head of the condyle revealed increase in the trabecular thickness with narrowing of the marrow spaces enclosing highly cellular elements (FigureA, C). The thick bone trabeculae revealed multiple randomly

arranged large sized osteocytes. The bone trabeculae denoted a high bone formation rate in the form of multiple resting lines as well as unduly calcified bone matrix that took intensely the haematoxylin stain with islands of woven bone (FigureA, D). The marrow spaces were bounded with resting osteoblasts while many active osteoblasts appeared to be newly differentiated within the bone marrow and begin to lay bone matrix (FigureC).

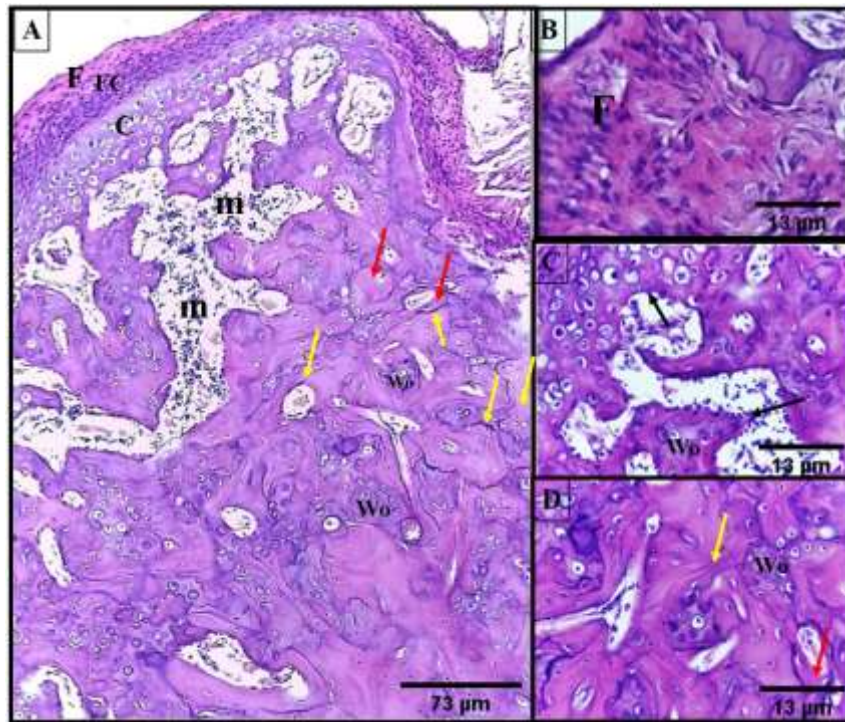


Figure 3. A photomicrograph of TMJ's condyle of ZOL group II (12 weeks) showing: (A): A well-developed fibrous (F) and fibrocartilaginous layer (FC) with a relative increase in the cartilaginous layer (C). New bone formation in the form of woven bone (Wo), intramembranous bone matrix (red arrows) surrounding marrow spaces (m) and multiple resting lines (yellow arrows). (H&E staining. Scale bar represent 73µm) (B): Apparent thickening of the fibrous covering (F) of the condyle. (H&E staining. Scale bar represent 13µm) (C): Marrow space (m) occupied with highly cellular elements and osteoblastic lining (black arrows), woven bone (Wo) and endochondral ossification. (H&E staining. Scale bar represent 13µm) (D): Woven bone (Wo) with irregular pattern of bone trabeculae with haphazardly entrapped large sized osteocytes, newly formed bone matrix partially bordering the marrow spaces (red arrows), resting lines (yellow arrow). (H&E staining. Scale bar represent 13µm)

Histomorphometric results

The histomorphometric results of static and dynamic bone parameters are presented as means \pm standard deviation (\pm SD) in Tables 1, 2 and Figure 3

Static bone parameters

Bone volume/ Tissue volume (BV/TV) and Trabecular thickness (Tb.Th)

A significant increase in mean BV/TV and Tb.Th was detected at the ZOL group II (12 weeks) as compared to both control and ZOL group I ($p < 0.001$). On the contrary, a non-statistically significant difference was detected between the control and the ZOL group I (6 weeks) in the previously mentioned parameters ($p = 0.62$ and $p = 0.81$, respectively).

Trabecular separation (Tb.Sp)

A significant increase in mean Tb.Sp was recorded at the ZOL group I (6 weeks) as compared to both the control and the ZOL group II (12 weeks) ($p = 0.001$ and 0.012 , respectively). A non-statistically significant difference was detected between the control group and ZOL group II (12 weeks) ($p = 0.677$).

Trabecular number (Tb.N)

The highest mean trabecular number was evident in the control group with a statistically significant difference with the ZOL groups I and II ($p = 0.034$ and $p = 0.003$, respectively). While no statistically significant difference was detected between the ZOL groups I and II ($p = 0.662$).

Osteoblasts surface to bone surface (Ob/BS) and eroded surface to bone surface (ES/BS)

Control group showed the highest mean osteoblasts surface to bone surface followed by the ZOL group II (12 weeks) (0.6050 and 0.5556, respectively) with a statistically significant difference between the groups

($p < 0.001$). No significant difference was detected between the control group and the ZOL group II ($p = 0.235$).

On the contrary, the ZOL group I (6 weeks) revealed the highest mean eroded surface to bone surface with an overall statistically significant differences between all the groups ($p < 0.001$).

Table 1. The static bone parameters.

		Mean	Std. Dev	Std. Error	95% Confidence Interval for Mean	F	Sig.
BV/TV	12 weeks	0.8171 ^a	0.1184	0.0265	(0.7575, 0.8767)	24.89	<0.001*
	6 weeks	0.5424 ^b	0.1641	0.0367	(0.4828, 0.6020)		
	Control	0.5818 ^b	0.1107	0.0247	(0.5222, 0.6414)		
Trabecular thickness (Tb.Th)	12 weeks	70.7 ^a	54.4	12.2	(56.3, 85.1)	11.81	<0.001*
	6 weeks	31.45 ^b	10.34	2.31	(17.07, 45.82)		
	Control	25.15 ^b	5.27	1.18	(10.77, 39.53)		
Trabecular separation (Tb.Sp)	12 weeks	25.51 ^b	17.59	3.93	(13.88, 37.13)	7.99	0.001*
	6 weeks	49.82 ^a	40.92	9.15	(38.19, 61.44)		
	Control	18.57 ^b	6.21	1.39	(6.94, 30.19)		
Tb.N	12 weeks	16.44 ^b	8.27	1.85	(13.38, 19.50)	6.38	0.003*
	6 weeks	18.32 ^b	6.39	1.43	(15.25, 21.38)		
	Control	23.87 ^a	5.56	1.24	(20.81, 26.93)		
Ob/BS	12 weeks	0.5556 ^{a,c}	0.0720	0.0161	(0.5131, 0.5981)	50.84	<0.001*
	6 weeks	0.3217 ^b	0.0836	0.0187	(0.2792, 0.3642)		
	Control	0.6050 ^a	0.1218	0.0272	(0.5625, 0.6475)		
ES/BS	12 weeks	0.1517 ^b	0.0545	0.0122	(-0.0754, -0.0114)	51.86	<0.001*
	6 weeks	0.1951 ^a	0.0458	0.0102	(-0.1648, -0.1008)		
	Control	0.06228 ^c	0.01549	0.00346	(-0.1214, -0.0575)		

Dynamic bone parameters

Mineral apposition rate (MAR) (um/day):

The ZOL group II showed a statistically significant decrease in mineral apposition rate as compared to the

control and the ZOL group I ($p < 0.001$). (Figure 2, Table 2, Figure 3

)

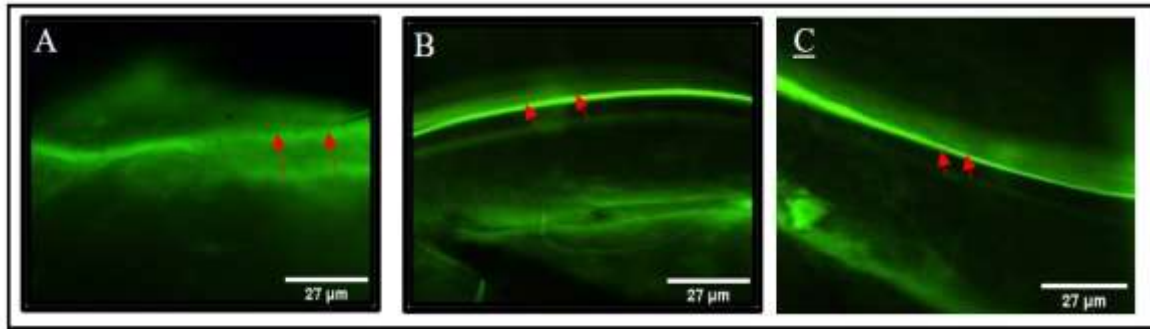


Figure 2. A tetracycline-fluorescence labelling of TMJ condyles showing the mineral apposition rate (MAR) in control group (A), ZOL group I (6 weeks) (B), ZOL group II (12 weeks) (C). (Tetracycline, Scale bars represent 27µm)

Table 2. Dynamic bone parameters

	Mean	Std. Dev	Std. Error	95% Confidence Interval for Mean	F	Significant
12 weeks	2.7917 ^b	0.2501	0.0559	(2.2889, 3.2946)		
6 weeks	4.933 ^a	1.320	0.295	(4.430, 5.436)	50.82	<0.001*
Control	5.752 ^a	1.407	0.315	(5.250, 6.255)		

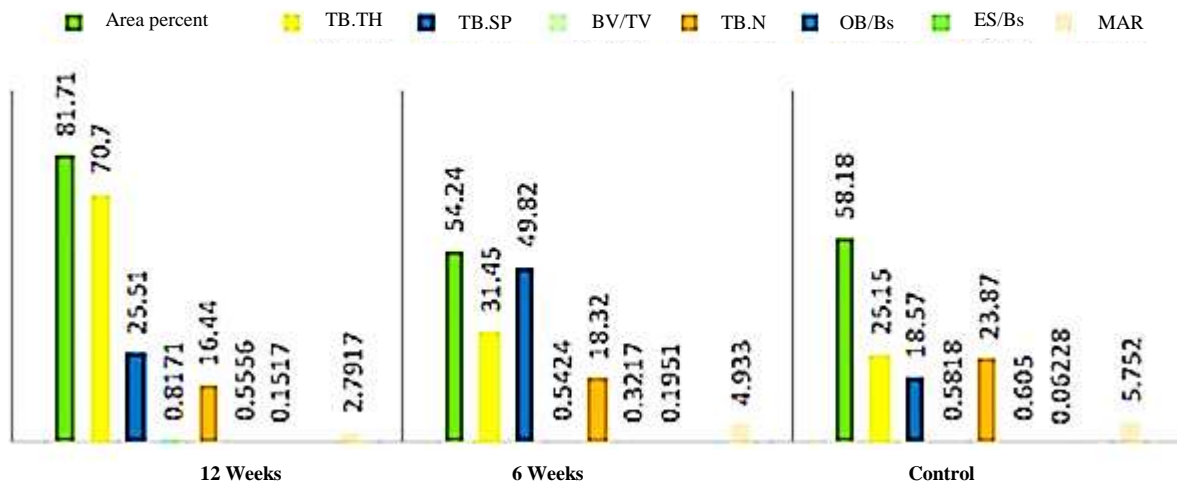


Figure3. Static and dynamic bone parameters.

DISCUSSION

ZOL is a third generation N-Bps used as an adjunctive treatment in cancer therapy to reduce skeletal effect of bone metastases [50], cancer related hypercalcemia [33], and can also help alleviate pain associated with bone metastasis [35,36]. Through the current study, ZOL was administered in oncologic dose at two intervals 6 weeks and 12 weeks to investigate its effect on mandibular condylar bone static and dynamic parameters.

In the present study, following 6 weeks of ZOL treatment, the subchondral TMJ bone revealed widened marrow spaces with thin branched trabeculae that entrapped few osteocytes in wide lacunae. Osteocytes completely disappeared in some areas, bone sequestration with small, detached pieces of necrotic bone were observed in some areas denoting Bps related osteonecrosis of the jaw. These findings coincide with

those reported by Silva et al., [51], who noticed Bps-related osteonecrosis of the jaw and increase in radiolucent areas in Wister rats after treatment with 0.2 and 1.0 mg.kg⁻¹ ZOL for four weeks. However, bone degeneration was relatively reversed in our study in the ZOL group II (12 weeks) due to new endochondral and membranous bone formation.

According to the histomorphometric results of the current study, a net catabolic effect has been recorded following treatment by ZOL for six weeks. This is indicated by the significant increase in Tb.Sp. and eroded surface to bone surface in this group as compared to the control or ZOL (12 weeks) group which could be attributed to Bps related osteonecrosis of the jaw. The exact mechanism by which ZOL can induce osteonecrosis of the jaw is not yet clear. The decreased bone turnover due to Bps inhibitory action on bone resorption secondary to Bps effect on osteoclasts [52] has been suggested as a primary mechanism involved in the development of Bps related osteonecrosis of the jaws [51]. Moreover, inflammation has also been implicated in pathogenesis of Bps related osteonecrosis of the jaws. Rats treated with 0.2 and 1.0 mg.kg⁻¹ doses of ZOL showed an increase in lymphocytes, neutrophils, and monocytes in post-extraction bone site. This lymphocytosis occurs secondary to the release of pro-inflammatory cytokines (interferon- γ , interleukins (IL) 1 α , 2, 6, 10, tumor necrosis factor alpha (TNF α), C-X-C Motif Chemokine Ligand 1 (CXCL1) and monocyte chemoattractant protein) [51]. Additionally, N-Bps were found to have a direct inhibitory action on bone-forming cells viability and alkaline phosphatase activity in vitro, low doses of both ALN and ZOL rapidly increased the release TNF α and IL-1 β , as well as dickkopf WNT signalling pathway inhibitor 1 (DKK 1) and sclerostin, both inhibitors of osteoblastogenesis. Moreover, ALN and 10⁻⁷ M of ZOL decreased the expression of type I collagen and osteopontin, while both drugs slightly stimulated secreted protein, acidic and rich in cysteine (SPARC) production [53]. Osteopontin is a non-collagenous bone matrix protein essential for regulation of bone remodeling. It is implicated in inhibition of hydroxyapatite growth and bone mineralization [54]. The latter findings support and explain the recorded absence of osteoblastic linings as well the widened marrow

cavities in ZOL group I (6 weeks) in the present study. Nevertheless, these mediators level is time and dose dependent, as their levels decreased from day 3 to day 7 [53].

Unlike results reported in the current study, ZOL administration to mice at weekly dose of 0.5 mg.kg⁻¹ weekly for 3 weeks was associated with significant increase in bone mineral density and bone mineral content, significant increase in BV/TV, Tb.N, and decreased Tb.Sp, as well as significant decrease in serum markers of osteoblast and osteoclasts reflecting the ability of ZOL to suppress bone remodeling compared with controls [55]. This contradiction can be attributed to different dosage scheme used in our study.

A significant increase in ES/BS while a significant decrease in the Ob/BS in the ZOL group I (6 weeks) as compared to both the control and the ZOL group II (12 weeks) have been recorded through the ongoing study. This denoted a relative transient increase in osteoclastic action and in upregulation of Receptor activator of nuclear factor kappa-B ligand (RANKL)/osteoprotegerin (OPG) axis which might be referred to the initial increase in the inflammatory mediators during this time lap.

Through the current study, the administration of ZOL for 12 weeks was associated with a significant increase in static bone parameters BV/TV, Tb.Th, Ob/BS and a significant decrease in ES/BS and MAR as compared to the control and ZOL group I (6 weeks). These findings indicate that the increase in the bone volume observed in the 12 weeks group the current study is attributed to ZOL bone resorption suppression as a result of osteoclasts inhibition, which subsequently surpass the osteoblasts activation and cause new bone formation.

Preclinical studies have demonstrated the efficacy of ZOL as an adjunctive treatment for bone metastasis. Oncological dose of ZOL induced osteosclerosis and was associated with improved bone histomorphometric parameters and disrupted osteoclasts function in rats with lymph node and lung cell tumor bone metastasis [56]. ZOL also effectively reduced bone resorption and increased bone density in osteosarcoma rat model [57]. Furthermore, ZOL significantly increased bone volume, trabecular number, and significantly reduced osteoclasts number in rats injected with breast cancer cells [58]. The effect of oncologic dose of ZOL on bone architecture

was previously studied by Camacho-Alonso et al. Rats receiving weekly dose of 0.2 mg.kg⁻¹ ZOL for 1, 2 or 3 weeks displayed significantly higher fracture resistance in mandibular condyle and femur head. The mandibular condyle displayed a higher calcium and phosphorous content as compared to the control group [59]. Furthermore, administration of ZOL oncologic dose for 3 and 6 months were associated with significant reduction in dogs' mandible MAR and bone remodelling as compared to control [60] which coincide with findings reported in the current study as despite the significant increase in the static bone parameter in the ZOL group II in our study, the newly formed bone wasn't qualitatively mineralized as revealed in the haematoxylin stained bone matrix which indicated less mineral content. Similar improvement in static bone parameters while reduction in MAR results were attained upon administration of ZOL to OVX monkeys. The decreased MAR rate at ZOL group II could be attributed to the difference structure-related remodelling rate between the cancellous bone and cortical bone [61]. Interestingly, ZOL administered to rats at a dose of 0.1 mg.kg⁻¹ for 2 months significantly increased the volume of fibrous cartilage of the condyle [62].

Several clinical studies further endorsed the efficacy of ZOL as an adjunctive treatment for bone metastases. ZOL was associated with increase in bone mineral density, trabecular bone score and reduced skeletal complications in women with bone loss induced by breast cancer treatment [63–65], in addition to reduced complications related to bone metastases secondary to prostate cancer in men [66, 67] and secondary to tumours other than breast or prostate cancer [68].

The current reported findings reflect the mode of action of ZOL upon both short and long term exposure. ZOL is associated with a primary increase in the level of inflammatory mediators [53] which is associated with increased RANK expression and active bone resorption associated with a direct inhibitory action on bone-forming cells [53]. ZOL administration is also associated with reduction in bone remodelling by disrupting osteoclasts morphology [69] in addition to exerting an inhibitory effect on osteoclast cell function [70] and recruitment via reducing RANK expression [71] as well as inducing osteoclasts apoptosis [72].

It has been authorized that N-Bps including ZOL can interfere with osteoclasts differentiation and survival indirectly through diminishing the instructive influence of osteoblast on osteoclastic cells differentiation [73,74]. N-Bps can down regulate expression of RANKL and upregulate expression of OPG by osteoblast [75,76]. RANKL and OPG are key regulators of osteoclast differentiation [77] and are essential for the modulation of the bone resorption process [78]. RANKL and OPG are cytokines within the TNF family, produced mainly by osteoblast cells for the regulation of osteoclastogenesis and bone resorption. Upon binding of RANK-L to its receptor RANK expressed on surface of osteoclast precursor cells, it stimulates osteoclastogenesis, osteoclast survival and bone resorption. OPG on the other hand is a receptor antagonist that prevents RANK to RANK-L interaction to inhibit osteoclast differentiation, function, promote their apoptosis and prevents bone resorption [79]. This can account for the significant reduced ES/BS associated with the significant increase in Ob/BS in ZOL group II (12 weeks) as compared with ZOL group I (6 weeks) observed in the current study.

The influence of N-Bps on bone homeostasis and bone remodelling doesn't only rely on osteoclast inhibition, but it can also affect osteoblast homeostasis [73,80]. The effect of ZOL on osteoblasts seems to be dose and time dependant. Therapeutic doses for osteoporosis management (10⁻⁷ M or less) were associated with increased osteoblasts proliferation [81], while higher doses were associated with suppression of osteoblasts proliferation, increased apoptosis and cytotoxicity [55,81–83], decreased cell viability and migration [83] in vitro. In addition to inhibition of osteoblasts proliferation, differentiation and function [84]. These findings can explain the initial reduced Ob/BS in the current study after administration ZOL for six weeks.

The active endochondral ossification, woven bone formation and active osteoblastic lining of the bone marrow cavities reported in the histological sections of the condyles of the rats administrated ZOL for 12 weeks in the present study are supported and explained by the results of the study carried out by Hao et al. 2015. They reported woven bone formation in 0.1 mg.kg⁻¹ ZOL-treated Sprague-Dawley rats at early stage of

osteoporotic fracture healing while the cartilage and fibrocartilage persisted in the majority of the control animals. ZOL enhanced callus growth and mineralization, instead of blocking endochondral bone formation and the subsequent transformation of fibrocartilage callus into woven bone [85]. ZOL could enhance the proliferation and osteogenic differentiation of MSCs [81,86], and increase osteoblast proliferation, differentiation, and mineralization [87] or even would not inhibit mineralization [88,89]. Moreover, it has been deduced that ZOL could protect cartilage and subchondral bone by lessening the degree of overlying cartilage degeneration and reducing bone resorption in osteoarthritis models [90,91] which coincide with findings observed in ZOL group II (12 weeks) in the current study.

In conclusion, our study suggests that oncologic doses of ZOL on long term could enhance endochondral and intramembranous ossification of TMJ condyles. This study also provides evidence that the deleterious effect of bisphosphonates in inducing jaw necrosis could be reversed into a beneficial role by enhancing new woven bone formation through endochondral ossification which should help in clinical treatment of subchondral fractures. Further studies with successive sacrificing dates starting from the first week of ZOL administration need to be held to clarify the exact correlation between inflammatory mediators' level with bone early and late osteogenic markers as well as RANK expression.

CONFLICT OF INTERESTS

The authors declare that they have no conflicts of interest.

REFERENCES

1. Marieb E.N., Hoehn K., 2007. The Endocrine System. In Human Anatomy & Physiology Eighth Edition; Beauparlant, S., Ed.; Benjamin Cummings. 616–618.
2. Regezi J., Sciubba J., Jordan R., 2016. Oral Pathology: Clinical Pathologic Correlations, 7th edition.; Dolan, J., Ed.; Elsevier. pp.346-369
3. Miller P.D., Watts N.B., 2013. Bisphosphonates. In Osteoporosis: diagnosis and management; Stovall, D.W., Ed.; John Wiley & Sons, Ltd. pp 123–143.

- <https://doi.org/10.1002/9781118316290.ch9>.
4. Giger E.V., Castagner B., Leroux J.C., 2013. Biomedical applications of bisphosphonates. J Control Release. 167(2), 175–188. <https://doi.org/10.1016/j.jconrel.2013.01.032>.
5. Srivastava M., Deal C., 2002. Osteoporosis in Elderly: Prevention and Treatment. Clin Geriatr Med. 18, 529–555.
6. Ivanova S., Vasileva L., Ivanova S., Peikova L., Obreshkova D., 2015. Osteoporosis: therapeutic options. Folia Med. (Plovdiv). 57 (3–4), 181–190. <https://doi.org/10.1515/folmed-2015-0037>.
7. Watts N.B., Diab D.L., 2010. Long-term use of bisphosphonates in osteoporosis. J Clin Endocrinol Metab. 95(4), 1555–1565. <https://doi.org/10.1210/jc.2009-1947>.
8. Ebetino F.H., Hogan A.M.L., Sun S., Tsoumpra M.K., Duan X., Triffitt J.T., Kwaasi A.A., Dunford J.E., Barnett B.L., Oppermann U., Lundy M.W., Boyde A., Kashemirov B.A., McKenna C.E., Russell R.G., 2011. The relationship between the chemistry and biological activity of the bisphosphonates. Bone. 49(1), 20–33. <https://doi.org/10.1016/j.bone.2011.03.774>.
9. Cremers S., Papapoulos S., 2011. Pharmacology of bisphosphonates. Bone. 49(1), 42–49. <https://doi.org/10.1016/j.bone.2011.01.014>.
10. Russell R.G., Watts N.B., Ebetino F.H., Rogers M.J., 2008. Mechanisms of action of bisphosphonates: similarities and differences and their potential influence on clinical efficacy. Osteoporos Int. 19(6), 733–759. <https://doi.org/10.1007/s00198-007-0540-8>.
11. Drake M.T., Cremers S.C.L.M., 2010. Bisphosphonate therapeutics in bone disease: the hard and soft data on osteoclast inhibition. Mol Interv. 10(3), 141–152. <https://doi.org/10.1124/mi.10.3.5>.
12. Powles T., Paterson A., McCloskey E., Schein P., Scheffler B., Tidy A., Ashley S., Smith I., Ottestad L., Kanis J., 2006. Reduction in bone relapse and improved survival with oral clodronate for adjuvant treatment of operable breast cancer [ISRCTN83688026]. Breast Cancer Res. 8(2), R13. <https://doi.org/10.1186/bcr1384>.
13. Graham R., Russell G., 2011. Bisphosphonates: The first 40 years. Bone. 49, 2–19. <https://doi.org/10.1016/j.bone.2011.04.022>.
14. Nancollas G.H., Tang R., Phipps R.J., Henneman Z.,

- Gulde S., Wu W., 2006. Novel insights into actions of bisphosphonates on bone: differences in interactions with hydroxyapatite. *Bone*. 38, 617–627. <https://doi.org/10.1016/j.bone.2005.05.003>.
15. Rogers M.J., Crockett J.C., Coxon F.P., Monkkenon J., 2011. Biochemical and molecular mechanisms of action of bisphosphonates. *Bone*. 49(1), 34–41. <https://doi.org/10.1016/j.bone.2010.11.008>.
16. Khan S.A., Kanis J.A., Vasikaran S., Kline W.F., Matuszewski B.K., McCloskey E.V., Beneton M.N., Gertz B.J., Sciberras D.G., Holland S.D., Orgee J., Coombes G.M., Rogers S.R., Porras A.G., 1997. Elimination and biochemical responses to intravenous alendronate in postmenopausal osteoporosis. *J Bone Miner Res.* 12(10), 1700–1707. <https://doi.org/10.1359/jbmr.1997.12.10.1700>.
17. Dunford J.E., Thompson K., Coxon F.P., Luckman S.P., Hahn F.M., Poulter C.D., Ebetino F.H., Rogers M.J., 2001. Structure-activity relationships for inhibition of farnesyl diphosphate synthase in vitro and inhibition of bone resorption in vivo by nitrogen-containing bisphosphonates. *J Pharmacol Exp Ther.* 296(2), 235–242.
18. Gasser J.A., Ingold P., Venturiere A., Shen V., Green J.R., 2008. Long-term protective effects of zoledronic acid on cancellous and cortical bone in the ovariectomized rat. *J Bone Miner Res.* 23, 544–551. <https://doi.org/10.1359/JBMR.071207>.
19. Ralston S., 2015. Bisphosphonates for Osteoporosis. In *Medicines for Women*; Harrison-Woolrych, M., Ed.; Springer International Publishing: Cham. 345–371. <https://doi.org/10.1007/978-3-319-12406-3>.
20. Grey A., Bolland M., Wattie D., Horne A., Gamble G., Reid I.R., 2010. Prolonged antiresorptive activity of zoledronate: a randomized, controlled trial. *J Bone Miner Res.* 25(10), 2251–2255. <https://doi.org/10.1002/jbmr.103>.
21. Black D.M., Delmas P.D., Eastell R., Reid I.R., Boonen S., Cauley J.A., Cosman F., Lakatos P., Leung P.C., Man Z., Mautalen C., Mesenbrink P., Hu H., Caminis J., Tong K., Rosario-Jansen T., Krasnow J., Hue T.F., Sellmeyer D., Eriksen E.F., Cummings S.R., 2007. Once-yearly zoledronic acid for treatment of postmenopausal osteoporosis. *N Engl J Med.* 356(18), 1809–1822. <https://doi.org/10.1056/NEJMoa1404595>.
22. Recker R.R., Delmas P.D., Halse J., Reid I.R., Boonen S., García-Hernandez P. a, Supronik J., Lewiecki E.M., Ochoa L., Miller P., Hu H., Mesenbrink P., Hartl F., Gasser J.A., Eriksen E.F., 2008. Effects of intravenous zoledronic acid once yearly on bone remodeling and bone structure. *J Bone Miner Res.* 23(1), 6–16. <https://doi.org/10.1359/jbmr.070906>.
23. Delmas P.D., Munoz F., Black D.M., Cosman F., Boonen S., Watts N.B., Kendler D., Eriksen E.F., Mesenbrink P.G., Eastell R., 2009. Effects of yearly zoledronic acid 5 mg on bone turnover markers and relation of pinp with fracture reduction in postmenopausal women with osteoporosis. *J Bone Miner Res.* 24(9), 1544–1551. <https://doi.org/10.1359/JBMR.090310>.
24. Black D.M., Reid I.R., Boonen S., Bucci-rechtweg C., Cauley J.A., Cosman F., Cummings S.R., Hue T.F., Lippuner K., Lakatos P., Leung P. C., Man Z., Lou R., Martinez M., Tan M., Ruzycky M.E., Su G., Eastell R., 2012. The effect of 3 versus 6 years of zoledronic acid treatment of osteoporosis: a randomized extension to the HORIZON-Pivotal Fracture Trial (PFT). *J Bone Miner Res.* 27(2), 243–254. <https://doi.org/10.1002/jbmr.1542>.
25. Black D.M., Reid I.R., Cauley J.A., Cosman F., Leung P.C., Lakatos P., Lippuner K., Cummings S.R., Hue T.F., Mukhopadhyay A., Tan M., Aftiring R.P., Eastell R., 2015. The effect of 6 versus 9 years of zoledronic acid treatment in osteoporosis: a randomized second extension to the HORIZON-Pivotal Fracture Trial (PFT). *Am Soc Bone Miner Res.* 30 (5), 934–944. <https://doi.org/10.1002/jbmr.2442>.
26. Grey A., Bolland M.J., Wattie D., Horne A., Gamble G., Reid I.R., 2009. The antiresorptive effects of a single dose of zoledronate persist for two years: a randomized, placebo-controlled trial in osteopenic postmenopausal women. *J Clin Endocrinol Meta.* 94(2), 538–544. <https://doi.org/10.1210/jc.2008-2241>.
27. Greenspan S.L., Perera S., Ferchak M.A., Nace D.A., Resnick N.M., 2015. Efficacy and safety of single-dose zoledronic acid for osteoporosis in frail elderly women a randomized clinical trial. *J Am Med Assoc.* 175(6), 913–921. <https://doi.org/10.1001/jamainternmed.2015.0747>.
28. Cosman F., Cauley J.A., Eastell R., Boonen S., Palermo L., Reid I.R., Cummings S.R., Black D.M., Hayes H.C., 2014. Reassessment of fracture risk in

- women after 3 years of treatment with zoledronic acid: when is it reasonable to discontinue treatment? *J Clin Endocrinol Metab.* 99 (December), 4546–4554. <https://doi.org/10.1210/jc.2014-1971>.
29. Boonen S., Kaufman J.-M., Lippuner K., Zanchetta J., Langdahl B., Rizzoli R., Lipschitz S., Dimai H.P., Witvrouw R., Eriksen E., Brixen K., Russo L., Claessens F., Papanastasiou P., Antunez O., Su G., Bucci-Rechtweg C., Hruska J., Incera E., Vanderschueren D., Orwoll E., 2012. Fracture risk and zoledronic acid therapy in men with osteoporosis. *N Engl J Med.* 367(18), 1714–1732. <https://doi.org/10.1056/NEJMoa1204061>.
30. Lekamwasam S., Adachi J. D., Agnusdei D., Bilezikian J., Boonen S., Borgström F., Cooper C., Diez Perez A., Eastell R., Hofbauer L.C., Kanis J.A., Langdahl B.L., Lesnyak O., Lorenc R., McCloskey E., Messina O.D., Napoli N., Obermayer-Pietsch B., Ralston S.H., Sambrook P.N., Silverman S., Sosa M., Stepan J., Suppan G., Wahl D.A., Compston J.E., 2012. A framework for the development of guidelines for the management of glucocorticoid-induced osteoporosis. *Osteoporos. Int.* 23(9), 2257–2276. <https://doi.org/10.1007/s00198-012-1958-1>.
31. Zhao X., Hu X., 2015. Dosing of zoledronic acid with its anti-tumor effects in breast cancer. *J Bone Oncol.* 4(3), 98–101. <https://doi.org/10.1016/j.jbo.2015.08.001>.
32. Santini D., Vincenzi B., Galluzzo S., Battistoni F., Rocci L., Venditti O., Schiavon G., Angeletti S., Uzzalli F., Caraglia M., 2007. Repeated intermittent low-dose therapy with zoledronic acid induces an early, sustained, and long-lasting decrease of peripheral vascular endothelial growth factor levels in cancer patients. *Clin Cancer Res.* 13(15), 4482–4486.
33. Wellington K., Goa K.L., Coleman R.E., Dearnaley D.R., Fleisch H., Hotte S.J., 2003. Zoledronic acid a review of its use in the management of bone metastases and hypercalcaemia of malignancy. *Drugs.* 63(4), 417–437.
34. Wood J., Bonjean K., Ruetz S., Ene A.B., Devy L., Foidart J.M., Castronovo V., Green J.R., Biology T., 2002. Novel antiangiogenic effects of the bisphosphonate compound zoledronic acid. *J Pharmacol Exp Ther.* 302(3), 1055–1061. <https://doi.org/10.1124/jpet.102.035295>.
35. Wang G., Chen J., Ma R., Xu W., Yan C., Niu C., 2018. Effects of zoledronic acid and ibandronate in the treatment of cancer pain in rats with lung cancer combined with bone metastases. *Oncol Lett.* 16(2), 1696–1700. <https://doi.org/10.3892/ol.2018.8804>.
36. Walker K., Medhurst S.J., Kidd B.L., Glatt M., Bowes M., Patel S., McNair K., Kesingland A., Green J., Chan O., Fox A.J., Urban L.A., 2002. Disease modifying and anti-nociceptive effects of the bisphosphonate, zoledronic acid in a model of bone cancer pain. *Pain.* 100(3), 219–229. [https://doi.org/10.1016/S0304-3959\(02\)00040-4](https://doi.org/10.1016/S0304-3959(02)00040-4).
37. Reid I.R., Gamble G.D., Mesenbrink P., Lakatos P., Black D.M., 2010. Characterization of and risk factors for the acute-phase response after zoledronic acid. *J Clin Endocrinol Metab.* 95(9), 4380–4387. <https://doi.org/10.1210/jc.2010-0597>.
38. Rathbone E.J., Brown J.E., Marshall H.C., Collinson M., Liversedge V., Murden G.A., Cameron D., Bell R., Spensley S., Agrawal R., Jyothirmayi R., Chakraborti P., Yuille F., Coleman R.E., 2013. Osteonecrosis of the jaw and oral health-related quality of life after adjuvant zoledronic acid: an adjuvant zoledronic acid to reduce recurrence trial subprotocol (BIG01/04). *J Clin Oncol.* 31(21), 2685–2691. <https://doi.org/10.1200/JCO.2012.46.4792>.
39. Khosla S., Burr D., Cauley J., Dempster D.W., Ebeling P.R., Felsenberg D., Gagel R.F., Gilsanz V., Guise T., Koka S., McCauley L.K., McGowan J., McKee M.D., Mohla S., Pendrys D.G., Raisz L.G., Ruggiero S.L., Shafer D.M., Shum L., Silverman S.L., Van Poznak C.H., Watts N., Woo S.B., Shane E., 2007. Bisphosphonate-associated osteonecrosis of the jaw: report of a task force of the American Society for Bone and Mineral Research. *J Bone Miner Res.* 22, 1479–1491. <https://doi.org/10.1359/jbmr.0707onj>.
40. Reid I.R., 2009. Osteonecrosis of the jaw: who gets it, and why? *Bone.* 44(1), 4–10. <https://doi.org/10.1016/j.bone.2008.09.012>.
41. Pacheco V.N., Langie R., Etges A., Ponzoni D., Puricelli E., 2015. Nitrogen containing bisphosphonate therapy: assessment of the alveolar bone structure in rats—a blind randomized controlled trial. *Int J Exp Pathol.* 96(4), 255–260.

42. Allen M.R., Kubek D.J., Burr D.B., 2010. Cancer treatment dosing regimens of zoledronic acid result in near-complete suppression of mandible intracortical bone remodeling in beagle dogs. *J Bone Miner Res.* 25(1), 98–105. <https://doi.org/10.1359/jbmr.090713>.
43. Dempster D.W., Compston J.E., Drezner M.K., Glorieux F.H., Kanis J.A., Malluche H., Meunier P.J., Ott S.M., Recker R.R., Parfitt A.M., 2013. Standardized nomenclature, symbols, and units for bone histomorphometry: a 2012 update of the report of the ASBMR Histomorphometry Nomenclature Committee. *J Bone Miner Res.* 28(1), 2–17. <https://doi.org/10.1002/jbmr.1805>.
44. Schindelin J., Arganda-Carreras I., Frise E., Kaynig V., Longair M., Pietzsch T., Preibisch S., Rueden C., Saalfeld S., Schmid B., Tinevez J.Y., White D.J., Hartenstein V., Eliceiri K., Tomancak P., Cardona A., 2012. Fiji: an open-source platform for biological-image analysis. *Nat Methods.* 9(7), 676–682. <https://doi.org/10.1038/nmeth.2019>.
45. Arganda-Carreras I., Kaynig V., Rueden C., Eliceiri K.W., Schindelin J., Cardona A., Sebastian Seung H., 2017. Trainable weka segmentation: a machine learning tool for microscopy pixel classification. *Bioinformatics.* 33(15), 2424–2426. <https://doi.org/10.1093/bioinformatics/btx180>.
46. Doube M., Kłowski M.M., Arganda-Carreras I., Cordelières F.P., Dougherty R.P., Jackson J.S., Schmid B., Hutchinson J.R., Shefelbine S.J., 2010. BoneJ: free and extensible bone image analysis in ImageJ. *Bone.* 47(6), 1076–1079. <https://doi.org/https://doi.org/10.1016/j.bone.2010.08.023>.
47. Malhan D., Muelke M., Rosch S., Schaefer A.B., Merboth F., Weisweiler D., Heiss C., Arganda-Carreras I., El Khassawna T., 2018. An optimized approach to perform bone histomorphometry. *Front Endocrinol (Lausanne).* 9, 666. <https://doi.org/10.3389/fendo.2018.00666>.
48. Kulak C.A.M., Dempster D.W., 2010. Bone histomorphometry: a concise review for endocrinologists and clinicians. *Arq Bras Endocrinol Metabol.* 54(2), 87–98. <https://doi.org/10.1590/s0004-27302010000200002>.
49. Parfitt A.M., Mathews C.H., Villanueva A.R., Kleerekoper M., Frame B., Rao D.S., 1983. Relationships between surface, volume, and thickness of iliac trabecular bone in aging and in osteoporosis. Implications for the microanatomic and cellular mechanisms of bone loss. *J Clin Invest.* 72(4), 1396–1409. <https://doi.org/10.1172/JCI111096>.
50. Kohno N., Aogi K., Minami H., Nakamura S., Asaga T., Iino Y., Watanabe T., Goessl C., Ohashi Y., Takashima S., 2005. Zoledronic acid significantly reduces skeletal complications compared with placebo in Japanese women with bone metastases from breast cancer: a randomized, placebo-controlled trial. *J Clin Oncol.* 23(15), 3314–3321. <https://doi.org/10.1200/JCO.2005.05.116>.
51. de Barros Silva P.G., Junior A.E.C.F., Teófilo C.R., Barbosa M.C., Lima R.C.P., Sousa F.B., Mota M.R.L., de Albuquerque Ribeiro R., Alves A.P.N.N., 2015. Effect of different doses of zoledronic acid in establishing of bisphosphonate-related osteonecrosis. *Arch Oral Biol.* 60(9), 1237–1245.
52. Jabbour Z., El-Hakim M., Henderson J.E., Rubens F., 2014. Bisphosphonates inhibit bone remodeling in the jaw bones of rats and delay healing following tooth extractions. *Oral Oncol.* 50(5), 485–490.
53. Giannasi C., Niada S., Farronato D., Lombardi G., Manfredi B., Farronato G., Brini A.T., 2019. Nitrogen containing bisphosphonates impair the release of bone homeostasis mediators and matrix production by human primary pre-osteoblasts. *Int J Med Sci.* 16(1), 23-32.
54. Singh A., Gill G., Kaur H., Amhmed M., Jakhu H., 2018. Role of osteopontin in bone remodeling and orthodontic tooth movement: a review. *Prog Orthod.* 19(1), 18. <https://doi.org/10.1186/s40510-018-0216-2>.
55. Pozzi S., Vallet S., Mukherjee S., Cirstea D., Vaghela N., Santo L., Rosen E., Ikeda H., Okawa Y., Kiziltepe T., Schoonmaker J., Xie W., Hideshima T., Weller E., Boussein M.L., Munshi N.C., Anderson K.C., Raje N., 2009. High-dose zoledronic acid impacts bone remodeling with effects on osteoblastic lineage and bone mechanical properties. *Clin Cancer Res.* 15(18), 5829–5839. <https://doi.org/10.1158/1078-0432.CCR-09-0426>.
56. Nyangoga H., Blouin S., Libouban H., Baslé M.F., Chappard D., 2010. A single pretreatment by zoledronic acid converts metastases from osteolytic to osteoblastic in the rat. *Microsc Res Tech.* 73(8), 733–740. <https://doi.org/10.1002/jemt.20814>.
57. Labrinidis A., Hay S., Liapis V., Findlay D.M.,

- Evdokiou A., 2010. Zoledronic acid protects against osteosarcoma-induced bone destruction but lacks efficacy against pulmonary metastases in a syngeneic rat model. *Int J Cancer*. 127 (2), 345–354. <https://doi.org/10.1002/ijc.25051>.
58. Haider M.T., Holen I., Dear T.N., Hunter K., Brown H.K., 2014. Modifying the osteoblastic niche with zoledronic acid in vivo-potential implications for breast cancer bone metastasis. *Bone*. 66(100), 240–250. <https://doi.org/10.1016/j.bone.2014.06.023>.
59. Camacho-Alonso F., López-Jornet P., Vicente-Hernández A., 2013. Short-term effect of zoledronic acid upon fracture resistance of the mandibular condyle and femoral head in an animal model. *Med Oral Patol Oral Cir Bucal*. 18(3), e421-6. <https://doi.org/10.4317/medoral.18449>.
60. Allen M.R., Kubek D.J., Burr D.B., 2010. Cancer treatment dosing regimens of zoledronic acid result in near-complete suppression of mandible intracortical bone remodeling in beagle dogs. *J Bone Miner Res*. 25(1), 98–105. <https://doi.org/10.1359/jbmr.090713>.
61. Binkley N., Kimmel D., Bruner J., Haffa A., Davidowitz B., Meng C., Schaffer V., Green J., 1998. Zoledronate prevents the development of absolute osteopenia following ovariectomy in adult Rhesus monkeys. *J Bone Miner Res*. 13(11), 1775–1782. <https://doi.org/10.1359/jbmr.1998.13.11.1775>.
62. Gonen Z.B., Colpak H.A., Onger M.E., 2019. Effects of bisphosphonate treatment on mandibular condyle tissues of temporomandibular joint: a stereological study. *J Stomatol Oral Maxillofac Surg*. 120(6), 513–516.
63. Kalder M., Kyvernitakis I., Albert U.S., Baier-Ebert M., Hadji P., 2015. Effects of zoledronic acid versus placebo on bone mineral density and bone texture analysis assessed by the trabecular bone score in premenopausal women with breast cancer treatment-induced bone loss: results of the ProBONE II substudy. *Osteoporos. Int. J. Establ. as result Coop. between Eur Found Osteoporos Natl Osteoporos. Found. USA* 26(1), 353–360. <https://doi.org/10.1007/s00198-014-2955-3>.
64. Gnant M.F.X., Mlineritsch B., Luschin-Ebengreuth G., Grampp S., Kaessmann H., Schmid M., Menzel C., Piswanger-Soelkner J.C., Galid A., Mittlboeck M., Hausmaninger H., Jakesz R., 2007. Zoledronic acid prevents cancer treatment-induced bone loss in premenopausal women receiving adjuvant endocrine therapy for hormone-responsive breast cancer: a report from the Austrian breast and colorectal cancer study group. *J Clin Oncol*. 25(7), 820–828. <https://doi.org/10.1200/JCO.2005.02.7102>.
65. Brufsky A., Harker W.G., Beck J.T., Carroll R., Tan-Chiu E., Seidler C., Hohneker J., Lacerna L., Petrone S., Perez E.A., 2007. Zoledronic acid inhibits adjuvant letrozole-induced bone loss in postmenopausal women with early breast cancer. *J Clin Oncol*. 25(7), 829–836. <https://doi.org/10.1200/JCO.2005.05.3744>.
66. Saad F., 2005. Clinical benefit of zoledronic acid for the prevention of skeletal complications in advanced prostate cancer. *Clin Prostate Cancer*. 4(1), 31–37. <https://doi.org/10.3816/cgc.2005.n.009>.
67. Saad F., Gleason D.M., Murray R., Tchekmedyian S., Venner P., Lacombe L., Chin J.L., Vinholes J.J., Goas J.A., Zheng M., 2004. Long-term efficacy of zoledronic acid for the prevention of skeletal complications in patients with metastatic hormone-refractory prostate cancer. *J Natl Cancer Inst*. 96(11), 879–882. <https://doi.org/10.1093/jnci/djh141>.
68. Rosen L.S., Gordon D., Tchekmedyian S., Yanagihara R., Hirsh V., Krzakowski M., Pawlicki M., de Souza P., Zheng M., Urbanowitz G., Reitsma D., Seaman J.J., 2003. Zoledronic acid versus placebo in the treatment of skeletal metastases in patients with lung cancer and other solid tumors: a phase III, double-blind, randomized trial-the zoledronic acid lung cancer and other solid tumors study group. *J Clin Oncol*. 21(16), 3150–3157. <https://doi.org/10.1200/JCO.2003.04.105>.
69. Coxon F.P., Helfrich M.H., Larijani B., Muzylak M., Dunford J.E., Marshall D., Mckinnon A.D., Nesbitt S.A., Horton M.A., Seabra M.C., Ebetino F.H., Rogers M.J., 2001. Identification of a novel phosphonocarboxylate inhibitor of Rab geranylgeranyl transferase that specifically prevents Rab prenylation in osteoclasts and macrophages. *J Biol Chem*. 276 (51), 48213–48222. <https://doi.org/10.1074/jbc.M106473200>.
70. Rogers M.J., Frith J.C., Luckman S.P., Coxon F.P., Benford H.L., Monkkonen J., Auriola S., Chilton K.M., Russell R.G., 1999. Molecular mechanisms of action of bisphosphonates. *Bone*. 24 (5 Suppl), 73S-79S.
71. Kimachi K., Kajiya H., Nakayama S., 2011. Zoledronic acid inhibits rank expression and migration of

- osteoclast precursors during osteoclastogenesis. *Naunyn-Schmied Arch Pharmacol.* 383, 297–308. <https://doi.org/10.1007/s00210-010-0596-4>.
72. Kellinsalmi M., Mönkkönen H., Mönkkönen J., Leskelä H.-V., Parikka V., Hämäläinen M., Lehenkari P., 2005. In vitro comparison of clodronate, pamidronate and zoledronic acid effects on rat osteoclasts and human stem cell-derived osteoblasts. *Basic Clin. Pharmacol. Toxicol.* 97(6), 382–391. https://doi.org/10.1111/j.1742-7843.2005.pto_176.x.
73. Bellido T., Plotkin L.I., 2011. Novel actions of bisphosphonates in bone: preservation of osteoblast and osteocyte viability. *Bone.* 49(1), 50–55. <https://doi.org/10.1016/j.bone.2010.08.008>.
74. Nishikawa M., Akatsu T., Katayama Y., Yasutomo Y., Kado S., Kugal N., Yamamoto M., Nagata N., 1996. Bisphosphonates act on osteoblastic cells and inhibit osteoclast formation in mouse marrow cultures. *Bone.* 18(1), 9–14.
75. Viereck V., Emons G., Lauck V., Frosch K.H., Blaschke S., Grundker C., Hofbauer L.C., 2002. Bisphosphonates pamidronate and zoledronic acid stimulate osteoprotegerin production by primary human osteoblasts. *Biochem Biophys Res Commun.* 291(3), 680–686. <https://doi.org/10.1006/bbrc.2002.6510>.
76. Pan B., Farrugia A.N., To L.B., Findlay D.M., Green J., Lynch K., Zannettino A.C.W., 2004. The nitrogen-containing bisphosphonate, zoledronic acid, influences RANKL expression in human osteoblast-like cells by activating TNF-alpha converting enzyme (TACE). *J Bone Miner Res.* 19(1), 147–154. <https://doi.org/10.1359/jbmr.2004.19.1.147>.
77. Nanci A., 2013. *Ten Cate's Oral Histology: development, structure and function, eighth edi*; St Louis: Elsevier Mosby.
78. Teitelbaum S.L., 2007. Osteoclasts: what do they do and how do they do it? *Am J Pathol.* 170, 427–435.
79. Tyrovolas J.B., Spyropoulos M.N., Makou M., Perrea D., 2008. Root resorption and the OPG / RANKL / RANK system : A Mini Review. *J Oral Sci.* 50, 367–376.
80. Plotkin L.I., Lezcano V., Thostenson J., Weinstein R.S., Manolagas S.C., Bellido T., 2008. Connexin 43 is required for the anti-apoptotic effect of bisphosphonates on osteocytes and osteoblasts in vivo. *J Bone Miner Res.* 23(11), 1712–1721. <https://doi.org/10.1359/jbmr.080617>.
81. Corrado A., Neve A., Maruotti N., Gaudio A., Marucci A., Cantatore F.P., 2010. Dose-dependent metabolic effect of zoledronate on primary human osteoblastic cell cultures. *Clin Exp Rheumatol.* 28(6), 873–879.
82. Huang X., Huang S., Guo F., Xu F., Cheng P., Ye Y., Dong Y., Xiang W., Chen A., 2016. Dose-dependent inhibitory effects of zoledronic acid on osteoblast viability and function in vitro. *Mol Med Rep.* 13(1), 613–622. <https://doi.org/10.3892/mmr.2015.4627>.
83. Zafar S., Coates D.E., Cullinan M.P., Drummond B.K., Milne T., Seymour G.J., 2016. Effects of zoledronic acid and geranylgeraniol on the cellular behaviour and gene expression of primary human alveolar osteoblasts. *Clin Oral Investig.* 20(8), 2023–2035. <https://doi.org/10.1007/s00784-015-1706-y>.
84. Patntirapong S., Singhatanadgit W., Chanruangvanit C., Lavanrattanukul K., Satravaha Y., 2012. Zoledronic acid suppresses mineralization through direct cytotoxicity and osteoblast differentiation inhibition. *J Oral Pathol Med.* 41(9), 713–720. <https://doi.org/10.1111/j.1600-0714.2012.01154.x>.
85. Hao Y., Wang X., Wang L., Lu Y., Mao Z., Ge S., Dai K., 2015. Zoledronic Acid Suppresses Callus Remodeling but Enhances Callus Strength in an Osteoporotic Rat Model of Fracture Healing. *Bone.* 81, 702–711.
86. Zhou Q., Zhao Z.N., Cheng J.T., Zhang B., Xu J., Huang F., Zhao R.N., Chen Y.J., 2011. Ibandronate promotes osteogenic differentiation of periodontal ligament stem cells by regulating the expression of micRNAs. *Biochem Biophys Res Commun.* 404(1), 127–132.
87. Greiner S., Kadow-Romacker A., Lübberstedt M., Schmidmaier G., Wildemann B., 2007. The effect of zoledronic acid incorporated in a poly (d, l-lactide) implant coating on osteoblasts in vitro. *J Biomed Mater Res. Part A,* 80(4), 769–775.
88. Idris A.I., Rojas J., Greig I.R., van't Hof R.J., Ralston S.H., 2008. Aminobisphosphonates cause osteoblast apoptosis and inhibit bone nodule formation in vitro. *Calcif Tissue Int.* 82(3), 191–201.
89. Reinholz G.G., Getz B., Pederson L., Sanders E.S., Subramaniam M., Ingle J.N., Spelsberg T.C., 2000.

Bisphosphonates directly regulate cell proliferation, differentiation, and gene expression in human osteoblasts. *Cancer Res.* 60(21), 6001–6007.

90. Strassle B.W., Mark L., Leventhal L., Piesla M.J., Li X.J., Kennedy J.D., Glasson S.S., Whiteside G.T., 2010. Inhibition of osteoclasts prevents cartilage loss and pain in a rat model of degenerative joint disease. *Osteoarthritis Cartil.* 18(10), 1319–1328.

91. Herrak P., Görtz B., Hayer S., Redlich K., Reiter E., Gasser J., Bergmeister H., Kollias G., Smolen J. S., Schett G., 2004. Zoledronic acid protects against local and systemic bone loss in tumor necrosis factor-mediated arthritis. *Arthritis Rheum Off J Am Coll Rheumatol.* 50(7), 2327–2337.

