



Acute and sub-chronic toxicity study of methanol stem bark extract of *Bombaxcostatum* Pellgr. Et VUILLET (Bombacaceae) in mice

Nuhu Mohammed^{1*}, Joseph Akpojo Anuka¹, Aliyu Muhammad Musa², Jamilu Yau¹

¹Department of Pharmacology and Therapeutics, Ahmadu Bello University Zaria, Nigeria;

*Email: nuhumhd8@gmail.com

²Department of Pharmaceutical and Medicinal Chemistry, Ahmadu Bello University Zaria, Nigeria;

ARTICLE INFO

Type: Original Research

Topic: Medicinal Plants

Received May 08th 2020

Accepted August 11th 2020

Key words:

- ✓ *Bombax costatum*
- ✓ Toxicity
- ✓ Necrosis
- ✓ Safety
- ✓ Transaminase

ABSTRACT

Background & Aim: *Bombax costatum* is widely used in the African traditional medicine for the management of liver diseases, fever, epilepsy and pain but its safety on prolonged administration has not been evaluated. The present study aimed at evaluating the toxicological properties of the methanol stem bark extract (MSBE) of *Bombax costatum*.

Experimental: Oral median lethal dose (LD₅₀) was estimated. Effects of methanol stem bark extract of *Bombax costatum* (MSBE) (31.25, 62.5 and 125 mg/kg) on mean body weight, relative organ weight (ROW), liver function, kidney function, lipid profile, haematological parameters and histopathological changes in some organs were evaluated following 28 days daily oral administration to mice.

Results: Oral LD₅₀ of MSBE of *B. costatum* was estimated to be >5000 mg/kg. There was significant ($p > 0.005$) increase in mean body weight of mice over time. The extract caused significant ($p < 0.05$) increase in ROW of liver and significant ($p < 0.05$) decrease in ROW of the kidneys at 125 mg/kg. Significant increase in alanine transaminase and aspartate transaminase were also observed at 125 mg/kg when compared to normal control group. Mild to moderate necrosis was also observed in the liver and kidneys of treated groups.

Recommended applications/industries: The results suggested that prolonged oral administration of methanol stem bark extract of *B. costatum* at doses higher than 62.5 mg/kg might be toxic to the liver and kidneys.

1. Introduction

Medicinal plants have been widely used by urban and rural populations in treating various diseases because they are readily available, accessible and affordable (Jordan et al., 2010). The World Health Organization (WHO) has recognized the fact that about 80% of the population in developing countries rely on traditional medicine for their healthcare needs (WHO, 2013). This could be due to affordability, accessibility and cultural

acceptability of traditional medicine in many parts of the world. Most people living in developing countries use traditional medicine either as a result of high cost of pharmaceuticals or because traditional medicines are more acceptable from a cultural and spiritual perspective (Cunningham, 1988). Traditionally, medicinal plants have been considered to be non-toxic and have been used by the general public and traditional medical practitioners to treat many diseases. In Nigeria and other parts of Africa, herbal drugs can

be obtained from street vendors, herbal stores, friends, relatives, markets and traditional medical practitioners. Even the ordinary people sometimes recommend traditional medicine to others without safety consideration. The general public and many traditional practitioners also believe that herbs are non-toxic (Bandaranayake, 2006). The active ingredients in plant extracts are chemicals that can also be found in purified medication, and thereby having the same potential to cause toxicity.

Bombax costatum Pellgr. et Vuillet is a widely used medicinal plant in many parts of West African region. The bark of the plant is used to treat fever, skin disease, pain, abscess, oedema, hernia, and epilepsy (Assogba et al., 2017). The stem bark is used in treatment of liver diseases (Dalziel, 1985). Methanol stem bark extract of *B. Costatum* was found to contain tannins, sterols, alkaloids, saponins, cardiac glycosides, triterpenes, flavonoids and carbohydrates. It also has good *in vitro* antioxidant potential and hepatoprotective activity against paracetamol as well as Carbon tetrachloride (CCl₄) induced liver damage in rats (Mohammed et al., 2018). Despite the wide utilization, acclaimed and proven efficacy of preparations of *B. costatum*, the safety profile of this important medicinal plant on prolonged administration have not been scientifically evaluated. The aim of this study was to evaluate the toxicological profile of the methanol stem bark extract of *B. costatum* in mice.

2. Materials and Methods

2.1. Experimental animals

Swiss Albino mice (20-26 g) of either sex were obtained from the Animal House of Pharmacology and Therapeutics Department, Ahmadu Bello University Zaria. All the mice were kept in plastic cages with metal coverlids. Soft wood shavings were used as bedding material. The animals were kept under natural day and light cycle. They were given free access to commercial mice feed and water *ad libitum*. All experiments were carried out according to the ethical guidelines approved by the Ahmadu Bello University committee for animal use and care with approval number: ABUCAUC/2020/50.

2.2. Plant material

The plant was identified and collected from Sabon-Gari, Kaduna State, Nigeria in August and

authenticated by Namadi Sanusi of Herbarium Unit of the Department of Botany, Ahmadu Bello University, Zaria, Nigeria. It was compared with a voucher specimen (No. 1211) deposited in the Herbarium for future reference.

2.3. Preparation of extract

The stem bark of the plant was chopped, cleaned and air dried under shade until constant weight was obtained. It was mechanically powdered using mortar and pestle and stored in an air tight container. Methanol extract of *B. costatum* stem bark was prepared by subjecting 2.75 kg of the powdered stem bark to cold maceration using 10 L of 70% methanol (Sigma-Aldrich, U.S.A) for 72h. The mixture was intermittently stirred with glass rod during the period and then filtered using Whatman filter paper No. 1. The filtrate was concentrated to dryness over a water bath (Mediatech, Chennai India) maintained at 50°C. The extract obtained was weighed, kept in an air tight container and stored in a desiccator until it is required for further studies. Fresh solution of the extract was prepared with distilled water during each study.

2.4. Acute toxicity study

Acute toxicity study of the MSBE of *B. costatum* was carried out in mice using Organization for Economic Co-operation and Development (OECD) guideline 423 (OCED 2001). The mice were deprived of food for 3h before administration of the extract. Limit test at dose of 5000 mg/kg of the extract was conducted using 3 mice. The 3 mice were dosed at 5000 mg/kg. All the mice were observed for general behavioural changes; signs of toxicity and mortality after treatment for the first four hours, then over a period of 24h and thereafter daily for 14 days duration.

2.5. Sub-chronic toxicity study

The effect of 28 days oral administration of MSBE of *B. costatum* in mice was investigated according to OECD guidelines 407 but with some modifications. Mice of either sex were used to study the effect of 28 days daily oral administration of the extract. The mice were divided into 4 groups of 6 mice each (3 female and 3 male). Group A were treated with distilled water (10 ml/kg per day) and kept as control. Groups B, C and D were given the extract orally in doses of 31.25, 62.5 and 125 mg/kg/day, respectively. The mice were observed daily for signs and symptoms of toxicity.

Body weights were recorded weekly. Exactly after 28 days of treatment, the mice in all the groups were euthanized. Blood samples were collected by cardiac puncture for biochemical and haematological analysis using plain and ethylenediaminetetraacetic acid (EDTA) bottles respectively (OECD, 2008). Blood samples in EDTA bottles were immediately analysed using Auto haematology analyzer (IndiaMART inter MESH Ltd India). Parameters analyzed include red blood cells (RBC), white blood cells (WBC), platelets (PLT), packed cell volume (PCV), neutrophils (NEU) and lymphocytes (LYM).

Blood sample collected from each mouse in plain bottles were allowed to clot and centrifuged at 4000 revolution per minute for 10 min. The sera were separated and used for evaluation of serum alanine transaminase (ALT), aspartate transaminase (AST), alkaline phosphatase (ALP), albumin (ALB), total bilirubin (TB), urea, creatinine, total cholesterol (TC), triglyceride (TG), high density lipoprotein (HDL) and low density lipoprotein (LDL) using auto chemistry analyzer (Pokleritalia 125 PPC, Italy).

Selected internal organs such as liver, heart, spleen, kidneys and lungs were collected, weighed and fixed in a buffer solution of 10% formalin for histopathological analysis. The relative organ weight (ROW) was then calculated as ratio of absolute organ weight (g) to body weight of mouse on day of sacrifice (g) multiplied by 100.

2.6. Histopathological study

Sections of tissue from collected organs were prepared for histopathological examination. Tissues were fixed in 10% buffered formalin (pH 7.2) and dehydrated through a series of ethanol solutions (70%, 90%, 96% and absolute). The tissues were cleared in xylene and embedded in paraffin. Sections of 5 μ m thickness were cut using a rotary microtome and stained with haematoxylin and eosin for examination. The stained tissues were observed through a Leitz microscope (Optical Institute, Germany) magnification and photographed with a Scope tek DCM500 camera (Hangzhou S. Digital Technology Ltd. China).

2.7. Statistical Analysis

Data were presented using tables, charts and plates where applicable. Haematological and biochemical

data were presented as Mean \pm Standard Error of the Mean (S.E.M.). Analyses of data were done using SPSS (version 20) and Microsoft excel (version 2010). Significant differences were compared using one way ANOVA followed by Tukey's post hoc test. Body weight of mice were analysed using repeated measure ANOVA followed by Bonferroni's post hoc test. The results were considered significant at p -values ≤ 0.05 .

3. Results and discussion

Median lethal dose determination gives an important guide to the margin of safety of medicinal plants. It also serves as a guide for dose selection in pharmacological and long term toxicity studies in animals (Colerangle, 2017). In this study, the oral LD₅₀ for MSBE of *B. costatum* in mice was estimated to be >5000 mg/kg body weight as no sign of toxicity or mortality was observed for up to 2 weeks. This finding is consistent with result of previous study (Mohammed et al., 2018) where oral LD₅₀ for MSBE of *B. costatum* in rats was also estimated to be >5000 mg/kg body weight. This implies that the extract is practically non-toxic since no morbidity or mortality was recorded (Loomis and Hayes, 1996). However, acute toxicity studies are not sufficient to effectively describe the safety profile of a medicinal plant and as such long term toxicity studies are required to effectively evaluate the safety profile of herbal medicines (McNamara, 1976). In this study, OECD 407 guideline was followed to assess the safety profile of *B. costatum* in mice.

There was significant ($p < 0.01$) increase in mean body weight of mice after 28 days daily oral administration of MSBE of *B. costatum* at 62.5 and 125 mg/kg over time at day 14, 21 and 28 when compared to day 0. Significant ($p < 0.05$) increase in mean body weight was also observed in the 125 mg/kg treated group over time at day 7 when compared to day 0. However, there was no statistically significant ($p > 0.05$) difference in mean body weight between all the treated groups and control group after 28 days daily oral administration of the MSBE of *B. Costatum* (Figure 1).

This finding implies that the extract is not anorexic; hence, there was general increase in body weight of mice over time.

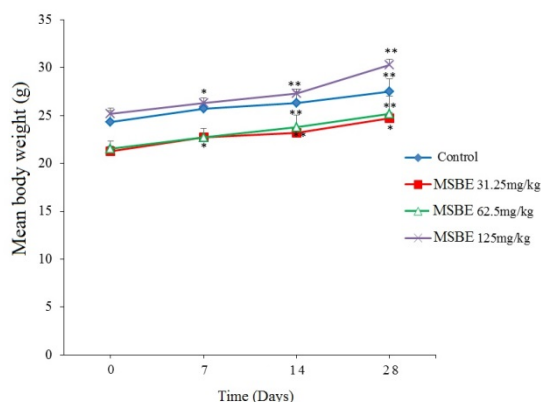


Figure 1. Effect of 28 days oral administration of methanol stem bark extract of *B. costatum* on mice mean body weight. Data were presented as Mean \pm SEM (n = 6). * p <0.05 compared to day 0, ** p <0.01 compared to day 0, MSBE= Methanol stem bark extract of *Bombax costatum*.

Reduction in body weight and relative organ weights of an animal is a simple predictive index of toxicity after exposure to potentially toxic substances (Teo et al., 2002). In this study, daily oral administration of MSBE of *B. costatum* for 28 days at 125 mg/kg caused significant (p <0.05) decrease in relative organ weight of kidneys and significant (p <0.05) increase in relative organ weight of the liver compared to control group. However, 28 days daily oral administration of MSBE of *B. costatum* at 31.25, 62.5 and 125 mg/kg did not cause significant (p >0.05) difference in the relative

organ weight of lungs, spleen and heart compared to control group (Table 1).

The observed decreased in relative organ weight of the kidneys at 125 mg/kg of the MSBE of *B. costatum* is predictive of toxicity of the extract to the kidney. Liver size can be normal, decreased or increased in presence of liver damage (Daniel, 2015). The observed increased in relative organ weight of the liver after 28 days daily oral administration of MSBE of *B. costatum* at 125 mg/kg might indicate toxicity of the extract to the liver.

The aminotransferases enzymes (ALT and AST) are sensitive indicators of liver cell injury and are most helpful in recognizing acute hepatocellular diseases. AST is found in the liver, cardiac muscle, skeletal muscle, brain, lungs, white blood cells, red blood cells and kidneys while ALT is produced exclusively in the liver. Damage to hepatocellular membrane will therefore result in leakage of transaminase enzymes resulting in elevation in their serum concentration (Daniel, 2015). There was significant (p <0.01) increase in the level of ALT and significant (p <0.05) increase in AST level after 28 days daily oral administration of 125 mg/kg of the extract when compared to control group. However, there was no significant (p >0.05) difference in serum ALP, TB and ALB levels between treated and control groups after 28 days oral administration of MSBE of *B. costatum* (Table 2).

Table 1. Effect of 28 days oral administration of MSBE of *B. costatum* on mice relative organ weight.

Organ	Distilled water 10ml/kg	MSBEBC 31.25 mg/kg	MSBEBC 62.5 mg/kg	MSBEBC 125 mg/kg
Lungs	1.00 \pm 0.68	1.13 \pm 0.08	1.03 \pm 0.06	0.98 \pm 0.03
Liver	3.60 \pm 0.17	3.93 \pm 0.32	3.42 \pm 0.28	5.08 \pm 0.35*
Spleen	0.62 \pm 0.06	0.80 \pm 0.05	0.58 \pm 0.08	0.72 \pm 0.08
Kidneys	1.08 \pm 0.008	1.15 \pm 0.12	0.95 \pm 0.05	0.65 \pm 0.06*
Heart	0.38 \pm 0.02	0.42 \pm 0.02	0.43 \pm 0.05	0.40 \pm 0.05

Data were presented as Mean \pm SEM (n = 6). One way ANOVA followed by Tukey's post hoc test. *= p \leq 0.05 compared to normal control group, MSBEBC= Methanol stem bark extract of *Bombax costatum*.

Table 2. Effect of 28 days oral administration of MSBE of *B. costatum* on liver function test parameters in mice.

Biochemical parameters	Distilled water 10ml/kg	MSBEBC 31.25mg/kg	MSBEBC 62.5mg/kg	MSBEBC 125mg/kg
ALT (U/L)	33.18 \pm 3.39	37.2 \pm 2.75	39.9 \pm 5.64	59.00 \pm 3.52**
AST (U/L)	34.42 \pm 2.82	39.18 \pm 3.84	47.03 \pm 3.55	54.22 \pm 6.70*
ALP (U/L)	52.60 \pm 5.06	53.65 \pm 2.98	56.78 \pm 2.64	58.80 \pm 4.07
TB (μ mol/L)	4.90 \pm 0.46	4.77 \pm 0.45	5.50 \pm 0.68	7.02 \pm 0.91
ALB (g/dl)	6.37 \pm 0.59	6.97 \pm 0.37	6.82 \pm 0.54	6.67 \pm 0.64

Data were presented as Mean \pm SEM (n = 6). One way ANOVA followed by Tukey's post hoc test, *= p \leq 0.05, **= p < 0.01 compared to normal control group. MSBEBC= Methanol stem bark extract of *Bombax costatum*, AST=Aspartate transaminase, ALT= Alanine transaminase, ALP= Alkaline phosphatase, TB= Total bilirubin, ALB= Albumin.

Slight hepatocellular necrosis was observed in the group that received the extract at 31.25 mg/kg while moderate hepatocellular necrosis was however observed after 28 days daily oral administration of the extract at 62.5 and 125 mg/kg (Figure 3). The observed significant increase in serum levels of ALT and AST in the extract treated group was consistent with the hepatocellular necrosis observed in the treated group.

Urea and creatinine can be used to assess renal function. Urea is the nitrogenous end-product of protein metabolism and it is completely filtered at the glomerulus, then reabsorbed and tubularly secreted within the nephrons. Creatinine on the other hand is a by-product of muscle metabolism and it is excreted by the kidney via glomerular filtration process. It is not reabsorbed, secreted or metabolized by the kidney and as such, decrease in glomerular filtration rate would result in increased serum creatinine concentration. Increased creatinine level could be from chronic renal damage (Borges et al., 2005). There was no significant ($p>0.05$) difference in level of serum urea and creatinine between all the treated and control groups (Table 3). However, glomerular necrosis and tubular necrosis were observed after 28 days oral administration of the extract at 62.5 and 125 mg/kg, respectively. There was no histopathological change observed in the kidneys of mice that received the MSBE of *B. costatum* at 31.25 mg/kg (Figure 2). The observed statistically insignificant difference in the level of urea and creatinine between the treated and control groups with corresponding glomerular and tubular necrosis after 28 days oral administration of the extract at 62.5 and 125 mg/kg could be due to early manifestation of toxicity in the kidney that has not yet affected kidney function.

There was no significant ($p>0.05$) difference in total cholesterol (TC), triglyceride (TG), high density lipoprotein (HDL) and low density lipoprotein (LDL) levels between treated and control groups after 28 days oral administration of the MSBE of *B. costatum* at 31.25, 62.5 and 125 mg/kg (Table 3). Cellular necrosis is associated with release of cellular contents that stimulate the recruitment, proliferation and activation of the immune cells resulting in phagocytosis of the cellular debris. Proliferation of lymphocytes will stimulate lymphopoiesis in the spleen that manifest histologically as lymphocyte hyperplasia. Lymphocytes are the main effectors cells of the immune system (Mc-Knight, 1999).

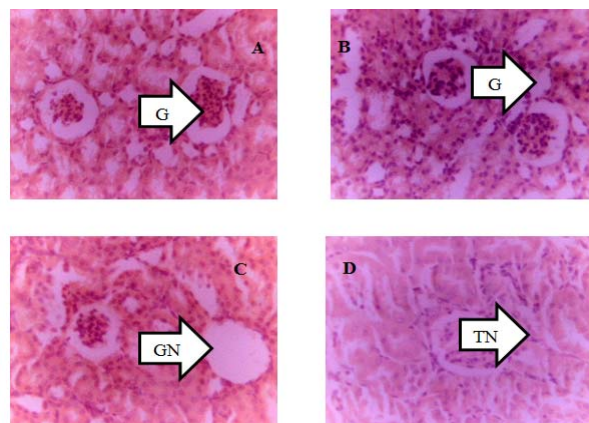


Figure 2. Photomicrograph of kidney histology showing effect of 28 days oral administration of methanol stem bark extract (MSBE) of *Bombax costatum* in mice (H and E $\times 250$). A= Distilled water, B= MSBE of *Bombax costatum* 31.25 mg/kg, C= MSBE of *Bombax costatum* 62.5 mg/kg, D= MSBE of *Bombax costatum* 125 mg/kg, T= Normal tubule, G= Normal glomerulus, GN= Glomerular necrosis, TN= Tubular necrosis

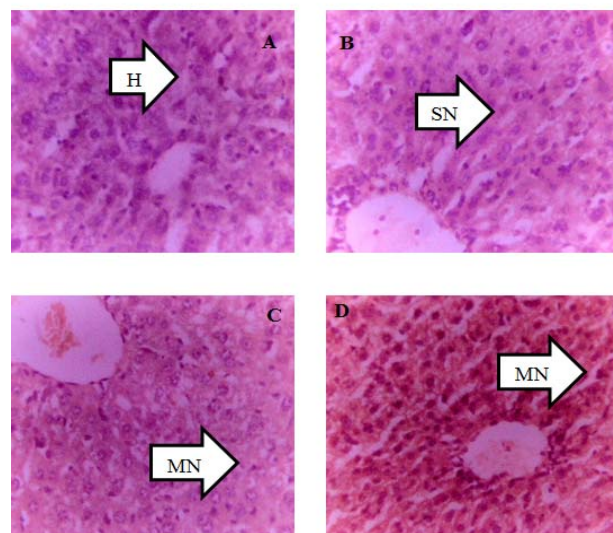


Figure 3. Photomicrograph of liver histology showing effect of 28 days oral administration of methanol stem bark extract (MSBE) of *Bombax costatum* in mice (H and E $\times 250$). A= Distilled water, B= MSBE of *Bombax costatum* 31.25 mg/kg, C= MSBE of *Bombax costatum* 62.5 mg/kg, D= MSBE of *Bombax costatum* 125 mg/kg, SN= Slight necrosis, MN= Moderate necrosis.

There was no significant difference in white blood cells (WBC), platelets (PLT), red blood cells (RBC), packed cell volume (PCV), lymphocyte (LYM) and neutrophils (NEU) levels between treated and control groups after 28 days oral administration of the MSBE of *B. costatum* at 31.25, 62.5 and 125 mg/kg (Table 4).

Table 3. Effect of 28 days oral administration of MSBE of *B. costatum* on serum urea, creatinine and lipid profile parameters in mice.

Biochemical parameter	Distilled water 10ml/kg	MSBEBC 31.25mg/kg	MSBEBC 62.5mg/kg	MSBEBC 125mg/kg
Urea (mmol/L)	4.50±0.24	4.97±0.13	4.62±0.21	5.53±0.44
Creatinine (µmol/L)	36.8±1.51	38.33±1.96	40.00±1.06	37.83±1.68
TC(mmol/L)	5.15±0.18	5.25±0.22	5.03±0.29	5.02±0.45
TG(mmol/L)	1.25±0.15	1.05±0.08	1.08±0.13	1.03±0.13
HDL(mmol/L)	2.30±0.18	2.10±0.19	2.22±0.21	2.03±0.07
LDL(mmol/L)	1.88±0.07	1.60±0.19	1.47±0.17	1.53±0.18

Data were presented as Mean ± SEM (n = 6). MSBEBC= Methanol stem bark extract of *Bombax costatum*, TC= Total cholesterol, TG= Triglyceride, HDL= High density lipoprotein, LDL= Low density lipoprotein.

Table4. Effect of 28 days oral administration of MSBE of *B. costatum* on some haematological parameters.

Hematological parameters	Distilled water 10ml/kg	MSBEBC 31.25mg/kg	MSBEBC 62.5mg/kg	MSBEBC 125mg/kg
WBC (x103/uL)	5.18±0.50	4.83±0.43	6.07±0.37	6.70±0.59
PLT (x103/uL)	485.2±29.40	579.7±57.00	583.5.8±40.50	596.8±44.50
RBC (x106/uL)	8.01±0.43	8.83±0.29	8.07±0.44	8.31±0.43
PCV (%)	37.73±1.54	40.55±2.21	38.90±1.60	38.40±1.88
LYM (%)	66.73±2.90	74.10±4.42	71.67±3.13	72.90±3.31
NEU (%)	6.05±0.31	6.00±0.30	6.08±0.31	6.25±0.31

Data were presented as Mean ± SEM (n = 6), MSBEBC= Methanol stem bark extract of *Bombax costatum*, WBC= White blood cell, PLT= Platelet, RBC= Red blood cell, PCV= Packed cell volume, LYM= Lymphocytes, NEU= Neutrophils.

Lymphocyte hyperplasia was observed in all the spleen of treated groups after 28 days daily oral administration of the extract (Figure 4).

Lymphocytic infiltration was observed in the lungs after 28 days oral administration of the extract at 62.5 mg/kg while lymphocytic infiltration and alveoli congestion were observed at 125 mg/kg (Figure5). The observed lymphocyte hyperplasia in the spleen and lymphocytic infiltration in the lungs is suggesting the ability of the extract to stimulate effector cells of the immune system on prolonged administration.

There was no histopathological change observed in the heart of both treated and control groups after 28 days oral administration of the extract to mice (Figure 6). This implies that the extract might be devoid of cardio-toxicity.

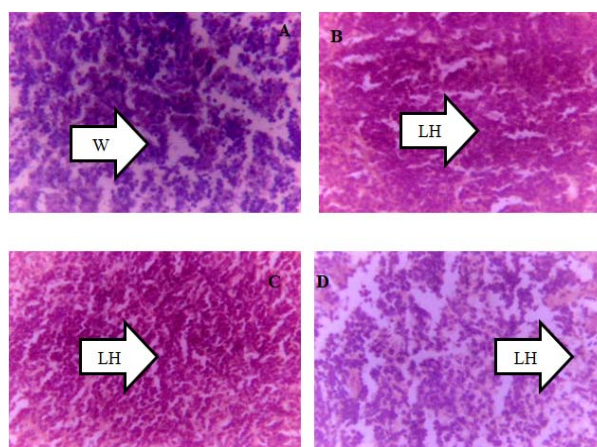


Figure 4. Photomicrograph of spleen histology showing effect of 28 days oral administration of methanol stem bark extract (MSBE) of *Bombax costatum* in mice (H and E ×250). A= Distilled water, B= MSBE of *Bombax costatum* 31.25 mg/kg, C= MSBE of *Bombax costatum* 62.5 mg/kg, D= MSBE of *Bombax costatum* 125 mg/kg, W= White pulp, LH=Lymphocyte hyperplasia.

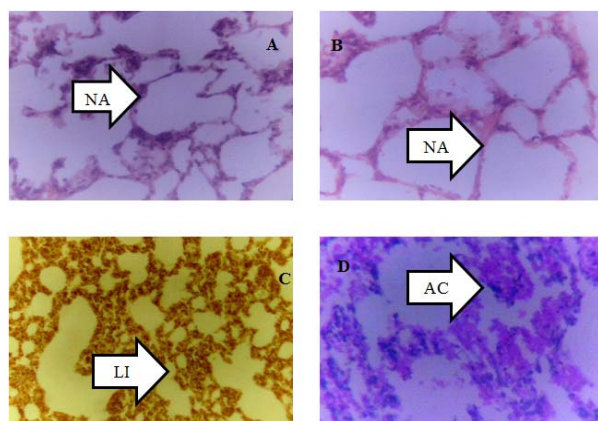


Figure 5. Photomicrograph of lungs histology showing effect of 28 days oral administration of methanol stem bark extract (MSBE) of *Bombax costatum* in mice (H and E $\times 250$). A= Distilled water, B= MSBE of *Bombax costatum* 31.25 mg/kg, C= MSBE of *Bombax costatum* 62.5 mg/kg, D= MSBE of *Bombax costatum* 125 mg/kg, NA= Normal alveolus, AC= Alveolar congestion, LI= Lymphocytic infiltration.

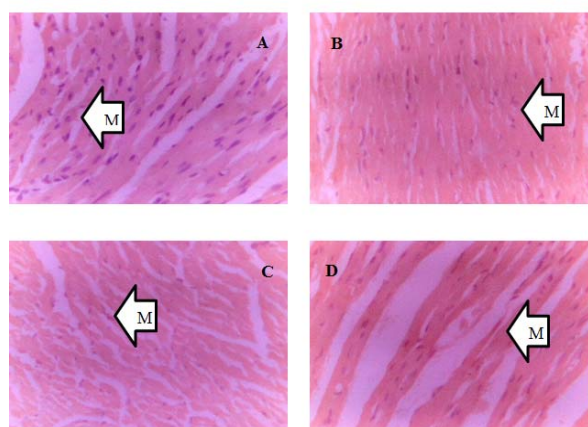


Figure 6. Photomicrograph of heart histology showing effect of 28 days oral administration of methanol stem bark extract (MSBE) of *Bombax costatum* in mice (H and E $\times 250$). A= Distilled water, B= MSBE of *Bombax costatum* 31.25 mg/kg, C= MSBE of *Bombax costatum* 62.5 mg/kg, D= MSBE of *Bombax costatum* 125 mg/kg, M= Normal myocardium

4. Conclusion

Prolong oral administration of MSBE of *B. costatum* can cause toxicity to the liver and kidney. This suggests that the extract should be used with caution when administered at high doses for a long period of time.

5. Acknowledgement

The authors are grateful for the technical assistance

of Salihu Abdullahi of the Department of Pharmacology and Therapeutics, Ahmadu Bello University Zaria, Nigeria

6. References

- Assogba, G.A., Fandohan, A.B., Salako, V.K. and Assogbadjo, A.E. 2017. Uses of *Bombax costatum* (Malvaceae) in the surrounding areas of the Pendjari biosphere reserve, Republic of Benin. *Tropical Woods and Forests*, 333(3): 17-33.
- Bandaranayake, W.M. 2006. Quality control, screening, toxicity, and regulation of herbal drugs, In: Ahmad, I., Aqil, F. and Owais, M. *Modern Phytomedicine: Turning Medicinal plants into Drugs*. Wiley-VCH Verlag GmbH & Co., Germany, pp. 25-57.
- Colerangle, J.B. 2017. Preclinical development of nononcogenic drugs (Small and large molecules). (2nd ed). In: Faqi, A.S. (Ed). *A Comprehensive Guide to Toxicology in Non-clinical Drug Development*. Academic Press, U.K. pp. 659-683.
- Cunningham, A.B. 1988. *An investigation of the herbal medicine trade in Natal/KwaZulu*. Investigational Report No. 29, Institute of Natural Resources, Natal. University of Natal. University Press.
- Dalziel, J.M. 1985. *The Useful Plants of West Tropical Africa*. Kew: Royal Botanic Gardens; Volume 1. pp 960.
- Daniel, S.P. 2015. Evaluation of Liver Function. In: Fauci, A.S., Braunwald, E., Kasper, D.L., Hauser, S.L., Longo, D.L., Jameson, J.L., Loscalzo, J.(eds.) *Harrison's Principles of Internal Medicine* 17th Ed. New York: The McGraw-Hill Companies, Inc. pp. 1995- 1999.
- Jordan, S.A., Cunningham, D.G. and Marles, R.J. 2010. Assessment of herbal medicinal products: challenges, and opportunities to increase the knowledge base for safety assessment. *Toxicology and Applied Pharmacology*, 243:198-216.
- Loomis, T.A. and Hayes, A.W. 1996. *Loomis's Essentials of Toxicology*, 4th ed. Academic Press, California.
- McKnight, D.C., Mills, R.G., Bray, J.J. and Crag, P.A. 1999. *Human Physiology*. 4th Ed. Churchill Livingstone, pp. 290-294.
- McNamara, B.P. 1976. Concepts in health evaluation of commercial and industrial chemicals. In: Mehlman, M.A., Shapiro, R.E., Blumental, H. (Eds.),

New Concepts in Safety Evaluation. Hemisphere, Washington, DC.

Mohammed, N., Yaro, A.H. and Nazifi, A.B. 2018. *Bombax costatum* Pellegr. and Vuillet Stem Bark Extract Prevents Paracetamol and Carbon Tetrachloride-Induced Liver Injury in Rats. *Tropical Journal of Natural Products Research*, 2(5):220-226.

Organisation for Economic Co-operation and Development. 2001. *OECD guidelines for testing of chemicals, Test No. 423, Acute toxic class method*. Available on the OECD public website for Test Guidelines at www.oecd.org/env/testguidelines.

Organisation for Economic Co-operation and Development. 2008. *Repeated Dose 28-day Oral Toxicity Study in Rodents*. Available on the OECD public website for Test Guidelines at www.oecd.org/env/testguidelines.

Rosidah, Y., Yam, M.F., Sadikun, A., Ahmad, M., Akowuah, G.A, Asmawi, M.Z. 2009. Toxicological evaluation of standardized methanol extract of *Gynura procumbens*. *Journal of Ethnopharmacology*, 123: 244-249.

Teo, S., Stirling, D., Thomas, S., Hoberman, A., Kiorpes, A. and Khetani, V. 2002. A 90- day oral gavage toxicity study of d-methylphenidate and d,l-methylphenidate in Sprague Dawley rats. *Toxicology*, 179: 183-196.

WHO 2013. *WHO Traditional Medicine Strategy 2014-2023*, Geneva: WHO Press.